

Partial Molar Pregnancy within the Fallopian Tube: A Rare and Challenging Entity

Dr. Amanpreet Kaur^{1*}, Dr. Aradhna², Dr. Monika Garg³, Dr. Manmeet Kaur⁴, Dr. Harleen Kaur⁵¹Junior Resident Department of Pathology, Government Medical College Patiala, Punjab, India²Assistant Professor, Department of Pathology, Government Medical College Patiala, Punjab, India³Associate Professor, Department of Pathology, Government Medical College Patiala, Punjab, India⁴Assistant Professor, Department of Pathology, Government Medical College Amritsar, Punjab, India⁵Junior resident Department of Pathology, Government Medical College Patiala, Punjab, IndiaDOI: [10.36347/sjmcr.2023.v11i06.041](https://doi.org/10.36347/sjmcr.2023.v11i06.041)

| Received: 05.05.2023 | Accepted: 07.06.2023 | Published: 14.06.2023

***Corresponding author:** Dr. Amanpreet Kaur

Junior Resident Department of Pathology, Government Medical College Patiala, Punjab, India

Abstract

Case Report

There have been a small number of ectopic molar pregnancies reported with estimates being around 1.5 in every 1,000,000 pregnancies. Ectopic pregnancy and molar pregnancy are not rare events with their incidence being 20 in every 1000 and 1 in every 500 to 1000 pregnancies respectively but their combination that is ectopic molar pregnancy is a rare entity so often not considered as a diagnostic possibility. Among ectopic pregnancies, fallopian tubes are the most common site (98% cases). Only 0.7 % of GTD (Gestational trophoblastic diseases) occur in Fallopian tube. Hydatidiform mole is the most common and a pre malignant form of GTD that occurs due to derranged fetal and placental development. Hydatidiform mole, a type of Gestational Trophoblastic disease, is an abnormal form of pregnancy/gestation which results from abnormal fertilization. Hydatidiform mole can either be a partial mole or complete mole. We report a case of a 30-year-old female with ruptured ectopic pregnancy, who initially presented with stable clinical status.

Keywords: Partial Mole, Ectopic pregnancy, Gestational trophoblastic disease.

Copyright © 2023 The Author(s): This is an open-access article distributed under the terms of the Creative Commons Attribution 4.0 International License (CC BY-NC 4.0) which permits unrestricted use, distribution, and reproduction in any medium for non-commercial use provided the original author and source are credited.

INTRODUCTION

Gestational trophoblastic disease is a rare condition. It's ectopic form is even rarer with estimate being around 1.5 in every 1,00,000 pregnancies [1]. Among ectopic pregnancies, the Fallopian tubes are the most common site (98%). Ectopic tubal molar pregnancy is a rare phenomenon. Only 0.7 % of gestational trophoblastic disease occur in Fallopian tube. Hydatidiform mole is the most common and a pre malignant form of gestational trophoblastic disease.

CASE PRESENTATION

A 30 years old female patient gravida 4, para 3, live 3, abortion 1 was admitted to gynae department of Rajindra hospital Patiala with complaint of abdominal pain since 2 days. She presented with history of 6 weeks of amenorrhea. On examination, she was found to be hemodynamically stable. Clinical examination revealed marked pallor with tenderness over right iliac fossa without guarding.

Per vaginal examination showed a normal sized uterus. Patient tested positive for pregnancy by urine pregnancy kit. Her past obstetrical history included a previous spontaneous early trimester abortion. Ultrasound examination of abdomen revealed ruptured right tubal ectopic pregnancy with hemoperitoneum. Laboratory findings included elevated serum beta human chorionic gonadotropin of 50,000 IU/L. The remainder of her laboratory investigations was unremarkable. Keeping in view of the above findings, decision for exploratory laparotomy was made. Subsequently, right sided salpingectomy was performed and sent for histopathological examination.

Gross examination

Gross examination of specimen showed brown coloured mass measuring 4 x 3 x 1.7 cm. Microscopic examination showed a ruptured Fallopian tube wall containing chorionic villi lined by syncytiotrophoblast and cytotrophoblast. Some of the villi are edematous and show cistern formation while others are small and hyalinized. Some hydropic villi showed focal trophoblastic proliferation. In some of the sections,

embryonic tissue was identified. The tubal wall also showed decidualized stromas along with inflammation and congested blood vessels. In view of these histological aspects, the diagnosis of partial molar

ruptured tubal pregnancy was made. b hcg before surgery was 50,000 IU/ml. Patient was followed up by serial serum b hcg levels. The tests showed a decreasing trend.

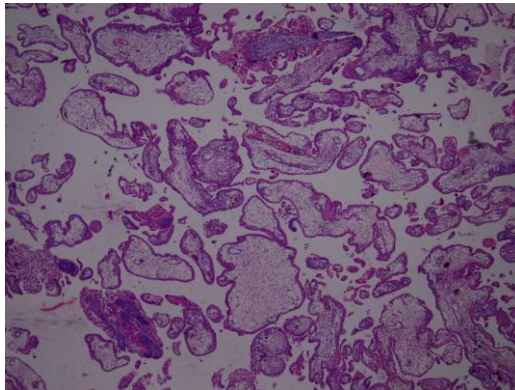


Figure 1: Irregular shaped edematous and swollen villi with scalloped borders, trophoblastic proliferation (H&E100x)

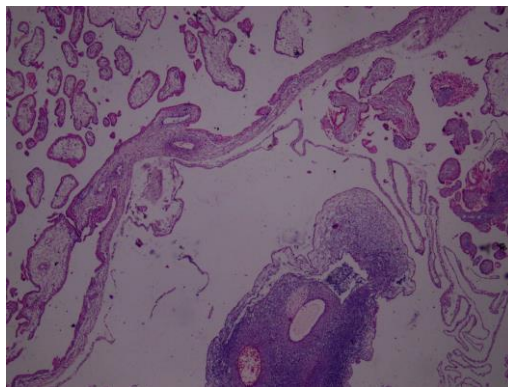


Figure 2: Image shows an admixture of normal appearing and edematous hydropic villi (H&E 400x)

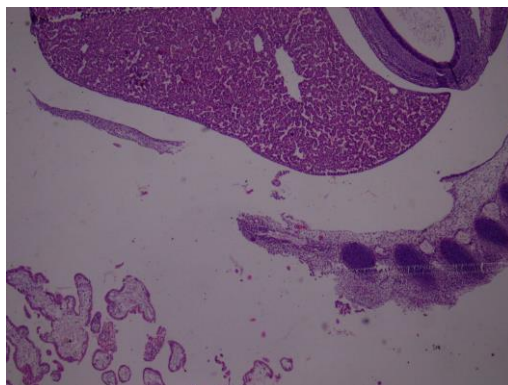


Figure 3: Image shows chorionic villi with fetal parts (H&E400x)

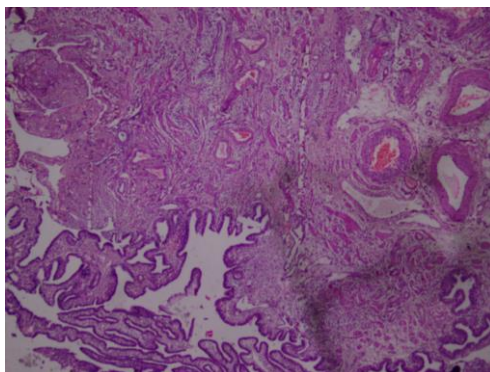


Figure 4: Image shows decidual stromal reaction in tubal wall with chorionic villus proliferation(H&E400x)

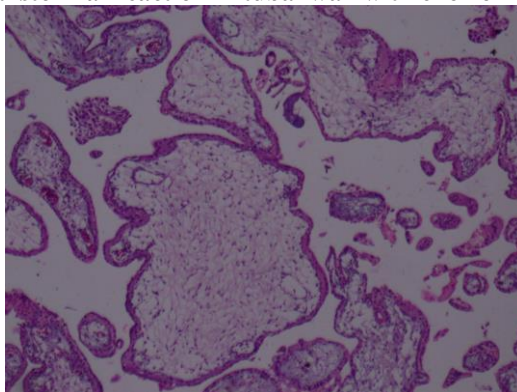


Figure 5: Irregular shaped edematous and swollen villi with scalloped borders, mild trophoblastic proliferation (H&E400x)

DISCUSSION

Hydatidiform mole, a type of Gestational Trophoblastic disease, is an abnormal form of pregnancy/gestation which results from abnormal fertilization. [2,3]. Molar pregnancy can be classified into partial or complete mole on the basis of morphology, pathology and genetic differences. A complete mole results when empty ovum is fertilised by single or occasionally 2 sperms, having diploid 46XX genotype [4]. Whereas, partial mole occurs when haploid ovum is fertilised by 2 sperms, resulting in triploid genome: 69 XXX, 69XYY, or 69 XXY [5].

The gold standard diagnostic tool for ectopic tubal pregnancy is histopathology [6]. Tubal molar pregnancies are managed surgically and are incidentally diagnosed by histopathology. A small number of tubal molar pregnancies may go unrecognised when such ectopic pregnancies are managed with methotrexate. According to some studies, ectopic molar pregnancies can be over diagnosed due to improper differentiation from non- molar hydropic pregnancies [7]. Molar pregnancies are characterized by hydropic chorionic villi and hyperplasia of trophoblasts. Molar pregnancies need to be differentiated from non molar pregnancies as molar pregnancies can lead to persistent trophoblastic disease [8].

Patients with ectopic molar pregnancy present with clinical features similar to that of tubal pregnancy like vaginal bleeding and abdominal pain. Thus it

becomes difficult and challenging to distinguish between the both conditions. The level of β -hCG does not contribute to make the distinction [9]. The histological differentiation between molar pregnancy and hydropic abortion is another challenge for the pathologists. Sebire *et al.* reported that ectopic molar pregnancies are often over diagnosed and only a small percentage of them are actually confirmed as ectopic molar pregnancies [10]. It thus becomes extremely important to do ploidy evaluation through DNA flow cytometry, in addition with clinical and histological features. It is worth noting that after histological techniques, molecular tests can distinguish complete from partial mole, but they fail to differentiate between complete mole from hydropic abortion [11].

It is crucial to make precise and early diagnosis of molar pregnancy as they can lead to persistent gestational trophoblastic disease which can further develop into malignancy, leading to adverse outcomes, if not treated. About 15% to 20% of complete molar pregnancies and 1% to 6% of partial molar pregnancies proceed to persistent gestational trophoblastic neoplasia [12]. Considering these risks of malignancy, following the diagnosis of molar pregnancy, patients are followed up with weekly quantitative β -hCG levels until 3 successive β -hCG levels are negative. They are also advised to avoid pregnancy for 6 months and are counselled on appropriate contraception options.

This case report focuses on the significance of histopathological examination of the products of

conception and tissue diagnosis following the surgical management of ectopic pregnancies. Even if it is a rare phenomenon, it is important to keep in mind the possibility of a hydatidiform mole in a patient with an ectopic pregnancy presentation. To conclude with, it becomes extremely crucial to continue proper follow-up of the patient with serial β -hCG assessment, appropriate contraception planning and appropriate counselling, to make sure that such cases of ectopic molar conceptions do not progress to choriocarcinomas.

REFERENCES

1. Bagshawe, K. D., Dent, J., & Webb, J. (1986). Hydatidiform mole in England and Wales 1973-83. *The Lancet*, 328(8508), 673-677.
2. Szulman, A. E., & Surti, U. (1978). The syndromes of hydatidiform mole: II. Morphologic evolution of the complete and partial mole. *American journal of obstetrics and gynecology*, 132(1), 20-27.
3. Szulman, A. E., & Surti, U. (1978). The syndromes of hydatidiform mole: II. Morphologic evolution of the complete and partial mole. *American journal of obstetrics and gynecology*, 132(1), 20-27.
4. Gillespie, A. M., Lidbury, E. A., Tidy, J. A., & Hancock, B. W. (2004). The clinical presentation, treatment, and outcome of patients diagnosed with possible ectopic molar gestation. *International Journal of Gynecologic Cancer*, 14(2).
5. Vassilakos, P., Riotton, G., & Kajii, T. (1977). Hydatidiform mole: two entities: a morphologic and cytogenetic study with some clinical considerations. *American journal of obstetrics and gynecology*, 127(2), 167-170.
6. Sherer, D. M., Stimphil, R., Hellmann, M., Gorelick, C., Serur, E., Zigalo, A., ... & Abulafia, O. (2006). Transvaginal sonographic findings of isolated intramural uterine choriocarcinoma mimicking an interstitial pregnancy. *Journal of ultrasound in medicine: official journal of the American Institute of Ultrasound in Medicine*, 25(6), 791-794.
7. Burton, J. L., Lidbury, E. A., Gillespie, A. M., Tidy, J. A., Smith, O., Lawry, J., ... & Wells, M. (2001). Over-diagnosis of hydatidiform mole in early tubal ectopic pregnancy. *Histopathology*, 38(5), 409-417.
8. Chauhan, S., Diamond, M. P., & Johns, D. A. (2004). A case of molar ectopic pregnancy. *Fertility and sterility*, 81(4), 1140-1141.
9. Sebire, N. J., Lindsay, I., Fisher, R. A., Savage, P., & Seckl, M. J. (2005). Overdiagnosis of complete and partial hydatidiform mole in tubal ectopic pregnancies. *International journal of gynecological pathology*, 24(3), 260-264.
10. Lai, C. Y., Chan, K. Y., Khoo, U. S., Ngan, H. Y., Xue, W. C., Chiu, P. M., ... & Cheung, A. N. (2004). Analysis of gestational trophoblastic disease by genotyping and chromosome in situ hybridization. *Modern pathology*, 17(1), 40-48.
11. John, R., & Lurain, M. (2010). Gestational trophoblastic disease I: epidemiology, pathology, clinical presentation and diagnosis of gestational trophoblastic disease, and management of hydatidiform mole. *Am J Obstet Gynecol*, 9.
12. DeCherney, A. H. (2019). *Current diagnosis & treatment: obstetrics & gynecology*. L. Nathan, N. Laufer, A. S. Roman, & M. H. Education (Eds.). McGraw-Hill Education.