

Unforeseen complication of Open mesh hernioplasty: A Case Report

Dr. Gaurav Raj Singh^{1*}, Dr Ajay Kumar Dayma², Dr. Rajkamal Jenaw³, Dr. Irfan Hussain Khan⁴

¹Resident, Department of General Surgery, NIMS Hospital, Jaipur, Rajasthan, India

²Assistant Professor, Department of General Surgery, NIMS Hospital, Jaipur, Rajasthan, India

³Professor, Director, Department of General Surgery, NIMS Hospital, Jaipur, Rajasthan, India

⁴Associate professor, Department of General Surgery, NIMS Hospital, Jaipur, Rajasthan, India

DOI: [10.36347/sjmcr.2023.v1i106.059](https://doi.org/10.36347/sjmcr.2023.v1i106.059)

| Received: 11.05.2023 | Accepted: 19.06.2023 | Published: 23.06.2023

*Corresponding author: Dr. Gaurav Raj Singh

Resident, Department of General Surgery, NIMS Hospital, Jaipur, Rajasthan, India

Abstract

Case Report

Open inguinal hernias are the most commonly performed surgical procedure in the general surgery, by this case report we intend to highlight the complication that we encountered while operating in the absence of previous surgical history and try to emphasize on the importance of detailed radiological investigations (USG and Colour Doppler) in cases with history of peripheral vascular diseases, as in our case patient was not aware of his previous surgical procedure and thus when we operated for bilateral inguinal hernia we met with unforeseen complication of torrential bleed on table. The post operative work up regarding the site of bleed revealed presence of a graft, history of which was not known to patient. Such complication could have been prevented by modifying approach, provided we had proper history and detailed radiology studies.

Keywords: Open mesh hernioplasty; inguinal hernia; femorofemoral bypass graft; Recurrent hernia.

Copyright © 2023 The Author(s): This is an open-access article distributed under the terms of the Creative Commons Attribution 4.0 International License (CC BY-NC 4.0) which permits unrestricted use, distribution, and reproduction in any medium for non-commercial use provided the original author and source are credited.

INTRODUCTION

Hernias are recognized as one of the oldest known disorders in humans. Surgical repair of inguinal hernias is a widely performed general surgery procedure, and newer techniques in hernia repair continue to evolve over time. The prevalence of abdominal wall hernias is estimated to be around 5% of the population, although it may be even higher. Inguinal hernias account for approximately 75% of all hernias, with two-thirds of them being indirect and the remainder being direct. Males have a significantly higher likelihood of developing a groin hernia compared to females. Inguinal hernia repair is considered the most common elective surgery performed in young males [1-3].

Femorofemoral crossover bypass is a surgical procedure used for arterial revascularization in cases of unilateral aortoiliac occlusive disease. It is primarily employed for patients experiencing intermittent claudication or critical limb ischemia, where anatomical constraints prevent the use of endovascular methods or when comorbid conditions rule out more invasive open surgical approaches. This procedure may also be employed as a complementary component of

endovascular repair for abdominal aortic aneurysms when one aortoiliac arterial system is occluded, ensuring proper exclusion of the aneurysm.

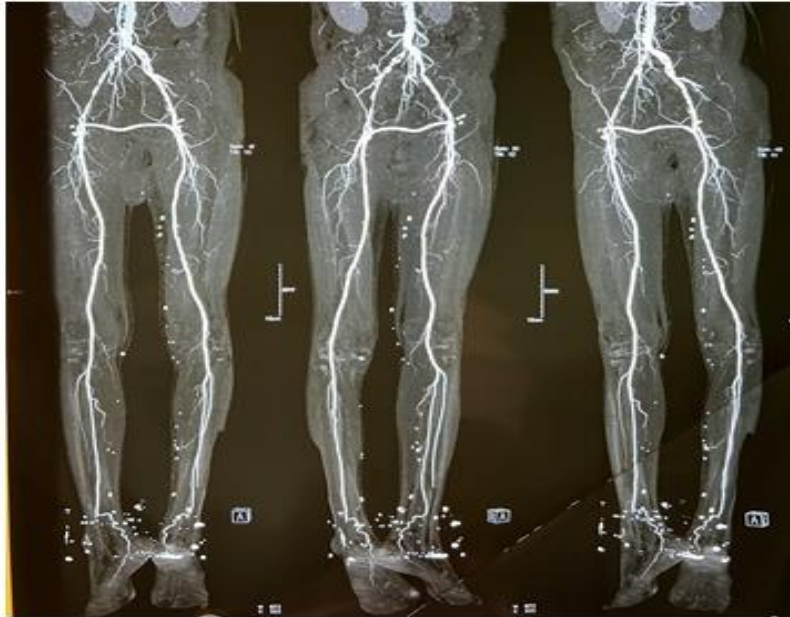While there is limited information available on inguinal hernia repair after femoral arterial bypass, and no recommended procedure has been established, I will now present an interesting case that highlights our experience.

CASE REPORT

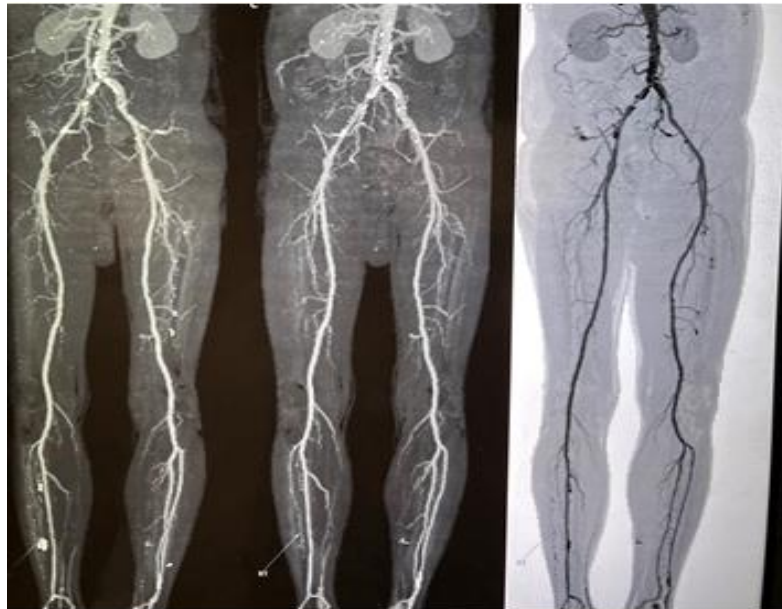
58 years male came to OPD with a complain of recurrent swelling in right inguinal region since 8 years which was operated 30 years back and left Inguinal swelling since last one month. Patient is a chronic smoker, alcoholic and hypertensive with CAD and DVT.

There is history of PTCA Stenting and CABG in 2018 and previously operated left sided inguinal hernia.

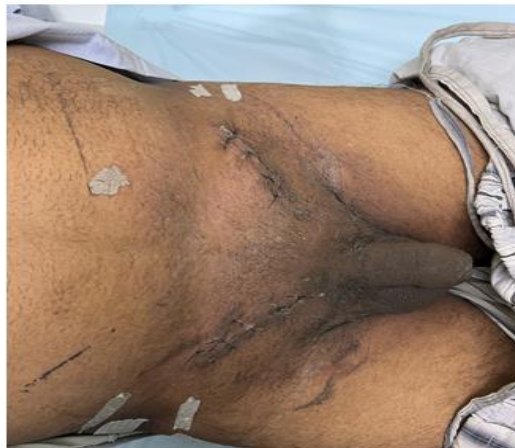Patient presented to us with complaint of Bilateral inguinal swelling.



Femorofemoral Graft



Normal CT Angiograph



Postoperative Picture

Intraoperative Findings

Mesh hernioplasty was planned with the standard incision site.

During the surgery we found a vessel in the subcutaneous plane with a wide lumen which got injured following torrential bleed on table. Bleeder was identified, ligated. Mesh hernioplasty was completed after achieving haemostasis.

Similar findings were noted on the right side.

Postoperative Period

Procedure gave clinical suspicion of some graft surgery which was missed during postoperative work up revealed:

1. Decreased pulse volume of the lower limb peripheral vessels
2. A CT angiography of lower limb revealed, atherosclerotic block of right common iliac artery and right anterior tibial artery.

Previous documentation revealed that he underwent PTCA with stent to LAD/RCA (26-03-18) and off Pump CABG X3(RCA, PDA and endarterectomy) and Left to Right Femoro -Femoral cross over graft with Saphenous vein and left femoral to popliteal saphenous vein graft and right femoral to popliteal graft with Vein graft in 2018.

Patient was unaware regarding same.

Patient was asymptomatic in our 4 months of follow up on oral anticoagulants. There were no complains of the ischemia in the lower limbs and all peripheral pulses were intact.

DISCUSSION

Inguinal hernias in general surgery are very common surgical procedures which are clinically diagnosed and supported by radiological investigations such as USG inguinoscrotal region, and have various surgical modalities of treatment.

Above described case had various comorbidities like hypertension, COPD, Coronary artery disease and history of Coronary artery bypass grafting along with Left to Right Femoro -Femoral cross over graft of which no history was given and no documentation were available, in this background PVD was missed.

And there had been very few cases reported in literature as of now. Recent most articles mentioned of only 3 such documented cases till 2019 [4-6].

In such cases with following comorbidities, specially history of coronary artery diseases, a detailed work up for other vascular diseases should be done and special emphasis should be given on detailed Ultrasonography of the inguinoscrotal region along with colour Doppler study of the vasculature to rule out such instances like in our case history of surgical interventions was not reliable

Such pre operative work up could help us in modifying our approach of surgery and switch to laparoscopic approach like TAPP and TEPP.

REFERENCES

1. "Abdominal Hernias: Practice Essentials, Background, Anatomy". 2021-11-04.
2. Chawla, S. (2013). Recent concepts in inguinal hernia repair. *Medical Journal of Dr. DY Patil University*, 6(4), 381-382.
3. Yuksel, A., Cayir, M. C., Kumtepe, G., Velioglu, Y., Atli, F. H., Muduroglu, A., & Gurbuz, O. (2018). An overview and update of femorofemoral crossover bypass surgery as an extra-anatomic bypass procedure. *The Thoracic and Cardiovascular Surgeon*, 66(03), 266-272. doi:10.1055/s-0037-1613715. Epub 2017 Dec 31. PMID: 29290082.
4. Onda, S., Suwa, K., Neki, K., & Yanaga, K. (2019). Open mesh plug repair for inguinal hernia after femoro-femoral arterial bypass: Two retrospective case series. *International Journal of Surgery Case Reports*, 65, 180-183. doi:10.1016/j.ijscr.2019.08.017. Epub 2019 Aug 20. PMID: 31722279; PMCID: PMC6854071.
5. Kawamura, Y. J., Futakawa, N., Oshiro, H., Yasuhara, H., Shigematsu, H., & Muto, T. (1999). Bilateral inguinal hernia repaired by laparoscopic technique: a rare complication of femorofemoral bypass. *Surgical endoscopy*, 13, 1157-1159.
6. Tsukada, T., Saito, H., Amaya, K., Terada, I., Kaji, M., & Shimizu, K. (2015). Hybrid laparoscopic and anterior approach for postsurgical inguinal hernia after iliofemoral arterial bypass. *International Surgery*, 100(3), 431-435. doi:10.9738/INTSURG-D-14-00226.1. PMID: 25785323; PMCID: PMC4370531.