

## A Giant Arachnoid Cyst: Is it an Innocent Bystander?

K. Outaghyame<sup>1\*</sup>, H. Chenter<sup>1</sup>, O. Kanali<sup>1</sup>, C. Ahmanna<sup>1</sup>, I. Zouita<sup>1</sup>, D. Basraoui<sup>1</sup>, H. Jalal<sup>1</sup>

<sup>1</sup>Radiology Department, Mother and Child Hospital, Mohamed VI University Hospital, Marrakech, Morocco

DOI: <https://doi.org/10.36347/sjmcr.2024.v12i10.014>

| Received: 21.08.2024 | Accepted: 30.09.2024 | Published: 02.10.2024

\*Corresponding author: K. Outaghyame

Radiology Department, Mother and Child Hospital, Mohamed VI University Hospital, Marrakech, Morocco

### Abstract

### Case Report

Arachnoid cysts can differ significantly in size and location, with larger cysts often leading to symptoms that necessitate surgical intervention. Evaluating the potential benefits of surgery for patients with arachnoid cysts and neurological symptoms is crucial.

**Keywords:** Arachnoid Cyst, Computed Tomography, Galassi Classification.

Copyright © 2024 The Author(s): This is an open-access article distributed under the terms of the Creative Commons Attribution 4.0 International License (CC BY-NC 4.0) which permits unrestricted use, distribution, and reproduction in any medium for non-commercial use provided the original author and source are credited.

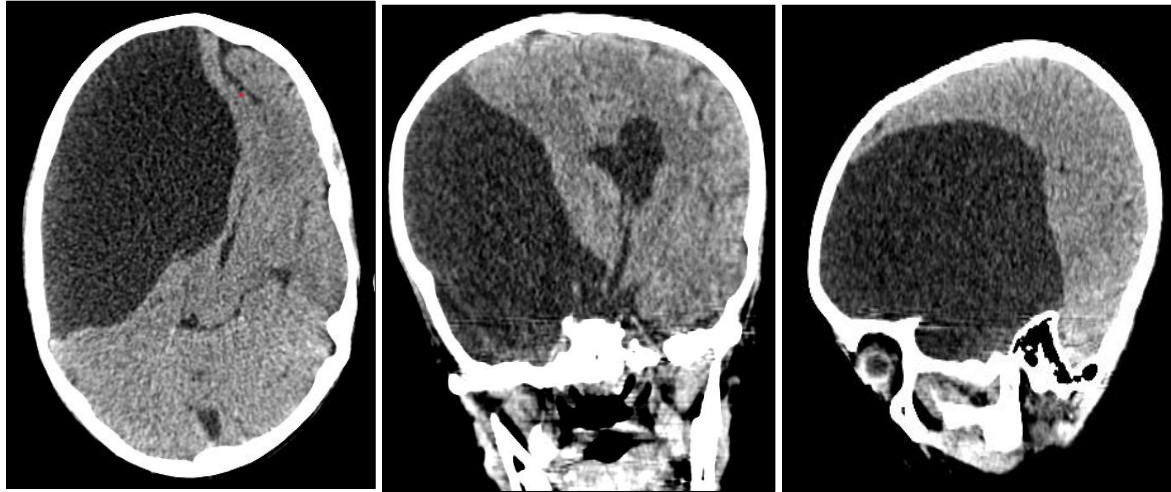
## INTRODUCTION

Arachnoid cysts (ACs) are frequently encountered benign congenital lesions found within the cranial cavity, often identified incidentally [1]. The exact mechanisms behind the formation of these cysts remain uncertain, but they are believed to result from the separation of the arachnoid membrane during embryonic development. One rare location for supratentorial ACs is the interhemispheric fissure. Common clinical manifestations of these cysts include headaches, seizures, and neurological deficits. Currently, there is no universally accepted strategy for the surgical management of ACs. Here, we present a case involving a giant AC that exhibited signs of brain compression.

## OBSERVATION

A 14-year-old boy, who was being treated for left humeral osteosarcoma with chemotherapy, arrived at the emergency department experiencing afebrile seizures. His neurological examination was largely

unremarkable, except for a notable midline-splitting sensory loss on the right side across all modalities, indicative of functional sensory loss. A brain CT scan (Figure 1) revealed a large, poorly defined, right fronto-temporal extra-axial cystic lesion with well-defined borders, extending into the left temporal fossa. The density of the lesion was similar to that of cerebrospinal fluid, and it exerted a mass effect on the ipsilateral lateral ventricle and midline structures, causing a significant right-to-left shift of 25 mm. There were also signs of subfalcial herniation, with the lesion measuring 11 x 11.7 x 16.5 cm (transverse x craniocaudal x anteroposterior). Additionally, a mild hypertrophy of the right lesser wing of the sphenoid bone was noted, along with slight dilation of the occipital horn of the left lateral ventricle, though without evidence of transependymal resorption. Electroencephalogram results were normal. A neurosurgical evaluation suggested that the cyst was likely an incidental finding not related to his seizures, and nonsurgical management was recommended 4o mini.



**Figure 1: Brain scan, parenchymal window in axial (a), coronal (b) and sagittal (c) sections with MIP acquisition:**

Large right fronto-temporal extra-axial cystic formation, extending into the left temporal fossa with density similar to cerebrospinal fluid, exerting a mass effect on the ipsilateral lateral ventricle and midline structures, with signs of subfalcine herniation.

## DISCUSSION

The estimated prevalence of arachnoid cysts (ACs) in adults is approximately 1.4%, with a slightly higher occurrence in men than in women. Most cases of ACs remain asymptomatic. However, their natural course can involve spontaneous or traumatic rupture, enlargement leading to brain compression, and hydrocephalus, which may exacerbate focal deficits. While ACs can present with symptoms such as parkinsonism, cognitive impairment, anxiety, and depression, the case described here did not exhibit any of these manifestations. Notably, even large and giant ACs can be asymptomatic. Arachnoid cysts are fluid-filled sacs within the cranial cavity, lined by the arachnoid membrane, and are often discovered incidentally in up to 1.4% of individuals undergoing brain MRI. Only about 5% of patients with arachnoid cysts experience neurological symptoms related to the cyst. The Galassi classification categorizes arachnoid cysts in the middle cranial fossa into three types: Type I cysts are typically small and asymptomatic, located in the anterior middle cranial fossa; Type II cysts extend superiorly along the Sylvian fissure and may displace the temporal lobe; and Type III cysts are exceptionally large, occupying the entire middle cranial fossa and displacing adjacent lobes. The cyst in this particular case is classified as type III. Four primary theories explain cyst enlargement: (1) cerebrospinal fluid (CSF) secretion from the inner surface of the cyst; (2) an osmotic gradient between the contents of the cyst and the surrounding CSF; (3) a slit-valve mechanism connecting the cyst to the subarachnoid space; and (4) pulsatile movements of intracystic fluid from venous or arterial sources. During the intraoperative examination, no valve-like structures were identified. The presented case exhibited

nonspecific symptoms, leading to controversy regarding treatment. Although surgery for symptomatic arachnoid cysts can be beneficial, some authors argue that seizures and headaches often persist post-treatment. Wang *et al.*, suggested that patients with nonspecific symptoms might benefit from surgical decompression of the cyst, while Rabiei *et al.*, reported no significant changes in surgically treated patients despite self-reported improvements. Some experts recommend medical management for patients with headaches or seizures. In this case, symptoms were suspected to be related to the cyst despite the absence of elevated intracranial pressure (ICP). Surgical indications included signs of brain compression, epileptiform activity, and isolation of the cyst during CT cisternography. Surgical approaches for ACs include microsurgical resection of the cyst wall (with or without connections to the ventricles or basal cisterns), endoscopic fenestration, and cyst-peritoneal shunting. Several studies indicate that the clinical outcome is independent of the surgical technique employed. In this instance, we opted to avoid cyst shunting given the patient's young age to prevent shunt dependency. Treatment strategies depend on whether patients are symptomatic. Conservative management typically involves serial imaging, while surgical options may include craniotomy, cystoperitoneal shunt placement, endoscopic fenestration, or stereotactic aspiration.

## CONCLUSION

Arachnoid cysts (ACs) are uncommon causes of headaches and seizures. Surgical intervention may be considered the preferred treatment option, even in cases with minimal clinical presentation. Indications for surgery include increased intracranial pressure (ICP), evidence of cyst enlargement, hydrocephalus, signs of brain compression, and the presence of epileptiform activity.

## BIBLIOGRAPHY

- Al-Holou, W. N., Terman, S., Kilburg, C., Garton, H. J., Muraszko, K. M., & Maher, C. O. (2013). Prevalence and natural history of arachnoid cysts in adults. *Journal of neurosurgery*, 118(2), 222-231.
- de Longpre, J. (2017). Large arachnoid cyst. *N Engl J Med*, 376, 2265.
- Dunn, C. B., Price, C. C., Schwab, N. A., & Shukla, A. A. W. (2012). A case of an arachnoid cyst masquerading as corticobasal degeneration. *The Clinical Neuropsychologist*, 26(8), 1342-1357.
- Galassi, E., Tognetti, F., Gaist, G., Fagioli, L., Frank, F., & Frank, G. (1982). CT scan and metrizamide CT cisternography in arachnoid cysts of the middle cranial fossa: classification and pathophysiological aspects. *Surgical neurology*, 17(5), 363-369.
- Gjerde, P. B., Litleskare, S., Lura, N. G., Tangen, T., Helland, C. A., & Wester, K. (2019). Anxiety and depression in patients with intracranial arachnoid cysts—a prospective study. *World Neurosurgery*, 132, e645-e653.
- Hubele, F., Imperiale, A., Kremer, S., & Namer, I. J. (2012). Asymptomatic giant arachnoid cyst. *Clinical nuclear medicine*, 37(10), 982-983.
- Marques, I. B., & Barbosa, J. V. (2014). Arachnoid cyst spontaneous rupture. *Acta Med Port*, 27, 137-41.
- Mormont, E., Dorban, S., & Gustin, T. (2017). Parkinsonism and cognitive impairment due to a giant frontal arachnoid cyst and improving after shunting. *Acta Neurologica Belgica*, 117, 347-349.
- Rabiei, K., Hellstrom, P., Hogfeldt-Johansson, M., & Tisell, M. (2018). Does subjective improvement in adults with intracranial arachnoid cysts justify surgical treatment? *J Neurosurg*, 128, 250–7.
- Wang, Y., Wang, F., Yu, M., & Wang, W. (2015). Clinical and radiological outcomes of surgical treatment for symptomatic arachnoid cysts in adults. *Journal of Clinical Neuroscience*, 22(9), 1456-1461.
- Yamasaki, F., Kodama, Y., Hotta, T., Taniguchi, E., Eguchi, K., Yoshioka, H., ... & Kurisu, K. (2003). Interhemispheric arachnoid cyst in the elderly: case report and review of the literature. *Surgical neurology*, 59(1), 68-74.