

## Intraosseous Lipoma of the Calcaneus with Cystic Degeneration: A Case Report

C. JEDDI<sup>1</sup>\*, H. KHAOUALNI<sup>1</sup>, B. Boutakioute<sup>1</sup>, M. Ouali Idrissi<sup>1</sup>, N. Cherif Idrissi Gannouni<sup>1</sup>

<sup>1</sup>Department of Radiology, Hospital AR-RAZI, University Hospital Center Mohammed VI, Marrakech, Morocco

DOI: <https://doi.org/10.36347/sjmcr.2024.v12i10.031>

| Received: 24.08.2024 | Accepted: 04.10.2024 | Published: 10.10.2024

\*Corresponding author: C. JEDDI

Department of Radiology, Hospital AR-RAZI, University Hospital Center Mohammed VI, Marrakech, Morocco

### Abstract

### Case Report

Intraosseous lipoma is a rare benign lesion of bone. We present a case of an intraosseous lipoma of the calcaneus detected on X rays that suggested a bone cyst. Diagnosis was done with a computed tomography scan and magnetic resonance imaging.

**Keywords:** Intraosseous Lipoma, Calcaneus, CT, MRI.

Copyright © 2024 The Author(s): This is an open-access article distributed under the terms of the Creative Commons Attribution 4.0 International License (CC BY-NC 4.0) which permits unrestricted use, distribution, and reproduction in any medium for non-commercial use provided the original author and source are credited.

## INTRODUCTION

An intraosseous lipoma is among the rarest primary bone tumors, accounting for 0.1% of all skeletal tumors. In the lower limb, its occurrence in the calcaneus is observed in 15% of cases [1].

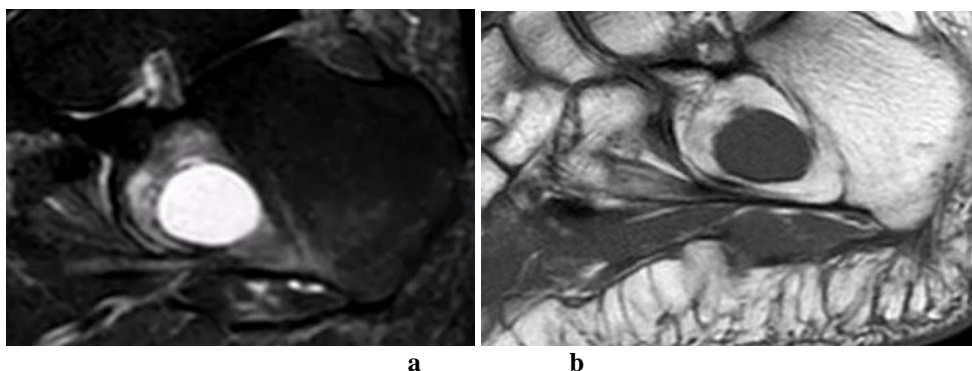
Its etiology remains unclear, with opinions divided between a benign tumor origin and post-traumatic factors. It slightly predominates in females and typically affects individuals in their fourth or fifth decade of life [2].

We report the case of an intraosseous lipoma of the calcaneus in a 30-year-old man.

## CASE

A 30-year-old patient complains of intermittent chronic bone pain in the heel that has progressed over the past two years, worsening with sports activity. An ankle X-ray suggested a diagnosis of a simple bone cyst. A CT scan of the ankle was performed and revealed a an intramedullary osteolytic lesion in the calcaneus shaft with a well-defined sclerotic margin with density less than subcutaneous tissues, a central homogeneous isodense component was noted.

MRI showed a calcaneal lesion whose center is hypointense on T1WI and hyperintense on STIR, denoting fluid. Its periphery is isointense to bone marrow on T1WI and suppressed on STIR, indicating fat (figure 1 and 2).



**Figure 1 and 2: MRI sagittal plan**

- (a) T1WI: Calcaneal lesion with hypointense center, and an isointense periphery to bone marrow.  
(b) STIR: Calcaneal lesion with hyperintense center, and a suppressed periphery.

## DISCUSSION

Diagnosis with X-ray alone is difficult for an intraosseous lipoma. Radiographic characteristics resemble those of benign tumors. The lesion appears osteolytic and mildly expansile, with a well-defined sclerotic border. Most tumors exhibit dystrophic calcification in areas of fat necrosis commonly referred to as Cockade sign that may be a useful clue to the diagnosis [3, 4].

With the introduction of CT and MRI, we can now determine the nature of the lesion without requiring a biopsy or surgical excision. However, the radiologic characteristics of intraosseous lipomas depends on the histological composition of the lesion. These lipomas can have different proportions of fat, bone, fibrous tissue, and cystic degeneration, leading to a variety of radiographic appearances [5].

Based on the histopathological features, intraosseous lipomas are divided into three types as described by Milgram *et al.*, [6]:

- Stage 1 includes solid tumors of viable lipocytes.
- Stage 2 includes transitional cases with partial fat necrosis and focal calcification but with areas of viable lipocytes.
- Stage 3 includes advanced cases where fat cells have died with varying degree of changes like calcification, cyst formation, and reactive new bone formation.

CT scan findings correlate with the histologic stages of the lesion. Stage 1 lesions appear lucent, indicating viable, non-necrotic fat with resorption of bony trabeculae. Stage 2 lesions show lucent regions of viable fat alongside radio dense areas of fat necrosis and dystrophic calcification and may also be expansile. Stage 3 lesions are heterogeneous, more radio dense due to calcification and significant fat necrosis, featuring a thick sclerotic border, and may exhibit cystic changes [4].

On MRI, the lesion appears geographic and rounded, without cortical interruption, displaying a peripheral rim of high signal intensity on T1-weighted images. Fat suppression is typically homogeneous on fat-suppressed T2-weighted or inversion recovery-weighted

images. In Milgram stage 2 or 3 lesions, ossifications and calcifications can create a distinctive radiographic appearance [6, 7]. Stage 2 lesions exhibit fat and a circumferential rim of decreased signal on T1- and T2-weighted images, along with low-signal-intensity areas in the central portion indicative of calcifications. Stage 3 lesions present with a thin peripheral rim of fat, central calcification, and a thick surrounding rim of sclerosis with low signal intensity on both T1- and T2-weighted sequences. Areas of fat necrosis show variable signal on T1-weighted images and increased signal on T2-weighted images [7].

## CONCLUSION

Intraosseous lipoma of the calcaneus is a very rare location for the condition. The differential diagnosis with a cystic lesion justifies the use of CT and MRI.

## REFERENCES

1. Alami, B., & Tizniti, S. (2014). Lipome intraosseux du calcaneum chez une jeune femme. *The Pan African Medical Journal*, 18, 316. doi: 10.11604/pamj.2014.18.316.5035
2. Milgram, J. W. (1988). Intraosseous lipomas: a clinicopathologic study of 66 cases. *Clin Orthop*, 231, 277-302.
3. Khal, A. A., Mihu, R. C., Schiau, C., Fetica, B., Tomoia, G., & Luna, M. V. (2021). Symptomatic intraosseous lipoma of the calcaneum. *Diagnostics (Basel)*, 11(12), 2243.
4. Milgram, J. W. (1988). Intraosseous lipomas: radiologic and pathologic manifestations. *Radiology*, 167, 155-60.
5. Eyzaguirre, E., Liqiang, W., Karla, G. M., Rajendra, K., Alberto, A., & Gatalica, Z. (2007). Intraosseous lipoma. A clinical, radiologic, and pathologic study of 5 cases. *Annals of diagnostic pathology*, 11(5), 320-325.
6. Milgram, J. W. (1988). Intraosseous lipomas. a clinicopathologic study of 66 cases. *Clin Orthop Relat Res.*, 231, 277-302.
7. Propeck, T., Bullard, M. A., Lin, J., Doi, K., & Martel, W. (2000). Radiologic-pathologic correlation of Intraosseous lipomas. *Am J Roentgenol*, 175(3), 673-678.