

## Mandibular Fibrosarcoma, A Case Report

Zidani Ayoub<sup>1\*</sup>, Khalil Aalloula<sup>1</sup>, Bouktib. Y<sup>1</sup>, Ouali Idrissi. M<sup>1</sup>, Idrissi. N<sup>1</sup>

<sup>1</sup>Radiology Department, Arrazi Hospital, Marrakech, Morocco

DOI: <https://doi.org/10.36347/sjmcr.2024.v12i10.052> | Received: 16.09.2024 | Accepted: 20.10.2024 | Published: 26.10.2024

\*Corresponding author: Zidani Ayoub

Radiology Department, Arrazi Hospital, Marrakech, Morocco

### Abstract

### Case Report

Ameloblastic fibrosarcoma (AFS) is a rare malignant odontogenic tumour classified by the WHO (1992) as an odontogenic sarcoma and defined as “a neoplasm with a similar structure to ameloblastic fibroma (AF) but in which the ectomesenchymal component shows the features of a sarcoma.” The first report of AFS was published by Heath in 1887. AFS and related lesions are less frequently diagnosed than odontogenic carcinomas. Approximately two-thirds of AFSs seem to arise de novo, but others have developed in recurrent AF, in which the ectomesenchymal cells retain their embryonic appearance and develop malignant characteristics. We report a rare case of an aggressive odontogenic neoplasm, the incisional biopsy of which showed the features of AF, while the excisional biopsy revealed the features of malignancy, suggestive of AFS. The purpose of this report is to discuss the diagnostic difficulties, whether AFS is truly an extremely rare tumour as reported earlier and, lastly, should the treatment protocols of AFs be revised, as 44% of AFSs arise from recurrent AFs.

**Keywords:** Odontogenic fibrosarcoma, Odontogenic sarcoma, Ameloblastic fibrosarcoma, Ameloblastic fibroma.

Copyright © 2024 The Author(s): This is an open-access article distributed under the terms of the Creative Commons Attribution 4.0 International License (CC BY-NC 4.0) which permits unrestricted use, distribution, and reproduction in any medium for non-commercial use provided the original author and source are credited.

## INTRODUCTION

Ameloblastic fibrosarcoma (AFS) is malignant odontogenic neoplasm. Defined by the World Health Organization (WHO): A neoplasm structurally similar to ameloblastic fibroma (AF), but with its ectomesenchymal component showing sarcomatous appearance [1, 2].

It can arise:

- From a pre-existing AF
- Or as a de novo lesion [3].

It mainly affects males during the third decade of life. The mandible is the most common region and its main clinical features include swelling and pain [1].

## OBJECTIVE

- Illustrate a case of ameloblastic mandibular fibrosarcoma,
- Collected in the Department of Radiology, Arrazi Hospital, Marrakech.

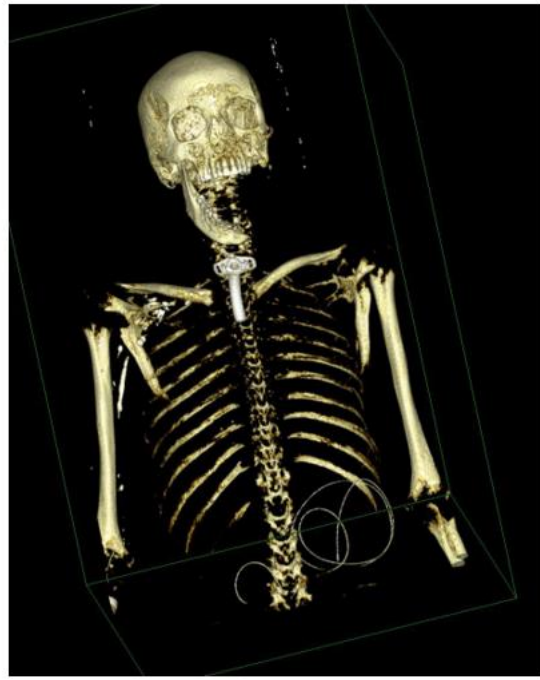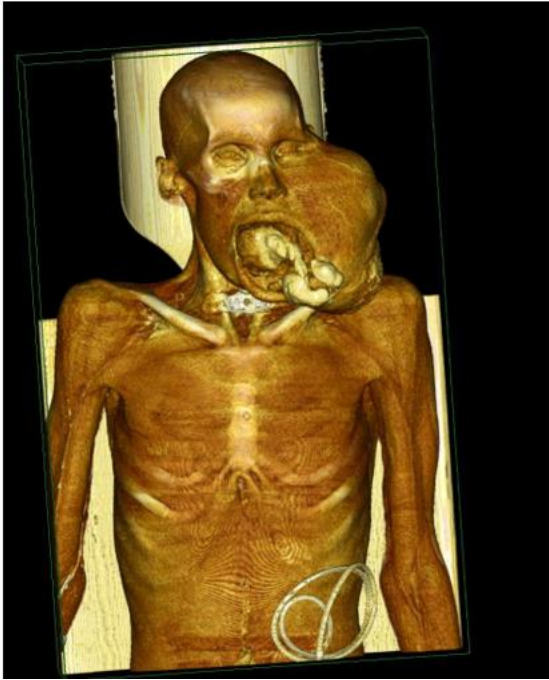## CASE REPORT

A 31-year-old male consulted for swelling of the left cheek. No history of any systemic illness or trauma to the present area was present. The current symptom was of a progressive onset and a rapid evolution. The examination of the swelling revealed a firm consistency that was free of pain on palpation. Radiographs and computed tomography (CT) were requested. An incisional biopsy suggested the diagnosis of “ameloblastoma”.

- Based on the clinical conditions, a medial mandibulectomy with safety margins was performed.
- A final diagnosis of AFS was performed.

The patient was lost to follow-up. 1 year after surgery, the evolution was marked by the recurrence of the tumor in the previous location with distant metastases in the lungs and the liver.

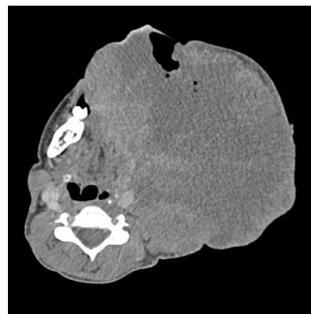
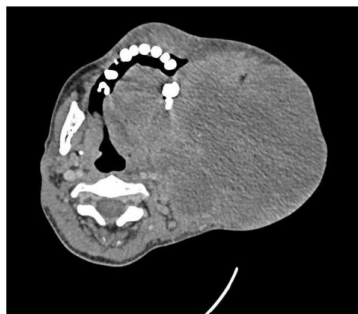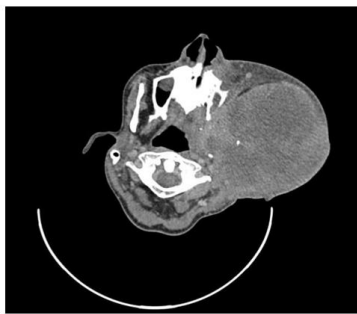
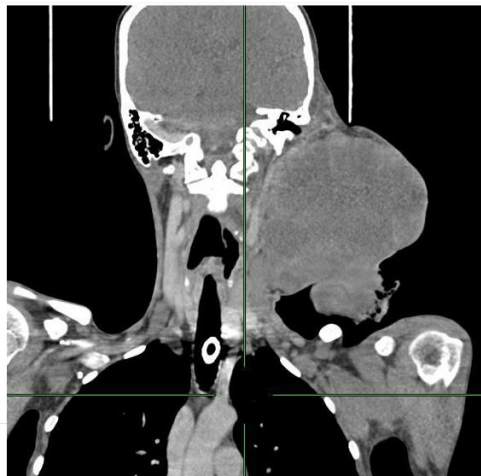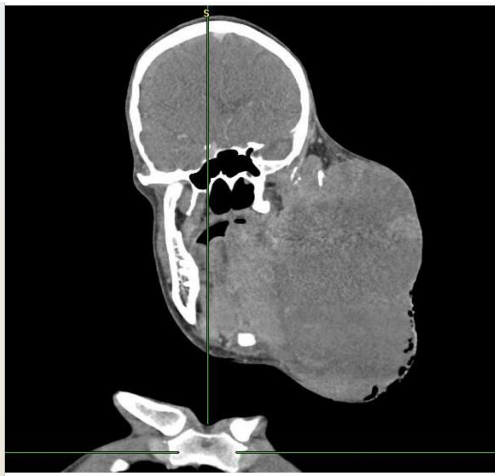CT scan with 3D reconstructions: A large mass of tissue with an aggressive character with the epicenter localized in the left mandible.



The mass is:

- Spontaneously isodense
- Highly and heterogeneously enhanced by contrast with large areas of central necrosis,

- Non-individualisation of the left hemi mandible
- Calcific densities.



- The mass infiltrate the bed of the mouth and the tongue,
- pushes back the oro-pharyngeal die with reduction of its caliber

## DISCUSSION

AFS is considered to be the malignant counterpart of AF, consisting of benign odontogenic epithelium with malignant mesenchyme [4]. The history of the present case suggests that the tumor was probably a de novo lesion, since the patient had no history of previous surgery or diseases involving the mandibular region. Radiological imaging of fibrosarcomas reveals radiolucent lesions with a geographical, moth-eaten or permeative pattern of bone destruction [5-7]. The absence of tumoural calcification or ossification can be of importance in differentiating fibrosarcomas from other malignancies:

- Chondrosarcomas
- Osteosarcomas.

Presently, surgical excision with a margin of normal tissue is the treatment of choice. Other treatment modalities such as adjuvant chemotherapy and radiotherapy were found to be ineffective [8]. Recurrence is common in AFS, with 37% of the reported cases having at least one episode [1].

## CONCLUSION

The differential diagnosis includes:

- Other odontogenic sarcomas,
- Ameloblastic carcinosarcoma
- Spindle cell carcinoma.

Treatment of choice is wide surgical excision, with long-term follow-up. AFS is a locally aggressive malignant tumor, with regional and distant metastases being uncommon.

## REFERENCES

1. Bregni, R. C., Taylor, A. M., & García, A. M. (2001). Ameloblastic fibrosarcoma of the mandible: report of two cases and review of the literature. *Journal of Oral Pathology & Medicine: Case report*, 30(5), 316-320.
2. de Paula, A. M. B., da Costa Neto, J. Q., da Silva Gusmão, E., Santos, F. B. G., & Gomez, R. S. (2003). Immunolocalization of the p53 protein in a case of ameloblastic fibrosarcoma. *Journal of oral and maxillofacial surgery*, 61(2), 256-258.
3. Taylor, A. M., García, A. M., & Godoy, L. M. R. (2003). Tumores odontogénicos malignos. Estudio retrospectivo y colaborativo de 7 casos. *Medicina Oral*, 8, 110-121.
4. Williams, M. D., Hanna, E. Y., & El-Naggar, A. K. (2007). Anaplastic ameloblastic fibrosarcoma arising from recurrent ameloblastic fibroma: restricted molecular abnormalities of certain genes to the malignant transformation. *Oral Surgery, Oral Medicine, Oral Pathology, Oral Radiology, and Endodontology*, 104(1), 72-75.
5. Theodorou, D. J., Theodorou, S. J., & Sartoris, D. J. (2003). Primary non-odontogenic tumors of the jawbones: an overview of essential radiographic findings. *Clinical imaging*, 27(1), 59-70. doi: 10.1016/S0899-7071(02)00518-1.
6. Kahn, L. B., & Vigorita V. (2002). Fibrosarcoma of bone. In: Fletcher, C. D. M., Unni, K. K., Mertens, F., editor. *World Health Organization Classification of Tumours Pathology and Genetics of Tumours of Soft Tissue and Bone*. IARC Press, Lyon, France; pp. 289–290.
7. Rao, B. N., Santana, V. M., Fleming, I. D., Pratt, C. B., Shapiro, D., Fontanesi, J., ... & Austin, B. A. (1989). Management and prognosis of head and neck sarcomas. *The American journal of surgery*, 158(4), 373-377. doi: 10.1016/0002-9610(89)90136-0.
8. Reichart, P. A., & Philipsen, H. P., editors. (2004). *Odontogenic tumours and allied lesions*. 1 st ed. London: Quintessence Publishing; 2004.