

## Stercoral Peritonitis Revealing Abdominal Tuberculosis in an Infant: A Case Report

S. Kirami<sup>1\*</sup>, A. Hebbezni<sup>1</sup>, H. Dahman<sup>1</sup>, H. Ch. Ahmanna<sup>1</sup>, B. Zouita<sup>1</sup>, D. Basraoui<sup>1</sup>, H. Jalal<sup>1</sup><sup>1</sup>Radiology Mother Child Department, CHU Mohammed VI, University Cadi Ayad, Marrakech, MoroccoDOI: [10.36347/sjmcr.2024.v12i05.027](https://doi.org/10.36347/sjmcr.2024.v12i05.027)

| Received: 30.03.2024 | Accepted: 06.05.2024 | Published: 15.05.2024

\*Corresponding author: S. Kirami

Radiology Mother Child Department, CHU Mohammed VI, University Cadi Ayad, Marrakech, Morocco

### Abstract

### Case Report

While relatively uncommon in children, abdominal tuberculosis should be considered in the presence of an insidious symptomatology marked by prolonged fever and gastrointestinal disturbances. Ultrasound or CT imaging can assist in guiding diagnosis and prelevements. histopathological confirmation is usually required to establish a definitive diagnosis.

**Keywords:** Abdominal tuberculosis, peritonitis, imaging, complications.

Copyright © 2024 The Author(s): This is an open-access article distributed under the terms of the Creative Commons Attribution 4.0 International License (CC BY-NC 4.0) which permits unrestricted use, distribution, and reproduction in any medium for non-commercial use provided the original author and source are credited.

## INTRODUCTION

Abdominal tuberculosis is an extrapulmonary form of Mycobacterium tuberculosis infection. There is an increasing incidence of abdominal tuberculosis (TB) in developed countries, with the peritoneum and intestinum being the most common sites of involvement. The clinical manifestations are often non specific and can mimic other pathologies, with inflammatory bowel disease or malignant neoplasms as the main differential diagnoses. Diagnosis is, therefore, difficult, unsuspected, and often delayed, especially in pediatric patients without an obvious history of exposure to the pathogen, leading to increased morbidity and mortality.

In this report, we present a case of abdominal tuberculosis diagnosed in a 9-year-old boy with a severe manifestation of stercoral peritonitis. Additionally, we conducted a brief literature review to recapitulate the primary imaging characteristics associated with this condition.

## CASE REPORT

A 9-year-old boy, presented with a 6-month clinical history of diarrhea, weight loss, and occasional fever. The physical examination revealed a febrile patient with cutaneous-mucous pallor. Abdominal palpation identified a tender periumbilical mass, along with diffuse abdominal tenderness. The rest of the examination showed no particular abnormalities. In the laboratory findings, there was a significant positive

infectious profile with elevated white blood cell count (WBC) and C-reactive protein (CRP).

Abdominal ultrasound was performed, revealing a large, echogenic, and septated peritoneal effusion, associated with deep adenopathies.

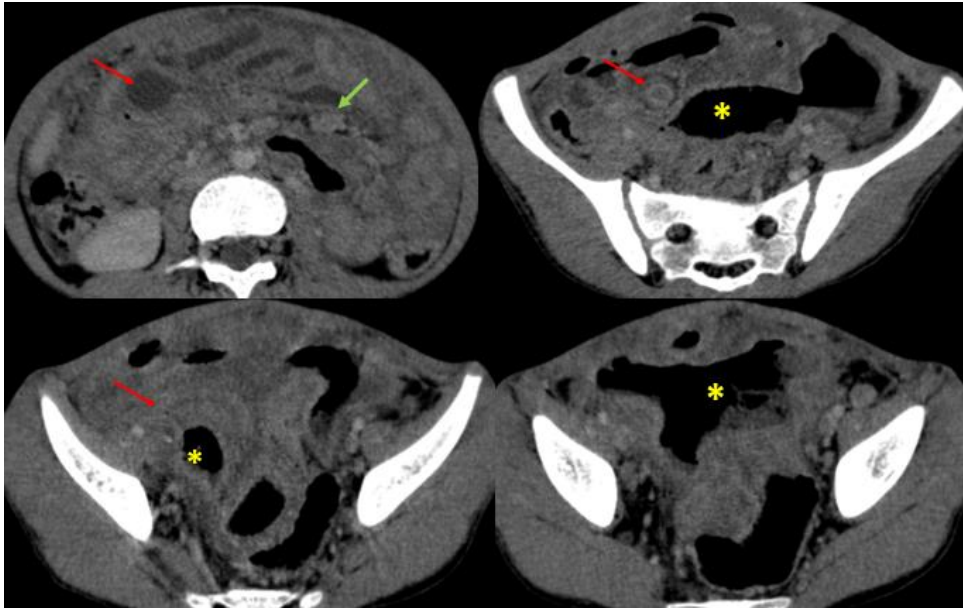
To further investigate the patient, a abdomino-pelvic CT scan was performed, revealing the presence of a voluminous peritoneal collection containing fecal material and air-fluid levels, extending into both iliac fossae, supravescical region (figure 1). The collection was filled with contrast medium after enterocolic opacification with a water-soluble contrast agent, indicating the presence of intestinal perforation (figure 2). Additionally, there was a dense and abundant effusion with diffuse mesenteric infiltration, along with multiple areas of thickening in the digestive walls and deep abdominal adenopathies.

Ultimately, the most probable diagnosis was that of complicated abdominal tuberculosis with digestive perforation. However, the diagnosis of inflammatory bowel disease could not be formally ruled out and was considered as a secondary possibility.

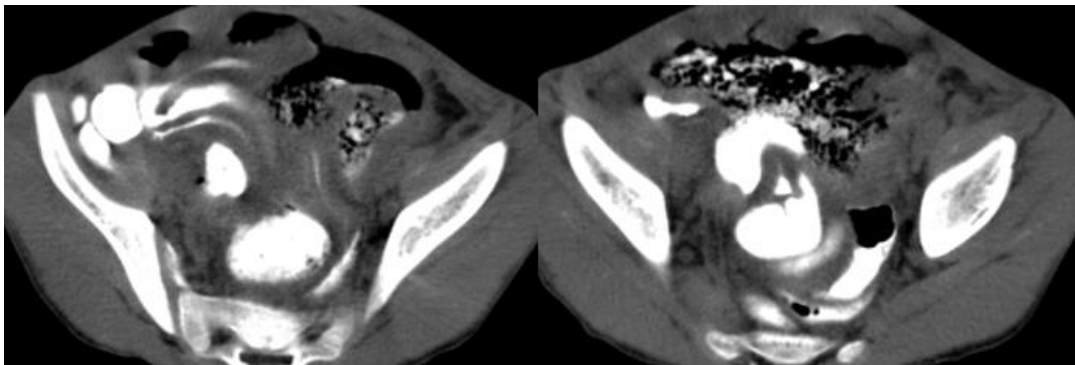
Urgent surgical intervention was requested, leading to an exploratory laparotomy. The procedure revealed widespread micronodular thickening in the peritoneum and bowel (figure 3), indicating a potential tuberculosis (TB) infection. Samples of ascitic fluid and peritoneal tissues were collected and sent for

pathological examination, confirming the presence of chronic granulomatous inflammation and abscess

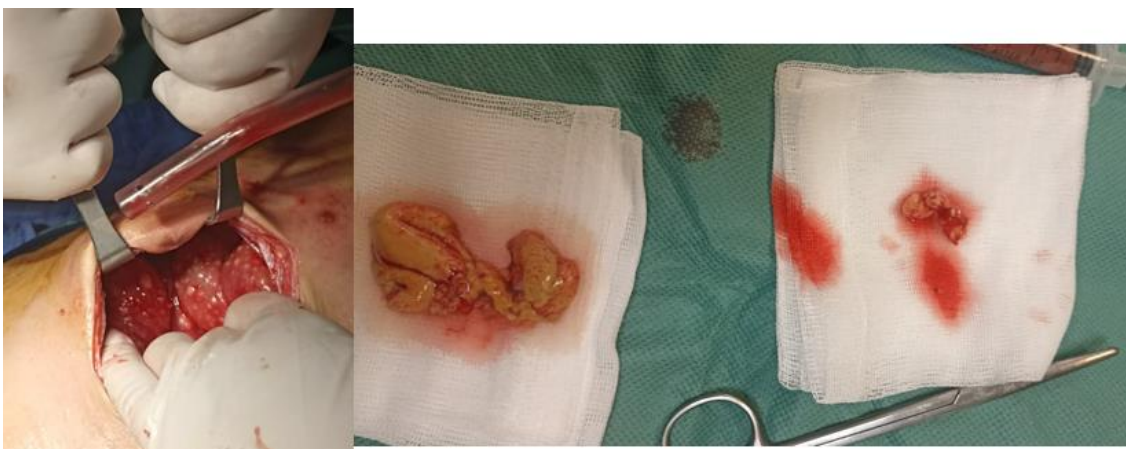formation. The findings were consistent with miliary tuberculosis affecting both the peritoneum and intestines.



**Figure 1:** Abdomino-pelvic CT with portal phase injection, revealing the presence of a voluminous peritoneal collection containing fecal material and air-fluid levels extending into both iliac fossae, supravescicular region(yellow asterisk) associated to dense and abundant effusion with diffuse mesenteric infiltration, along with multiple areas of thickening in the digestive walls(red arrows) , peritoneum, and deep abdominal adenopathies(green arrow)



**Figure 2:** Abdomino-pelvic CT scan with enterocolic opacification using a water-soluble contrast agent: The collection was filled with contrast medium indicating the presence of intestinal perforation



**Figure 3:** Exploratory laparotomy revealed widespread micronodular thickening in the peritoneum and bowel, samples of peritoneal tissues were sent for pathological examination, confirming the presence of chronic granulomatous inflammation and abscess formation consistent with miliary tuberculosis affecting both the peritoneum and intestines

## DISCUSSION

Abdominal tuberculosis primarily occurs in young adults, is rare in children, and remains relatively widespread in developing countries. Tuberculosis peritonitis is the common manifestation of abdominal TB.

The disease is thought to occur following reactivation of latent tuberculous foci in the peritoneum, via hematogenous spread from a previous pulmonary infection. TB peritonitis can also occur via ingestion of myco bacteria with passage through Peyer's patches in the ileum region to mesenteric lymph nodes. Contiguous spread is another route of possible infection [1].

Common symptoms often encompass abdominal pain, fever, diarrhea, constipation, alternating episodes of constipation and diarrhea, weight loss, anorexia, abdominal distension, and night sweats. These symptoms tend to persist for weeks or months before a definitive diagnosis is reached. In individuals exhibiting relevant clinical symptoms and possessing risk factors (such as a history of previous TB infection, residence in or travel to a tuberculosis-endemic area, or immunosuppression), consideration should be given to the possibility of a diagnosis of TB peritonitis [2].

Three distinct types of abdominal tuberculosis have been documented in the literature, each characterized by its presentation [3]:

1. Ascitic type, marked by a substantial accumulation of peritoneal fluid and the presence of multiple peritoneal nodules with a thickness of 1-2mm.
2. Dry type, which is identified by omental thickening, adhesions to small bowel loops, particularly the terminal ileum, often leading to inflammation, perforation, or scarring of the bowel wall, ultimately resulting in intestinal obstruction.
3. ganglionic type, characterized by varying degrees of mesenteric lymph node enlargement, exhibiting a hard consistency and limited mobility. This type also presents with scant to moderate amounts of ascites.

The intraoperative findings in our patient align with a combination of the three forms, as evidenced by the presence of massive purulent ascites, inflammation with perforations of the ileum, and multiple enlarged peritoneal lymph nodes.

In suspected cases of abdominal tuberculosis, ultrasound imaging is recommended to reveal potential indicators such as ascites, echogenic debris, peritoneal and omental thickening, bowel wall thickening, and lymphadenopathy. Confirmatory findings can be obtained through computed tomography (CT) imaging, which is valuable for assessing the extent of disease dissemination. Abdominal CT plays a crucial role in

distinguishing peritoneal tuberculosis from other potential diagnoses by highlighting smooth peritoneal thickening, lymphadenopathy with hypodense centers, and the presence of calcifications and splenic lesions. Notably, CT is effective in evaluating intestinal involvement, showcasing single or multiple transverse, circumferential, transmural ileal, or jejunal ulcers that can lead to strictures during the healing process and, in some cases, perforation. CT is also adept at assessing complications such as inflammation-induced adhesions, intestinal obstruction, bowel perforation, abscesses, and fistulae, often necessitating surgical intervention [4].

When considering differential diagnoses for abdominal tuberculosis, it's essential to distinguish it from conditions such as Crohn's disease, lymphoma, carcinomatosis, ascites, and spontaneous bacterial peritonitis, which may present with similar imaging features [4].

While a high index of clinical suspicion is required, microbiological or histopathological confirmation is usually required to establish a definitive diagnosis. Ultrasound or CT imaging can assist in guiding needle aspiration of ascitic fluid or peritoneal biopsy, providing a means to demonstrate the presence of Mycobacterium in affected sites, such as the peritoneum or intestine.

Treatment for abdominal TB involves antituberculous therapy, and surgical intervention may be required in the presence of complications, as observed in our case. On clinical follow-up, our patient reported a satisfactory recovery [5].

## CONCLUSION

While relatively uncommon in children, abdominal tuberculosis should be considered in the presence of an insidious symptomatology marked by prolonged fever and gastrointestinal disturbances. In our case the issue was the delay in establishing an accurate diagnosis of abdominal tuberculosis, leading to a delay in initiating treatment and consequently resulting in a significant alteration in the clinical presentation, notably with a severe manifestation of stercoral peritonitis. The diagnosis was established through clinical context, by using ultrasound and computed tomography imaging and subsequent intraoperative findings.

## REFERENCES

1. Zaslavsky, J., Mulugeta-Gordon, L., Vasko, I., Prezenza, T., Scattergood, E., Meislich, D., & Germaine, P. (2018). Tuberculous peritonitis in children: Two case reports highlighting the important role of imaging. *Radiology Case Reports*, 13(4), 862-866.
2. Rodríguez, A. E. V., Vidal, A. R. G., Gordillo, R. A., Regalado, C. S. D., Llanes, J. O. S., Vidal, A. A. G., & Llanes, J. O. S. (2023). A Case Report and

Literature Review of Intestinal Perforation Due to Tuberculosis. *Cureus*, 15(8), e43241.

3. Sala, M. L., Verhage, S. M., & Zijta, F. (2021). Abdominal tuberculosis complicated by intestinal perforation. *Case Reports in Gastrointestinal Medicine*, 2021.
4. Ladumor, H., Al-Mohannadi, S., Ameerudeen, F. S., Ladumor, S., & Fadl, S. (2021). TB or not TB: A comprehensive review of imaging manifestations of abdominal tuberculosis and its mimics. *Clinical Imaging*, 76, 130-143.
5. Ngonge, A. L., Ekaney, D. S. M., Sama, C. B., Musonge-Effoe, J., Effoe, V. S., & Ekwen, G. (2017). Multiple jejunal perforation secondary to intestinal tuberculosis infection: a case report. *The Pan African Medical Journal*, 27.