

Giant Hepatic Hemangioma: A Case Report

K. Lemtouni^{1*}, J. Hamdane¹, A. Diani¹, M. Benzalim¹, S. Alj¹

¹Service De Radiologie, Hôpital Ibn Tofail, Chu Mohamed VI, Marrakech, Morocco

DOI: [10.36347/sjmcr.2024.v12i05.057](https://doi.org/10.36347/sjmcr.2024.v12i05.057)

| Received: 22.03.2024 | Accepted: 02.05.2024 | Published: 20.05.2024

*Corresponding author: K. Lemtouni

Service De Radiologie, Hôpital Ibn Tofail, Chu Mohamed VI, Marrakech, Morocco

Abstract

Case Report

A giant hepatic hemangioma is a large benign liver tumor, typically over 10 cm in size. While often asymptomatic, these tumors can cause abdominal discomfort or pain. Diagnosis relies on imaging like ultrasound and CT/MRI scans showing characteristic features. Treatment options include surgery for symptomatic or enlarging tumors, with alternative approaches like embolization or ablation considered in certain cases. Prognosis is generally good with appropriate management, including rare instances of spontaneous regression, especially in postmenopausal women. Further research is needed to refine treatment strategies for giant hepatic hemangiomas.

Keywords: giant hepatic hemangioma, CT/MRI scans, enlarging tumors.

Copyright © 2024 The Author(s): This is an open-access article distributed under the terms of the Creative Commons Attribution 4.0 International License (CC BY-NC 4.0) which permits unrestricted use, distribution, and reproduction in any medium for non-commercial use provided the original author and source are credited.

INTRODUCTION

Hemangiomas stand as the prevailing benign hepatic tumors, exhibiting a prevalence reaching up to 20% within the population [1], notably skewing towards females. Typically, inconspicuous due to their small size and asymptomatic nature, the incidence of giant hemangiomas, remains a rarity in literature. This article presents the case of a male patient diagnosed with a giant hepatic hemangioma discovered incidentally during a routine check-up.

Goal: To review the radiological appearance, diagnostic criteria and complications of these lesions.

CASE REPORT

A 54-year-old man with no significant medical history came for a routine examination. During the interview, recurrent fainting attacks were noted for over a month, accompanied by abdominal pain around the

navel, heaviness in the abdominal cavity and an unexplained weight loss of 5 kg despite stable therapy.

Clinical examination revealed a large, nontender, mobile, difficult to palpate mass in the abdominal cavity. Color Doppler ultrasound showed a well-defined, heterogeneous and sterile mass occupying the entire right lobe of the liver and displacing the adjacent anatomical structures. Magnetic resonance imaging (MRI) revealed an abnormal 18 x 12 x 20 cm liver mass characterized by lobulated margins, T1 hypointensity, T2 hyperintensity and diffusion hyperintensity.

Arterial phase imaging showed peripheral nodal enhancement with centripetal progression, which Vascular structures with peripheral structures included progressing centripetally. Nodular enhancement affecting vascular structures, with localized, nonenhancing scarring after contrast administration.

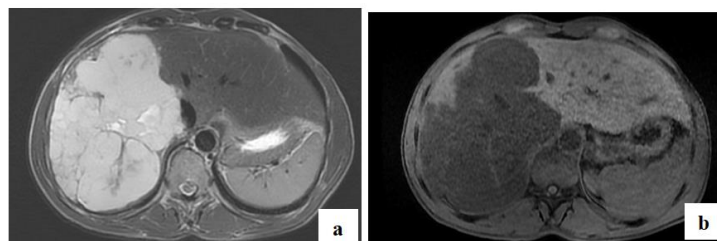


Figure 1: Axial-section T1 and T2 MRI showing the hemangioma in T2 hypersignal (a) and T1 hyposignal (b), septa in T2 hyposignal

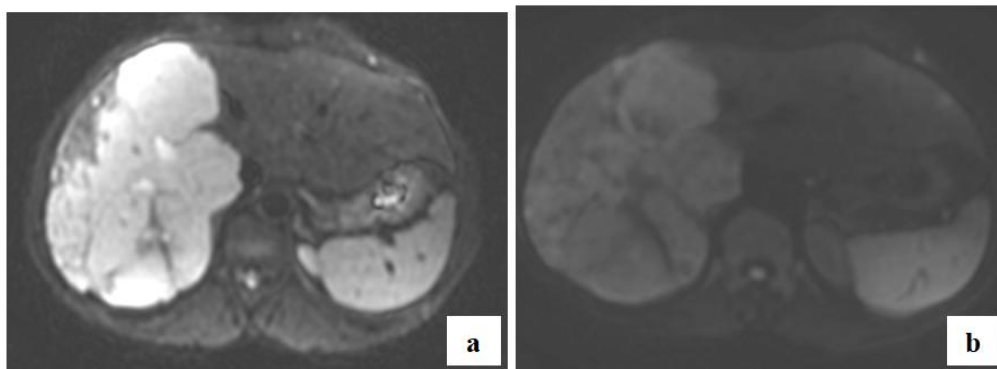


Figure 2: MRI axial section Diffusion sequence showing a drop in signal with increasing b value. B50 (a) B 800 (b)

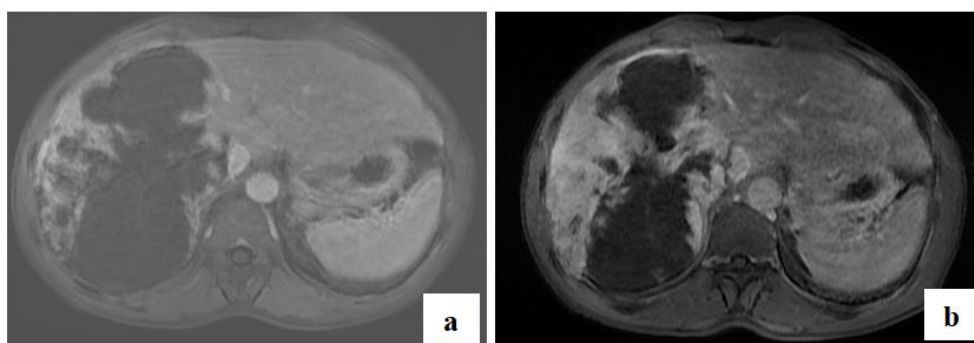


Figure 3: Axial-section T1 MRI after injection of Gadolinium at portal (a) and late (b) times, showing progressive enhancement in clots and centripetes

DISCUSSION

Hepatic hemangiomas is the most common benign mesenchymal tumor of the liver, predominantly affect women across a wide age range and usually occur between the ages of 30 and 50 [1]. These lesions, classified by size, range from small (1 to 2 cm), typical (2 to 10 cm), to giant (>10 cm).

Patients with giant hepatic hemangiomas often present with nonspecific symptoms such as abdominal pain, fullness, or discomfort. In some cases, the tumors may be asymptomatic and discovered incidentally during imaging studies for unrelated reasons. The size of the lesion can vary significantly, ranging from 10 cm to several centimeters in diameter.

Imaging studies play a crucial role in the diagnosis of giant hepatic hemangiomas. Percutaneous biopsy is not recommended in patients due to possible bleeding complications [2].

Ultrasonography typically reveals a well-defined, lobulated mass, heterogeneously hyperechoic in the periphery with posterior acoustic enhancement.

CT scan

Giant hemangiomas are heterogeneous with a central scar of low density. Calcifications are rarely seen [3].

Typically, peripheral, discontinuous, nodular "lumpy" enhancement is seen at arterial time, with progressive centripetal filling at portal time, and complete enhancement at late time. Giant hemangiomas have incomplete or asymmetric enhancement due to the presence of thrombosis, and are often associated with a central, non-enhanced scar, which may be the result of ischemia or hemorrhage.

On MRI

They are hyposignal T1 and intense hypersignal T2, with well-defined round or lobulated contours and typical peripheral, discontinuous, nodular, lumpy enhancement. Hyposignal internal septa are frequently observed, associated with a central scar, unenhanced after gadolinium injection [4].

Giant hemangiomas may show central clefts with intense T2 hypersignal, associated with areas of cystic degeneration or liquefaction. The differential diagnosis mainly includes cholangiocarcinoma, hypervascular metastasis and hepatic angiosarcoma [5].

The management of giant hepatic hemangiomas depends on various factors, including symptoms, lesion size, growth rate, and patient comorbidities. Symptomatic patients or those with significant mass effect may benefit from surgical resection [6]. However, surgery carries risks, including hemorrhage and postoperative liver insufficiency.

For asymptomatic patients with stable lesions, a conservative approach with regular imaging surveillance is often recommended [6]. In select cases, particularly when surgery is contraindicated, transcatheter arterial embolization (TAE) or radiofrequency ablation (RFA) may be considered to reduce tumor size and alleviate symptoms [6].

The prognosis for patients with giant hepatic hemangiomas is generally favorable, with most individuals experiencing symptom relief following appropriate intervention. Spontaneous regression of hepatic hemangiomas has also been reported, particularly in postmenopausal women [7].

Complications associated with giant hemangiomas include inflammatory changes, mechanical compression of adjacent structures, and hemorrhagic events, with Kasabach-Merritt syndrome being a rare complication associated with coagulopathy.

CONCLUSION

Hepatic hemangiomas are often asymptomatic and are usually discovered incidentally. The use of cross-sectional imaging techniques, particularly computed tomography and magnetic resonance imaging, allow accurate diagnosis at different stages of presentation. However diagnosis of minority cases remains uncertain and a surgical exploration might be needed. Mechanical compression of adjacent structures and hemorrhagic events, with Kasabach-Merritt syndrome being a rare complication associated with coagulopathy [8].

REFERENCES

1. Wang, H. Y., Zhang, L., Wu, J., Zhang, Z. J., Peng, B. G., Liang, L. J., & Zhou, Q. (2015). Adult hepatic cavernous hemangioma with highly elevated α -fetoprotein: A case report and review of the literature. *Oncology Letters*, 9(2), 637-640.
2. Evans, J., Willyard, C. E., & Sabih, D. E. (2022). Cavernous Hepatic Hemangiomas. In: StatPearls [Internet]. Treasure Island (FL): StatPearls Publishing; 2022 [cité 15 févr 2023]. Disponible sur: <http://www.ncbi.nlm.nih.gov/books/NBK470283/>
3. Doklešić, K., Stefanović, B., Karamarković, A., Bumbaširević, V., Stefanović, B., Gregorić, P., ... & Bajec, Đ. (2013). Spontaneous rupture of giant liver hemangioma: case report. *Srpski arhiv za celokupno lekarstvo*, 141(1-2), 95-99.
4. Sousa, M. S., Ramalho, M., Herédia, V., Matos, A. P., Palas, J., Jeon, Y. H., ... & Semelka, R. C. (2014). Perilesional enhancement of liver cavernous hemangiomas in magnetic resonance imaging. *Abdominal imaging*, 39(4), 722-730.
5. Klotz, T., Montoriol, P. F., Da Ines, D., Petitcolin, V., Joubert-Zakeyh, J., & Garcier, J. M. (2013). Hepatic haemangioma: common and uncommon imaging features. *Diagnostic and interventional imaging*, 94(9), 849-859.
6. Prasanna, P. M., Fredericks, S. E., Winn, S. S., & Christman, R. A. (2010). Giant cavernous hemangioma. *Radiographics*, 30(4), 1139-1144.
7. Mathew, R. P., Sam, M., Raubenheimer, M., Patel, V., & Low, G. (2020). Hepatic hemangiomas: the various imaging avatars and its mimickers. *La radiologia medica*, 125(9), 801-815.
8. Management of Symptomatic Hepatic « Mega » Hemangioma - PubMed [cité 15 févr 2023]. Disponible sur: <https://pubmed.ncbi.nlm.nih.gov/30972235/>