

## Appendicitis on Appendicular Stump in the General Surgery Department of the Hospital of the District of the Commune IV

Moussa Samaké<sup>1\*</sup>, Yely Dianessy<sup>1</sup>, Souleymane B Dembelé<sup>1</sup>, Abdou Guiré<sup>1</sup>, Yede, D. L. S<sup>1</sup>, Amaguiré Saye<sup>2</sup>, Siraman Diarra<sup>2</sup>, Brahim Dembele<sup>2</sup>, Birama Traoré<sup>3</sup>, Thierno Nadio<sup>4</sup>, Ibrahima Maiga<sup>5</sup>, Mahamane Dicko<sup>6</sup>, Modibo Diarra<sup>7</sup>, Siaka Konaté<sup>8</sup>, Boubacar Diassana<sup>9</sup>, Bathio Traoré<sup>9</sup>, Alou Bina Diarra<sup>10</sup>, Amadou Maiga<sup>11</sup>, Boubacar Yoro Sidibé<sup>11</sup>, Adégné Togo<sup>11</sup>

<sup>1</sup>General Surgery Department of Bamako District IV Hospital, Mali

<sup>2</sup>Obstetric Gynecology Department of the Bamako District IV Hospital, Mali

<sup>3</sup>Gynecology and obstetrics department of the San reference health center, Segou, Mali

<sup>4</sup>Department of ophthalmology of the hospital of the district of the commune IV of Bamako

<sup>5</sup>Imaging Service of the Bamako District IV Hospital, Mali

<sup>6</sup>Anesthesia and resuscitation service of the hospital of the district of the commune IV of Bamako, Mali

<sup>7</sup>Internal medicine department of the district hospital of Commune IV of Bamako, Mali

<sup>8</sup>General Surgery Department, Kolondjeba Referral Health Centre, Sikasso, Mali

<sup>9</sup>Department of General Surgery, Sikasso Hospital, Mali

<sup>10</sup>Anatomopathology department of the CHU of point G, Mali

<sup>11</sup>General Surgery Department of the Gabriel Touré University Hospital, Mali

DOI: [10.36347/sjmcr.2024.v12i05.103](https://doi.org/10.36347/sjmcr.2024.v12i05.103)

| Received: 04.04.2024 | Accepted: 15.05.2024 | Published: 31.05.2024

\*Corresponding author: Moussa Samaké

General Surgery Department of Bamako District IV Hospital, Mali

### Abstract

### Case Report

It is defined as a process of inflammation of the residual appendicular tissue after an appendectomy. CT scan of the abdomen is the most useful imaging method to demonstrate and diagnose the other lesions considered in the differential diagnosis. If missed, it can lead to significant morbidity and mortality with complications such as perforation and peritonitis. We report a case of appendicitis on appendicular stump in a 44-year-old patient with a history of appendectomy in 2017.

**Keywords:** Appendectomy, Appendicular Stump.

**Copyright © 2024 The Author(s):** This is an open-access article distributed under the terms of the Creative Commons Attribution 4.0 International License (CC BY-NC 4.0) which permits unrestricted use, distribution, and reproduction in any medium for non-commercial use provided the original author and source are credited.

## INTRODUCTION

Appendicitis on appendicular stump is not a new diagnosis as it was described in 1945 by Thomas Rose. It is defined as a process of inflammation of the residual appendicular tissue after appendectomy [1].

Although rare, with a reported incidence of 1 in 50,000 appendectomies, underrecognition can cause significant delay in diagnosis and treatment, resulting in serious complications [2].

Laparoscopic appendectomy has also been suggested to contribute to more residue tissue, increasing the risk of stump appendicitis [3].

CT scan of the abdomen is the most useful imaging method to demonstrate and diagnose other lesions considered in the differential diagnosis [4].

If forgotten, it can lead to significant morbidity and mortality with complications including perforation and peritonitis [3].

In this article, we will present the 1st case of appendicitis on appendicular stump in our service.

## CLINICAL CASE

Mrs V T, 44 years old, height: 1.76; weight: 91kg; BMI: WHO: 2; housewife, married, mother of 7 children, with a history of appendectomy performed in 2017.

She consulted us for pain in the right iliac fossa.

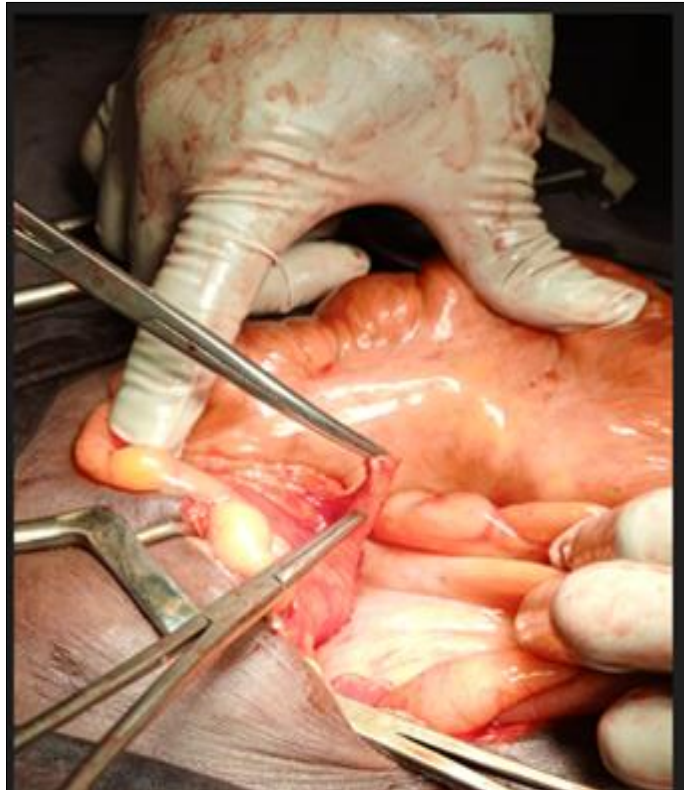
The beginning of the symptomatology goes back to March 2023, marked by pain in the right iliac fossa, intermittent, intense, fixed, a notion of unquantified fever, calmed at times by analgesics. In

front of this table she consulted in several health centers without success.

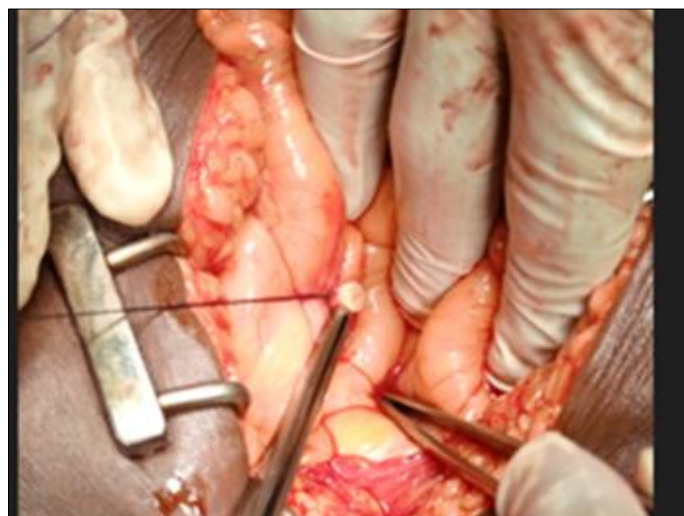
- Clinical examination noted a defense at the right iliac fossa, the blunberg sign was positive.
- Abdominal-pelvic ultrasound was performed, the result was normal.
- The thoraco-abdominal scan was performed, the result was normal.
- The blood count was performed, the result was in favor of a leukocytosis, PN: 12000/ ml.

The diagnosis of post-operative adhesion pain was evoked, in intraoperative, the exploration made it possible to find an epiplo-coecal adhesion, ileocecal, the rest of the organs sus and mesocolic was without peculiarity.

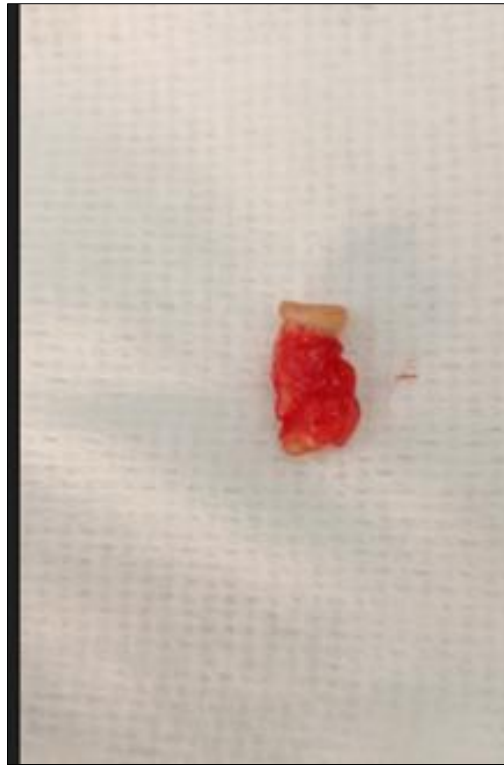
We proceeded to make an adhesiolysse to highlight the appendicular stump, measuring 4cm, phlegmoneux. We concluded an appendicitis on appendicular stump; the treatment consisted of an appendectomy without burying the stump.



**Fig. 1**



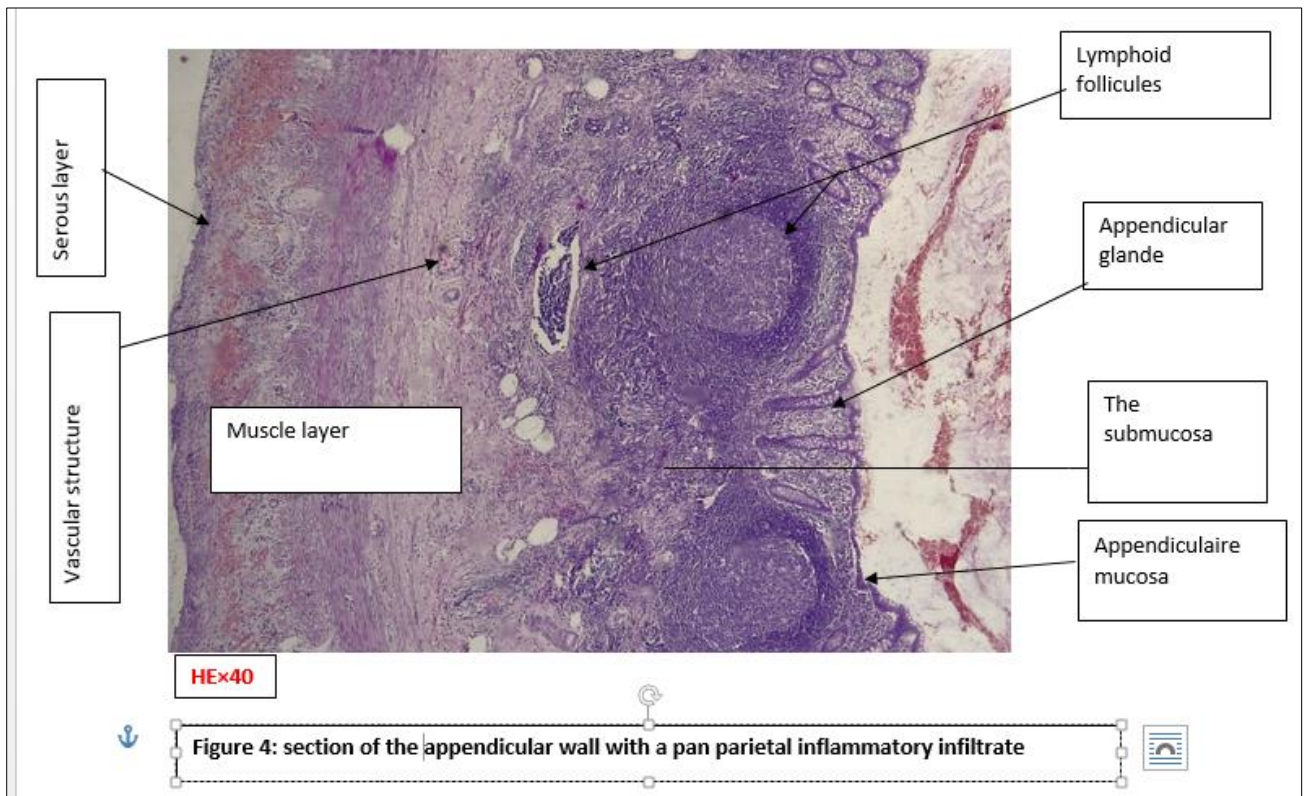
**Fig. 2**



**Fig. 3**

### The Surgical Suites Were Simple

The result of the anato-pathological examination of the operating room was in favor of a phlegmoneuse appendicitis on appendicular stump.



**Fig. 4**

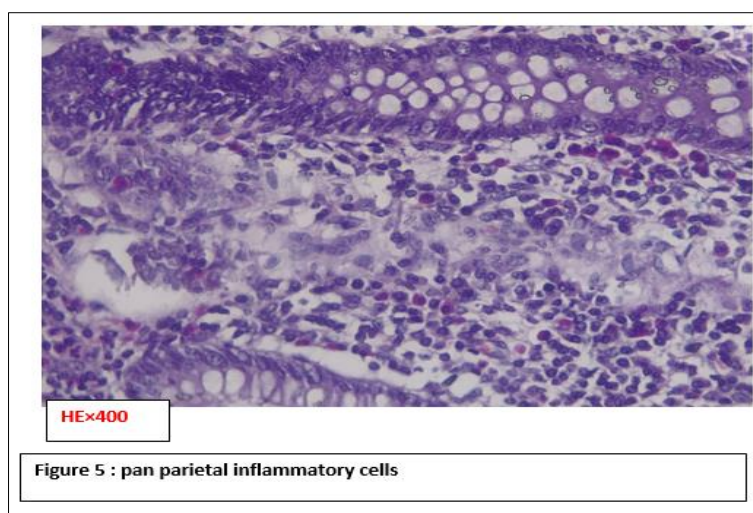


Fig. 5

Table on selected appendicitis variables on appendix stump

Authors/ Variables	Age	Appendectomy duration	Lean stump	Symptoms	Sex	Way of first	Diagnostic means
Yavuz Yuksel	32 years	3 years	2,5 cm	Vomiting, pain, defense	M	-	Echography Scan
Alex C. Essenmacher	11 years 11 years	19 month	2 cm 5 cm	Vomiting, right iliac pain Pain right iliac pit, vomiting, epigastralgia, fever	M F	laparoscopy laparoscopy	Scan Scan
Abdoulah	32 years	8 years		Perumbilical pain, nausea, no fever	M		Scan
Girolamo Geraci	54 ans	46 years	2,5 cm	Vomiting, nausea, no fever	F	Lapartomy	Colonoscopy, scan
Chad A.	42 years	1 years	1,7 cm	Abdominal pain, nausea, vomiting	M	laparoscopy	Scan
Notre cas	44 years	6 years	4 cm	Pain right iliac pit, defense, rowsing+	F	laparotomy	Intraoperationa lly

## COMMENTS AND DISCUSSION

Appendicitis on an appendix stump was first described by Rose in 1945 and Baumgartner in 1949 [5].

Appendicitis on appendicular stump is an undeclared and ill-defined pathology related to obstruction and inflammation of the residual appendix after appendectomy [6].

### Frequency

Appendicitis on appendicular stump is a rare complication after appendectomy. It is important that physicians are aware of this entity to ensure prompt diagnosis and treatment of this unusual condition [2].

We report a case of appendicitis on appendicular stump.

### The Risk Factors

The risk factors mentioned by the authors are many:

According to Alex C. Essenmacher [2], it is believed that it is more frequent after laparoscopic appendectomy, but a comparison with the open technique will become more difficult as this approach becomes less frequent. It is widely considered the result

of a surgical illusion in relation to the actual location of the appendicular base. This can be made more difficult by inflammatory changes and is probably more common after complicated appendicitis.

Abdullah R. Khazindar [1], found that there are many causes of appendicitis on appendicular stump, however, the presence of fecalith, lymphoid hyperplasia or appendicular tumors are the most common causes.

(Kurt E. Roberts,) [7], Reported that although, several factors may contribute to the development of appendicitis on appendicular stump. These factors include inappropriate identification of the base of the appendix and the various locations of the appendix.

Hala Kanona [6], showed that appendicitis on appendicular stump may occur after an open or laparoscopic appendectomy; surgical technique and operating experience, in addition to anatomical variations and complexity of cases at the initial appendectomy, can all play a role in the development of appendicitis on appendicular stump.

According to Hala Kanona [6], an appendix stump length less than 0.5 cm can decrease the risk as long as the surgeon can accurately locate the base of the appendix before the start of the procedure, which can be difficult in cases of severe local inflammation.

Kurt E. Roberts, [7], reported that it is also important to reseat the appendix completely or, leaving an appendix stump, it must be < 3mm in length.

The first route in our patient was laparotomy, the operative report of the 1st intervention was not available.

The appendix stump in our patient was 4 cm.

### Clinical Symptoms

Most patients have acute periumbilical pain radiating to the right iliac fossa (RIF); this pain is frequently associated with nausea, vomiting and fever Abdullah R. Khazindar [1].

Our patient presented pain in the right iliac fossa, defense, Blumberg's sign was positive.

### Paraclinical Examination

Alex C. Essenmacher [2], found that Ultrasound may be a screening tool to assess certain etiologies of abdominal pain, but CT scan with oral and intravenous contrast may be necessary for definitive diagnosis in complicated and unusual cases such as appendicitis on appendicular stump.

Neither the ultrasound examination nor the abdominopelvic CT helped us to have the diagnosis of our patient. The diagnosis of acute appendicitis on appendicular stump was evoked in intraoperative, confirmed by anatomo-pathological examination.

Differential diagnosis: Appendicitis on appendicular stump can be considered as one of the differential diagnoses of acute pain of the right iliac fossa, especially in patients with a history of appendectomy [1-5].

The diagnostic approach of a patient operated on acute appendicitis, presenting pain of the right iliac fossa must take into account the possibility of appendicitis on appendicular stump.

### Processing

There are three basic methods for treating appendicular stump: 1) single ligation, 2) ligation and

inversion, 3) no ligation, inversion. There is no agreement on the best method [8].

In our patient, we performed an appendectomy without burying the stump. The subsequent operations were simple.

## CONCLUSION

Appendicitis on appendicular stump is a rare pathology, the diagnosis must be evoked in front of a patient with a history of appendectomy, and who presents pain of the right iliac fossa.

The abdominal-pelvic CT is the reference complementary examination, its senility is higher than that of ultrasound treatment consists in making an appendectomy of the appendicular stump.

Not taken in, the pathology may evolve to the classic complications of acute appendicitis.

## REFERENCE

1. Khazindar, A. R. (2022). A case of stump appendicitis secondary to appendicular fecolith. *Cureus*, 14(2).
2. Essenmacher, A. C., Nash, E., Walker, S. K., Pitcher, G. J., Buresh, C. T., & Sato, T. S. (2018). Stump appendicitis. *Clinical practice and cases in emergency medicine*, 2(3), 211.
3. Chad, A., Keller, Bea., Rebecca, M., Dudley, DOa., Elizabeth, M., Huycke, DOa., Richard, B., Chow, DOa., & Arjumand, Ali. MD. (2022). *Stump appendicitis. Radiology Case Reports*, 17, 2534–2536.
4. Yuksel, Y., Ergun, T., Torun, E., & Ozen, O. (2021). Recurrent stump appendicitis. *The American Journal of Emergency Medicine*, 44, 481-e3.
5. Geraci, G., Di Carlo, G., Cudia, B., & Modica, G. (2016). Stump appendicitis. A case report. *Int J Surg Case Rep*, 20, 21-3.
6. Kanona, H., Al Samaraee, A., Nice, C., & Bhattacharya, V. (2012). Stump appendicitis: a review. *International journal of surgery*, 10(9), 425-428.
7. Roberts, K. E., Starker, L. F., Duffy, A. J., Bell, R. L., & Bokhari, J. (2011). Stump appendicitis: a surgeon's dilemma. *JSL: Journal of the Society of Laparoendoscopic Surgeons*, 15(3), 373.
8. Ismail, I., Iusco, D., Jannaci, M., Navarra, G. G., Grassi, A., Bonomi, S., ... & Virzì, S. (2009). Prompt recognition of stump appendicitis is important to avoid serious complications: a case report. *Cases Journal*, 2, 1-4.