

Vascular Embols Responsible of Central Retinal Artery Occlusion and Cerebral Vascular Accident during Hypertensive Pic: A Case Report

Yonli Yempabou Hugues Arnaud^{1*}, L. J. V. ERIGA¹, D. A Yaya-Oyé¹, F. K. Sambou OUMAROU¹, Y. Mouzari¹, A. Oubaaz¹

¹Department of Ophthalmology, Hôpital Militaire D'instruction Mohammed V-Rabat, Morocco

DOI: <https://doi.org/10.36347/sjmcr.2024.v12i08.002> | Received: 11.06.2024 | Accepted: 19.07.2024 | Published: 01.08.2024

*Corresponding author: Yonli Yempabou Hugues Arnaud

Department of Ophthalmology, Hôpital Militaire D'instruction Mohammed V-Rabat, Morocco

Abstract

Case Report

We report the case of a 60-year-old patient referred for a sudden drop in visual acuity in the right eye sixteen hours after hypertensive peak. The visual acuity was limited to light perception on the right and 10/10 P2 on the left. The fundus examination revealed occlusion of the central retinal artery, with typical ischemic edema and a cherry-red macula. A fluorescein angiography showed a major circulatory slowdown. A cerebral CT scan also showed ischemic damage. The patient benefited from anticoagulation and oxygen therapy, without any improvement in visual acuity.

Keywords: Visual acuity, hypertensive peak, retinal artery.

Copyright © 2024 The Author(s): This is an open-access article distributed under the terms of the Creative Commons Attribution 4.0 International License (CC BY-NC 4.0) which permits unrestricted use, distribution, and reproduction in any medium for non-commercial use provided the original author and source are credited.

INTRODUCTION

The occlusion of the central retinal artery is a rare pathology and constitutes an ophthalmological emergency, with a multiple etiology that puts at risk not only the visual prognosis, but also the vital prognosis [1]. Management is essentially etiological, with the prognosis reserved for the affected eye. We report the case of a patient with central artery occlusion secondary to a hypertensive spike.

CASE REPORT

This 60-year-old patient, with no known pathological history, particularly cardiovascular, was admitted for a sudden unilateral drop in visual acuity in the absence of a traumatic context on a hypertensive peak.

On admission 16 hours after the event, the patient was neurologically stable, with GCS 15/15, hypertension 20/15 mm hg, and respiratory status stable.

The ophthalmological examination after stabilization of blood pressure revealed visual acuity of 10/10 in the left eye, while vision in the right eye was limited to positive light perception in the temporal region. The intraocular pressure was 17 mm hg in both eyes.

In the anterior segment, the examination reveals areflective semi-mydriasis in the right eye. The rest of the examination was strictly normal in both eyes.

The fundus examination of the right eye revealed signs of hypertensive retinopathy. In the righteye, stage I papilledema, cherry-red macula, ischemic white retinal edema and arterial vessel emboli were noted, suggesting occlusion of the central retinal artery.

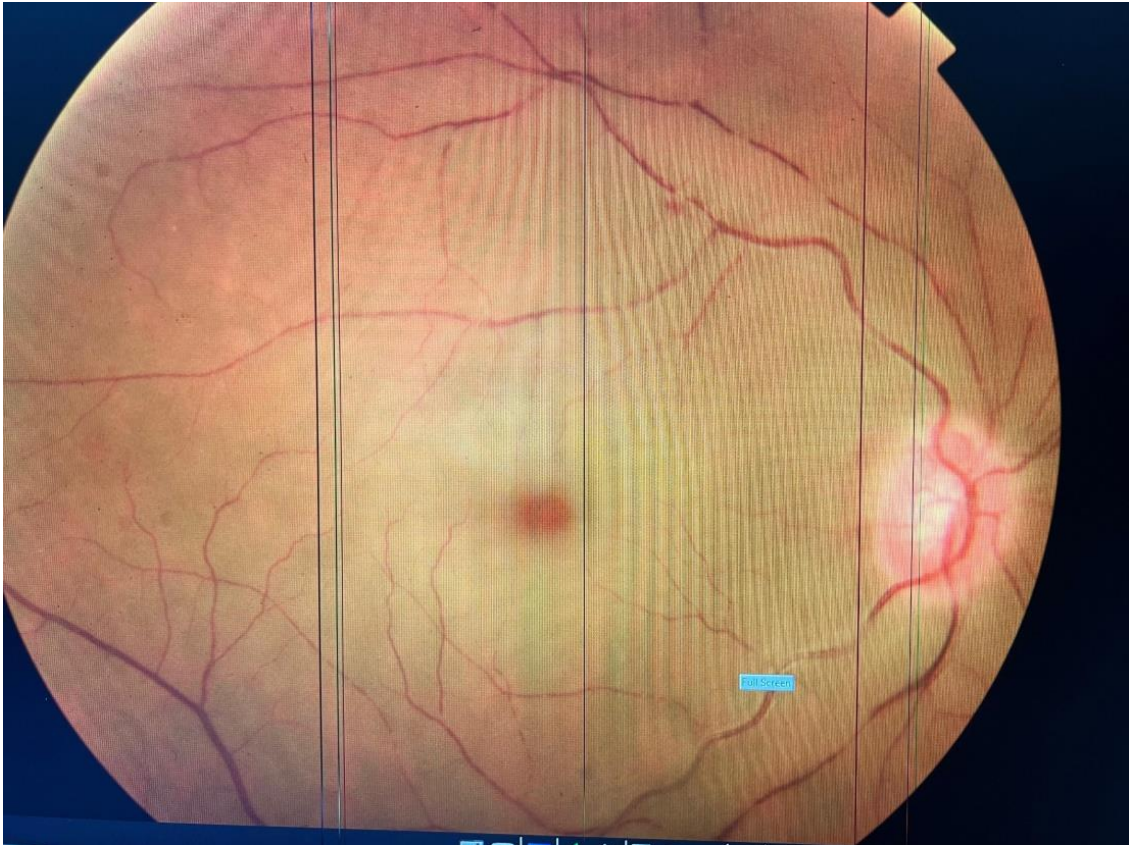

Figure 1: Retinophotography of the right eye with visible emboli on the arterial tracts, red macula, stage 1 papilledema

The hypertensive peak was urgently controlled with intravenous Nicardipine (Loxen).

The examination was completed by fluorescein angiography, which supported the diagnosis with delayed arterial filling.

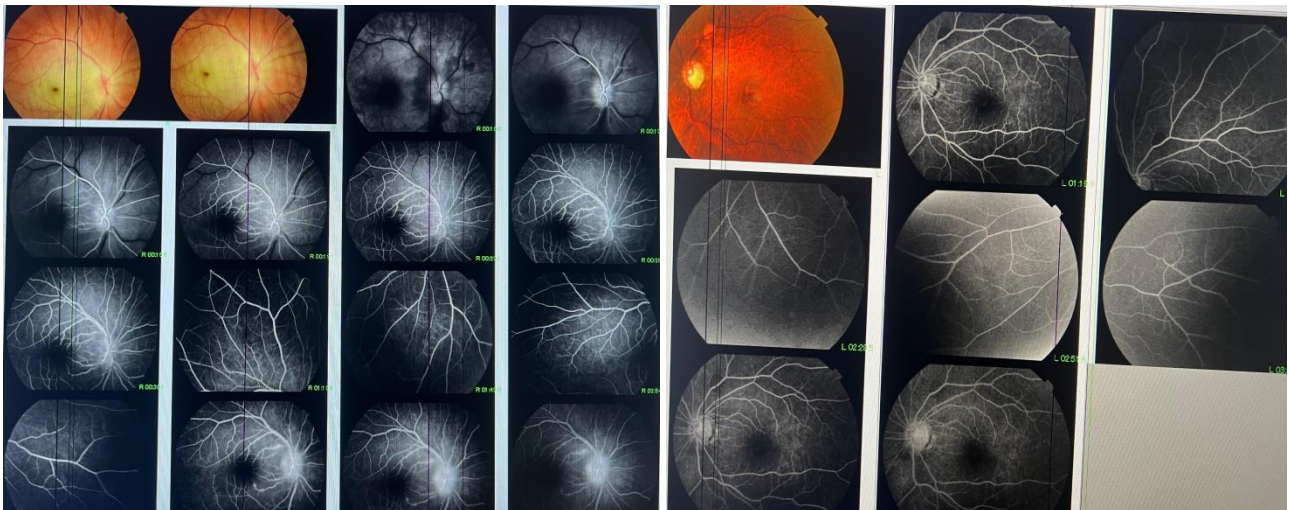


Figure 2: Angiography with delayed filling of the right eye. Left eye normal

As part of the etiological investigation, a cardiac work-up and cerebral imaging were performed.

Cerebral CT revealed ischemic territories. The cardiac work-up diagnosed arterial hypertension in an embolic setting.

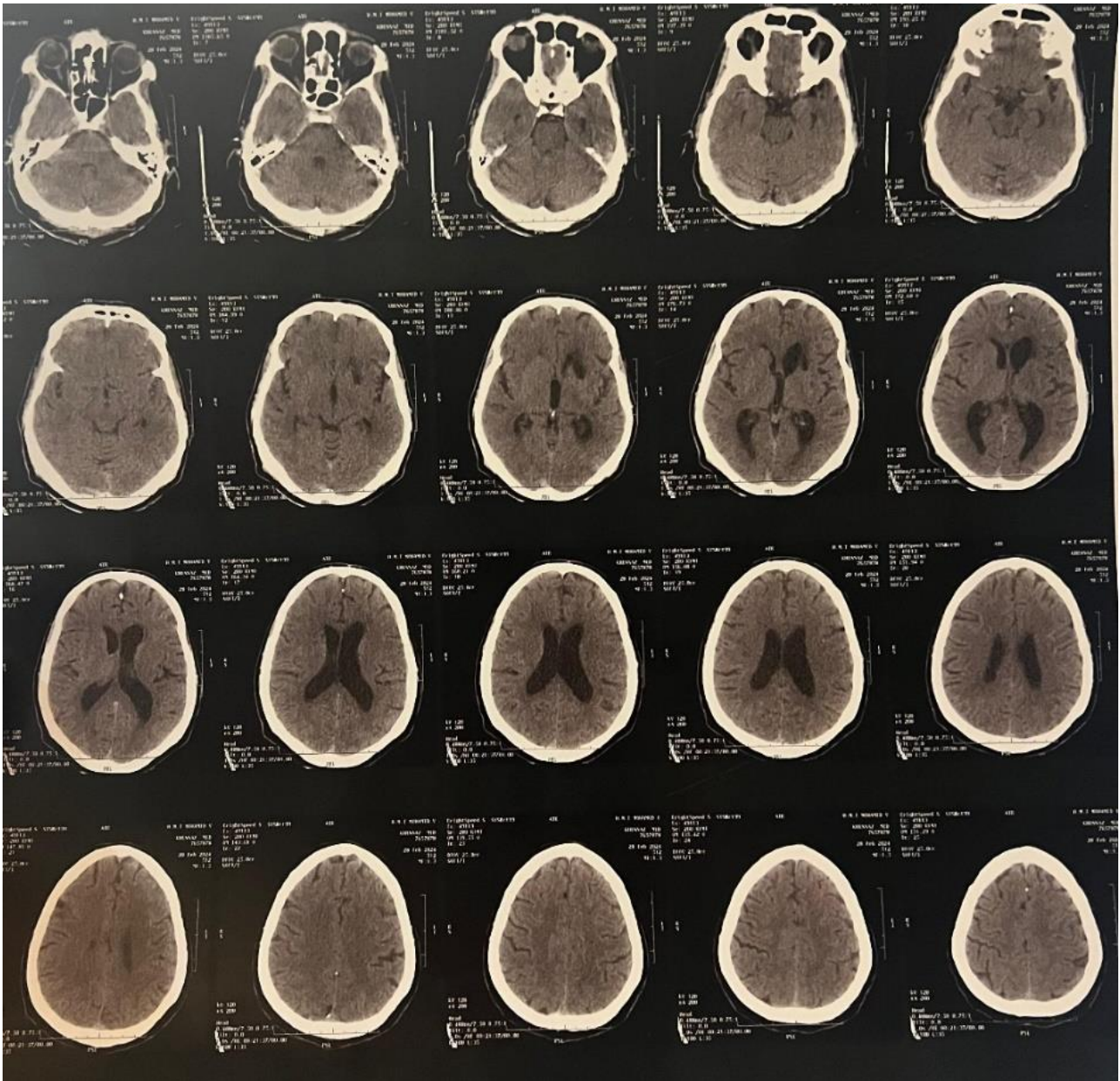


Figure 3: Cerebral CT scan showing ischemic territories

The ophthalmological treatment consisted of aspirin (Kardelic 160mg) + statins (Nocol) combined with hyperbaric oxygenotherapy at a frequency of 3 sessions per week. Due to the delay in admission and advanced age, no other treatment was added, notably fibrinolytics and vasodilators. No gain in acuity was reported.

The patient was then referred to the cardiology department for further management, with monthly ophthalmological monitoring for 3 months and then semi-annually.

DISCUSSION

Occlusion of the central retinal artery is a rare condition, estimated at 1 per 10,000 consultations. It is most often unilateral, as in our case, and bilaterality is

estimated to occur in between 1% and 2% of cases [2, 3]. The main risk factors are cardiovascular, including arterial hypertension [4, 5]. Diagnosis is most often clinical, and includes a sudden drop in visual acuity on a painless white eye, with a mostly normal anterior segment and characteristic fundus abnormalities: retinal white eye, narrowing of the arterial caliber, a cherry-red macula [6]. The examination can be supplemented by angiography without delaying management. The etiologies are dominated by emboli, thrombosis and coagulation disorders. The particularity of our patient is the visibility of vascular emboli on the fundus (in the absence of a surgical procedure) associated with cerebral emboli, which is a rare event [7]. In this situation, given the delay in admission, management is essentially focused on protecting the contralateral eye, as the affected eye has already been lost [8-10].

CONCLUSION

The occlusion of the central retinal artery is a diagnostic and therapeutic emergency. Early management can offer hope of relative repermeabilisation, even if the prognosis is poor. The challenge is to prevent complications and bilateralisation in unilateral cases.

REFERENCES

- Hayreh, S. S. (2011). Acute retinal arterial occlusive disorders. *Progress in retinal and eye research*, 30(5), 359-394.
- Occlusions Arteriellles Retiniennes, Collège des Ophtalmologistes Universitaires de France (COUF).
- Leavitt, J. A., Larson, T. A., Hodge, D. O., & Gullerud, R. E. (2011). The incidence of central retinal artery occlusion in Olmsted County, Minnesota. *American journal of ophthalmology*, 152(5), 820-823.
- Rudkin, A. K., Lee, A. W., & Chen, C. S. (2010). Vascular risk factors for central retinal artery occlusion. *Eye*, 24(4), 678-681.
- Callizo, J., Feltgen, N., Pantenburg, S., Wolf, A., Neubauer, A. S., Jurklies, B., ... & European Assessment Group for Lysis in the Eye. (2015). Cardiovascular risk factors in central retinal artery occlusion: results of a prospective and standardized medical examination. *Ophthalmology*, 122(9), 1881-1888.
- Mitral, R. D. U. R. Occlusion De L'artere Centrale De La Rétine.
- Rim, T. H., Han, J., Choi, Y. S., Hwang, S. S., Lee, C. S., Lee, S. C., & Kim, S. S. (2016). Retinal artery occlusion and the risk of stroke development: twelve-year nationwide cohort study. *Stroke*, 47(2), 376-382.
- Cugati, S., Varma, D. D., Chen, C. S., & Lee, A. W. (2013). Options de traitement pour l'occlusion de l'artère centrale de la rétine. *Options de traitement actuelles en neurologie*, 15, 63-77.
- Chen, C. S., & Lee, A. W. (2008). Management of acute central retinal artery occlusion. *Nature Clinical Practice Neurology*, 4(7), 376-383.
- Varma, D. D., Cugati, S., Lee, A. W., & Chen, C. S. (2013). A review of central retinal artery occlusion: clinical presentation and management. *Eye*, 27(6), 688-697.