

## Dermoscopy of Lymphangioma Circumscriptum

Fajri Zineb<sup>1\*</sup>, Hanane Baybay<sup>1</sup>, Meryem Soughi<sup>1</sup>, Zakia Douhi<sup>1</sup>, Sara Elloudi<sup>1</sup>, Fatima Zahra Mernissi<sup>1</sup>

<sup>1</sup>Department of Dermatology, University Hospital Hassan II of Fez

DOI: <https://doi.org/10.36347/sjmcr.2024.v12i09.006>

| Received: 25.07.2024 | Accepted: 31.08.2024 | Published: 03.09.2024

\*Corresponding author: Fajri Zineb

Department of Dermatology, University Hospital Hassan II of Fez

### Abstract

### Original Research Article

**Background:** Cutaneous lymphangiomas are congenital lymphatic malformations, which may involve the skin and subcutaneous tissue and can occur on any cutaneous surface or mucous membrane. Cutaneous lymphangiomas are uncommon, accounting for 4% of all vascular tumours. Dermoscopy is a non-invasive technique, which has greatly improved the diagnostic of cutaneous lymphangiomas. **Objective:** Our aims were to describe the different dermoscopic patterns of lymphangioma circumscriptum. **Methods:** We performed a descriptive retro-prospective observational study that included all patients diagnosed with DM in dermatology department over 2 years from 2019 to 2021. **Results:** A total of 14 cases of lymphangioma circumscriptum were studied. Ranging in age from 3 to 38 years. The most common structure we found in lymphangioma circumscriptum was the presence of lacunae, which were found in 12 of patients (85%) These lacunae were red or dark in colour in 6 cases (50%), yellowish or whitish in 5 cases (35,7%) and multicoloured (yellow, white, red and white in the same patient) in 4 cases (28%).The second most common dermoscopic structure was the presence of vascular structures, which were found in 82% of patients .Other dermoscopic structures were white lines, found in 9 cases (64%) ,the hypopyon sign or two-tone lacunae in 4 (28%). **Conclusion:** Recognition of dermoscopic features of eyebrow trichotillomania is very important and could help to diagnosis of lymphangioma circumscriptum.

**Keywords:** Lymphangioma Circumscriptum, Dermoscopy.

Copyright © 2024 The Author(s): This is an open-access article distributed under the terms of the Creative Commons Attribution 4.0 International License (CC BY-NC 4.0) which permits unrestricted use, distribution, and reproduction in any medium for non-commercial use provided the original author and source are credited.

## INTRODUCTION

Cutaneous lymphangiomas are congenital lymphatic malformations which may involve the skin and subcutaneous tissue and can occur on any cutaneous surface or mucous membrane. Cutaneous lymphangiomas are uncommon, accounting for 4% of all vascular tumours.<sup>1</sup> Cutaneous lymphangiomas are divided into two major groups: superficial and deep. The most common of these is lymphangioma circumscriptum, which is also known as superficial lymphatic malformation. Histologically, lymphangioma circumscriptum is characterised by many dilated lymphatic channels usually located in the superficial dermis, although they may extend to the reticular dermis or subcutaneous tissue. Clinically, lymphangioma circumscriptum is characterised by clusters of translucent vesicles resembling frog spawn soon after birth, although they are possible at any age. The differential diagnoses of lymphangioma circumscriptum include lymphangiectasia, haemangiomas, angiokeratomas, angiosarcomas, cutaneous metastases, warts and molluscum contagiosum.<sup>1,2</sup> Dermoscopy is a non-invasive technique, which has greatly improved the

diagnostic accuracy of pigmented and non-pigmented skin tumours.

**Objectives:** Our aims were to describe the different dermoscopic patterns of lymphangioma circumscriptum

## MATERIALS AND METHODS

A retrospective descriptive study over a 3-year period, included.

Dermoscopic images proven cases of lymphangioma circumscriptum, collected in the dermatology department. Clinical data were obtained for each patient, including their age and sex and the anatomical location of the lesions. No pressure was used to avoid the collapse of the vessels in the lesions. Images of each lesion were obtained using dermoscopic images were taken using DermLite and smartphones; interpretation of images was done by two investigators.

## RESULTS

A total of 14 cases of lymphangioma circumscriptum were studied. The lesions affected. 10

children and 4 adults, ranging in age from 3 to 38 years. The lymphangioma was located on the tongue in 3 patients, inguinal in 5 patients, 4 on the limbs one, on the nipple and one at the labial commissure in one patient and on the arm in one patient. Clinically, the lymphangiomas presented as clusters of vesicles of varying colour, sometimes translucent and sometimes purplish red. Differential diagnoses at the clinical stage were genital condyloma for inguinal lymphangiomas and herpes for lymphangiomas located in the labial commissure, Dermoscopy is a non-invasive technique which enabled the diagnosis to be made thanks to the typical appearance of lymphangiomas and to eliminate differential diagnoses.

A careful dermoscopic examination of the lesions allowed the following features to be observed the most common structure we found in lymphangioma circumscriptum was the presence of lacunae, which were found in 12 of patients (85%) (Figure 1-2-3). These lacunae were red or dark in colour in 6 cases (50%), yellowish or whitish in 5 cases (35,7%) and multicoloured (yellow, white, red and white in the same patient) in 4 cases (28%). (Figure 3) The second most common dermoscopic structure was the presence of vascular structures, which were found in 82% of patients (Figs 1-2). Other dermoscopic structures were white lines, found in 9 cases (64%) (Figure 1); the hypopyon sign or two-tone lacunae in 4 (28%) (Figs 4)

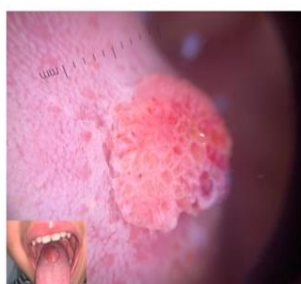


Figure 1 : Oral lymphangiomas. Dermoscopically, we see yellow lacunae, white lines and vascular structures

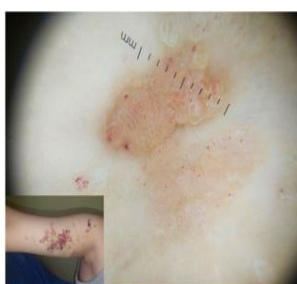

Figure 3 : Lymphangioma circumscriptum located on the arm of a 6-year-old child. The dermoscopic view shows a multicoloured lacunae red , and yellowish incipient white line, vascular structures and a yellowish background.

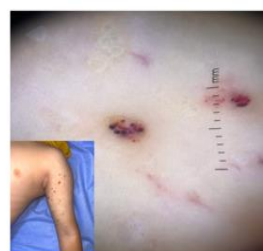

Figure 5 : lymphangioma circumscriptum located on the arm of a 10-year-old child shows only dark lacunae, mimicking a solitary angiokeratoma.

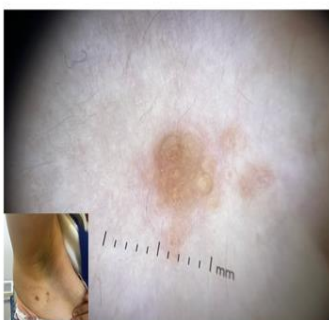

Figure 2 : lymphangiomas circumscriptum located on the axilla of a 28-year-old woman. . Dermoscopically, we see yellow lacunae, white lines and vascular structures

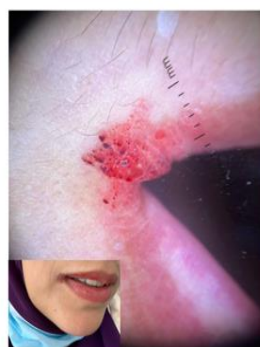

Figure 4 : Asymptomatic, erythematous papule located on the oral commissure of a 33-year-old woman. The dermoscopic view shows a pattern composed of red lacunae with hypopyon sign, white lines and vascular structures.

## DISCUSSION

Our study found that the most common dermoscopic pattern associated with lymphangioma circumscriptum is the presence of lacunae and vascular structures.<sup>2-5</sup> Lacunae are defined as multiple, clustered, well-demarcated, yellowish, reddish, or dark-coloured structures with a round to oval shape and they were found in 85% of our patients. The histopathological correlation of these lacunae is the presence of dilated, thin-walled vessels in the papillary dermis which are the hallmark of many vascular tumours.<sup>2-8</sup> the colour of these lacunae depends on their content. The whitish, light tan to yellow coloration is due to lymphatic fluid. The pinkish or reddish colour is due to the presence of red blood cells in the dilated lymphatic channels. When

they are partially or completely thrombosed, the lacunae can be dark violaceous, blue- black or black in colour. These are called dark lacunae<sup>2-8</sup> of lymphangioma circumscriptum patients. In some cases, a two-tone lacuna or a colour transition from dark (at the bottom) to light (at the upper part) in the same lacuna was between small blood vessels and lymphatic channels may be one source.<sup>1</sup> In our opinion, the presence of vascular structures in the dermoscopic view of 82% of our lymphangioma circumscriptum patients is the correlation of these micro-shunts, since in many cases these vascular structures are connected to red or dark lacunae. Other dermoscopic structures observed in our lymphangioma circumscriptum patients were white lines separating the lacunae. The histopathological correlation of the white lines could be the presence of fibroplasia, seen in many

cases of lymphangioma circumscriptum. The presence of scales was common in hyperkeratotic lymphangioma circumscriptum and is due to epidermal hyperplasia or hyperkeratosis.

A diagnosis of lymphangioma circumscriptum is usually easy based on its clinical aspect and behaviour. Lymphangioma circumscriptum is commonly characterized by clusters of translucent vesicles filled with lymphatic fluid and is more frequently seen in children, but they may arise at any age. Occasionally, solitary lesions are present or can show an atypical appearance. The differential diagnoses of lymphangioma circumscriptum include haemangiomas, angiokeratomas, pyogenic granulomas, angiosarcomas, cutaneous metastases, warts and molluscum contagiosum.<sup>1,2</sup> Dermoscopy can help in making the correct diagnosis. Multiple lacunae and vascular structures, are also found in haemangiomas and solitary angiokeratomas. The hallmark of a haemangioma is the presence of red or, in case of thrombosed lesions,<sup>8</sup> dark-coloured lacunae and the most common pattern associated with solitary angiokeratomas is one composed of dark lacunae and a whitish veil.<sup>6</sup> Neither whitish or yellowish lacunae nor the hypopyon sign have been associated with haemangiomas or solitary angiokeratomas in the literature.<sup>6–8</sup> However, we can find some vascular structures in some haemangiomas, above all in the arteriovenous variant, and in 3% of solitary angiokeratomas.<sup>6</sup> When extravasation of blood is marked, dermoscopic findings of lymphangioma circumscriptum are indistinguishable from those of haemangiomas.

## CONCLUSION

The presence of lacunae and vascular structures is the most common dermoscopic pattern associated with lymphangioma circumscriptum. The hypopyon sign and the white or yellowish coloration of lacunae are very characteristic of lymphangioma circumscriptum. Vascular structures were found in 82% of our patient.

## REFERENCES

- Arpaia, N., Cassano, N., & Vena, G. A. (2006). Dermoscopic features of cutaneous lymphangioma circumscriptum. *Dermatologic surgery*, 32(6), 852-854.
- Haliasos, E. C., Kerner, M., Jaimes, N., Zalaudek, I., Malvey, J., Lanschuetzer, C. M., ... & Marghoob, A. A. (2013). Dermoscopy for the pediatric dermatologist, part ii: dermoscopy of genetic syndromes with cutaneous manifestations and pediatric vascular lesions. *Pediatric dermatology*, 30(2), 172-181.
- Massa, A. F., Menezes, N., Baptista, A., Moreira, A. I., & Ferreira, E. O. (2015). Cutaneous Lymphangioma circumscriptum-dermoscopic features. *Anais brasileiros de dermatologia*, 90, 262-264.
- Patel, G. A., & Schwartz, R. A. (2009). Cutaneous lymphangioma circumscriptum: frog spawn on the skin. *International journal of dermatology*, 48(12), 1290-1295.
- SCOPE, A., Amini, S., Kim, N. H., Zell, D. S., Oliviero, M. C., & Rabinovitz, H. S. (2008). Dermoscopic-histopathologic correlation of cutaneous lymphangioma circumscriptum. *Archives of dermatology*, 144(12), 1671-1672.
- Zalaudek, I., Giacomel, J., & Cabo, H. (2008). Entodermoscopy: a new tool for diagnosing skin infections and infestations. *Dermatology*, 216, 14-23.