

4 Years Old Boy with Relapsing Juvenile Dermatomyositis without Skin Manifestation

Dr. Amal Ashour Elbasha^{1*}, Dr. Mai Alsammak²

¹Consultant Paediatrician, Al Mashaf Health Centre, Primary Health Care Corporation, Qatar

²Consultant Family Medicine, Madinat Khalifa Health Centre, Primary Health Care Corporation, Qatar

DOI: <https://doi.org/10.36347/sjmcr.2025.v13i02.013>

| Received: 14.01.2025 | Accepted: 19.02.2025 | Published: 21.02.2025

*Corresponding author: Dr. Amal Ashour Elbasha

Consultant Paediatrician, Al Mashaf Health Centre, Primary Health Care Corporation, Qatar

Abstract

Review Article

We report a 4-year-old boy with North African Heritage who presented initially with low grade fever, mild pharyngitis and myopathy which had led to myositis diagnosis based on muscle biopsy and MRI findings. He also had positive parvovirus IgG, and elevated inflammatory markers. He responded well to corticosteroid but subsequently experienced two relapses. The first relapse upon withdrawing the corticosteroid treatment. It was controlled by corticosteroid, methotrexate and immunoglobulin therapy. During this relapse he tested positive to streptococcal throat infection. The second relapse followed withdrawal of methotrexate treatment and was again managed successfully with corticosteroids, methotrexate and immunoglobulin treatment as discussed in detail below. Upon reevaluation of the muscle biopsy and repeat MRI findings, the diagnosis was revised to juvenile dermatomyositis (JDM) without dermatological manifestations. This case is notable for the absence of skin involvement, a relapsing disease course, and inconclusive muscle biopsy and bone findings on MRI. Additionally, it highlights the critical role of immunoglobulin therapy in refractory myositis. Our findings suggest that muscle biopsy should be considered for accurate diagnosis in suspected inflammatory muscle disease, even when dermatological symptoms are absent.

Keywords: Juvenile dermatomyositis, proximal myopathy, Muscle Biopsy, MRI, negative myositis antibodies, skin manifestation, antirheumatic agents, glucocorticoids, intravenous immunoglobulins, subcutaneous methotrexate.

Copyright © 2025 The Author(s): This is an open-access article distributed under the terms of the Creative Commons Attribution 4.0 International License (CC BY-NC 4.0) which permits unrestricted use, distribution, and reproduction in any medium for non-commercial use provided the original author and source are credited.

INTRODUCTION

Juvenile myositis represents a diverse group of systemic autoimmune diseases. These diseases manifest in various clinical and serologic subgroups, each presenting unique clinical symptoms, disease progressions, genetic associations, treatment responses, and prognoses [1]. Juvenile dermatomyositis (JDM) is noted as the most common inflammatory myopathy in children [2].

Juvenile Dermatomyositis (JDM) is a rare autoimmune myopathy that manifests in childhood, primarily as a capillary vasculopathy affecting the skin and skeletal muscles. The definitive cause of JDM is unclear, but it is proposed to be due to an autoimmune reaction in a genetically susceptible individual, possibly triggered by infections such as Group A streptococcal infection or other environmental factors. The peak incidence of JDM occurs between the ages of 5 and 10 years [6, 9, 10]. Girls are affected two to five times more often than boys [10, 11]. The presence of muscular weakness with characteristic skin involvement is a key

feature of JDM. Research is ongoing to improve early detection, personalized treatment, and long-term outcomes for JDM patients [5].

Initial Presentation

On May 10, 2015, a five-year-old boy was brought to Helios Hospital Cuxhaven with a 10-day history of fever without a clear focus, accompanied by weakness in all limbs and swelling in the right arm, leg, and foot. The fever was low-grade, accompanied by a sore throat, and treated with antibiotics without improvement. The child's condition worsened, and he was unable to walk. No cause was found for these complaints, leading to his transfer to a specialized clinic for further investigation. Notably, there was no history of dysphagia. He was born after a complication-free pregnancy at 38 weeks and had an unremarkable neonatal period.

Previous Medical History

In February 2015, he was diagnosed with a myoclonic seizure and is on Valproate. His family

history revealed cousins with epilepsy, but his two siblings are healthy. There is no blood relation between his parents.

Physical Examination

On examination, he was febrile and in pain, with swelling in the right leg (circumference 22 cm compared to 20 cm on the left) and swollen right foot and elbow area without redness. He walked with a limp. No skin pathologies or spine deformities were noted. Muscle bulk was normal, but there was generalized tenderness and reduced power (3/5) in proximal muscle groups of both upper and lower limbs. There was no Calcinosis cutis.

Laboratory Investigations

Initial lab tests showed:

- Normal blood count, liver function tests, and kidney function tests.
- Elevated CRP (58 mg/l) and ESR (56 mm/hour).
- Negative serologies for CMV, EBV, Borrelia, ANA, and ANCA.

- Positive Parvovirus IgG.

Further investigations, including echocardiography, chest X-ray, bone marrow aspiration, and lumbar puncture, were unremarkable.

MRI and Biopsy Findings

A full-body MRI performed due to persistent symptoms with an unclear cause showed increased signal intensity in muscular compartments, consistent with myositis. No abscess collection was found. Intracerebrally, there were no signs of bleeding, ischemia, mass effect, nor structural anomalies. A muscle biopsy revealed lymphohistiocytic infiltrates perivascularly in the perimysium, suggesting dermatomyositis or vasculitis; however, specific indications of dermatomyositis were lacking. Myositis antibodies were negative. *Since that patient had epilepsy and myositis together, MERRF (Myoclonus Epilepsy with Ragged – Red Ribers) was also considered, which was ruled out by muscle biopsy.* Based on clinical features, biopsy, and MRI findings, the diagnosis of myositis was made.

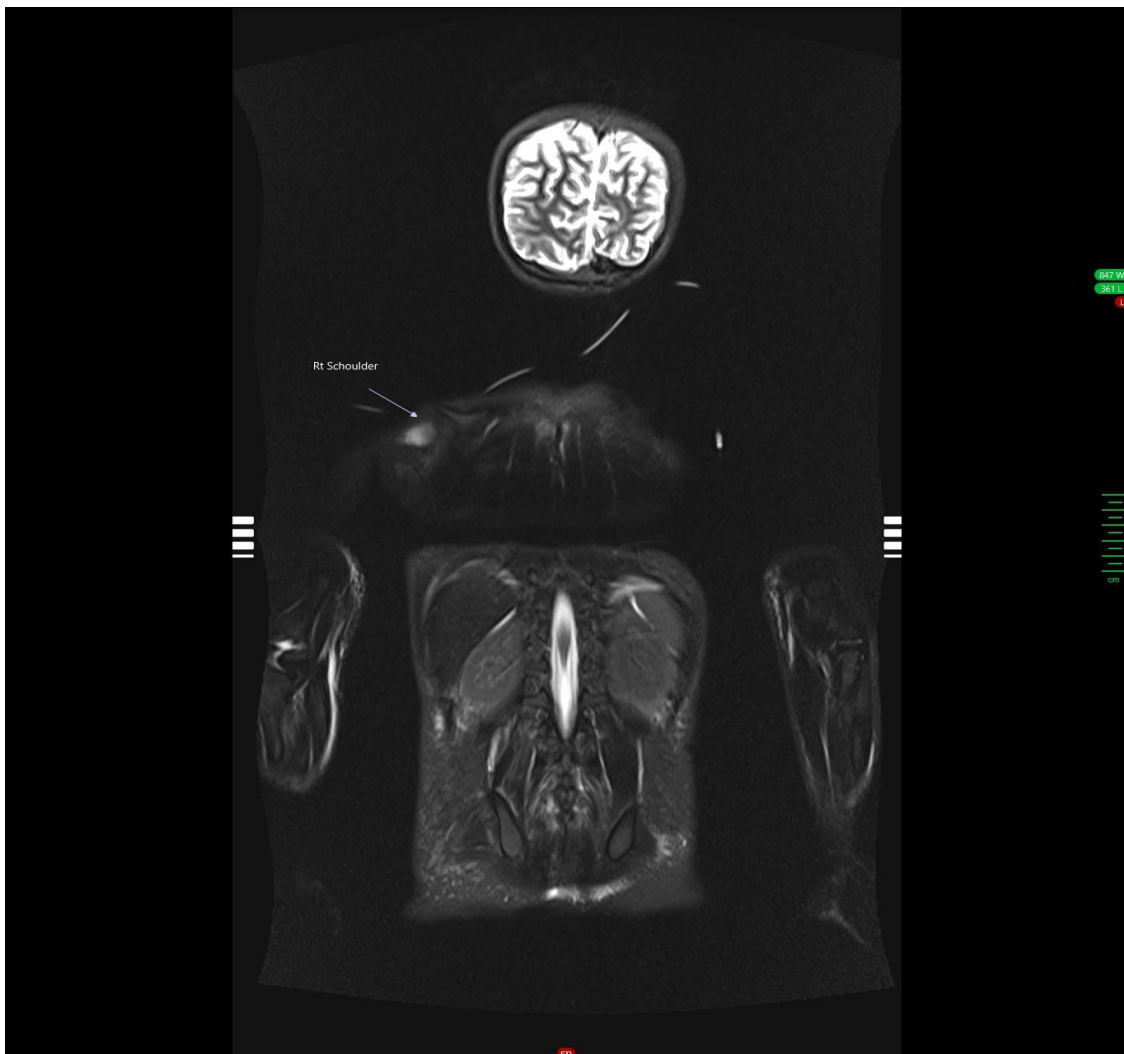


Figure 1: MRI finding: Right shoulder increased muscular signal intensity indicating myositis

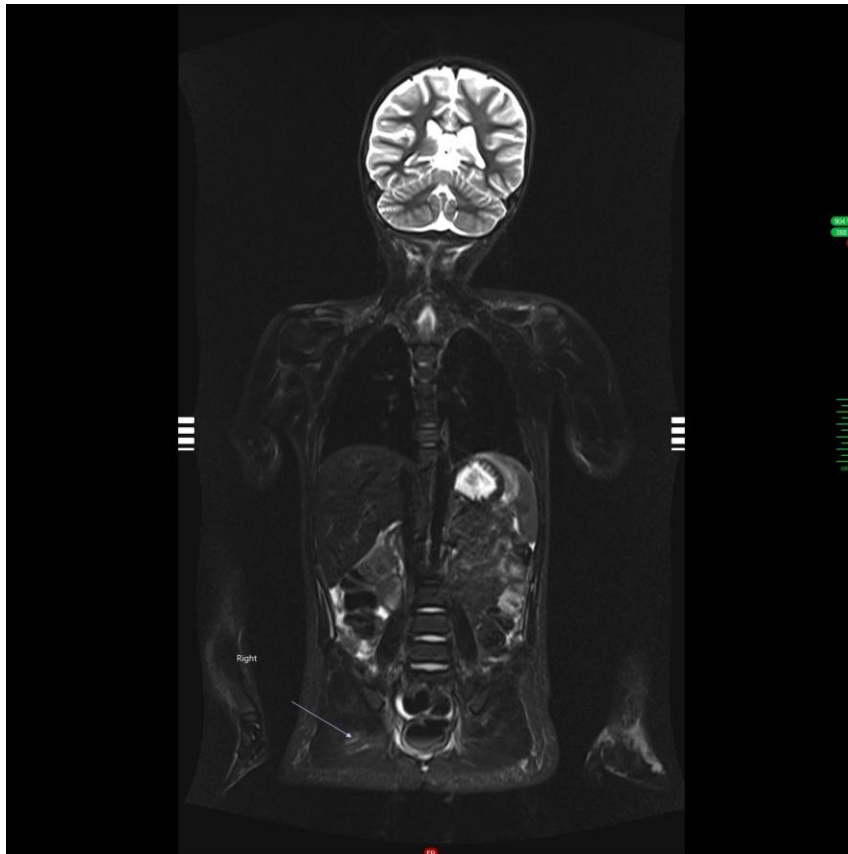


Figure 2: MRI finding: Pelvic muscles increased signal intensity indicating myositis

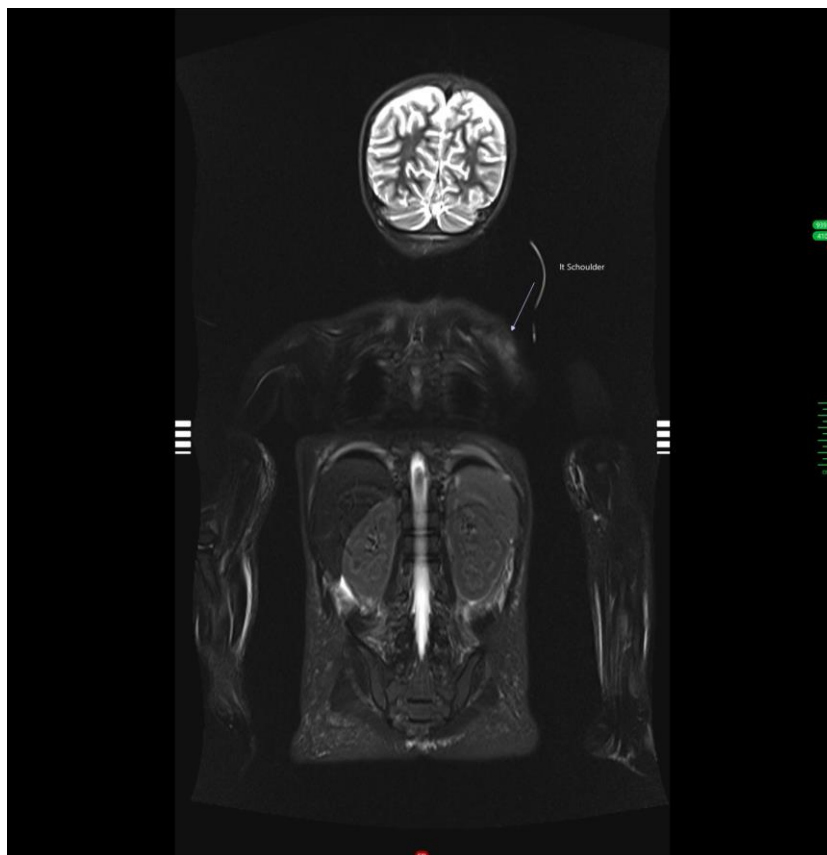


Figure 3: MRI finding: Left shoulder increased muscular signal intensity indicating myositis

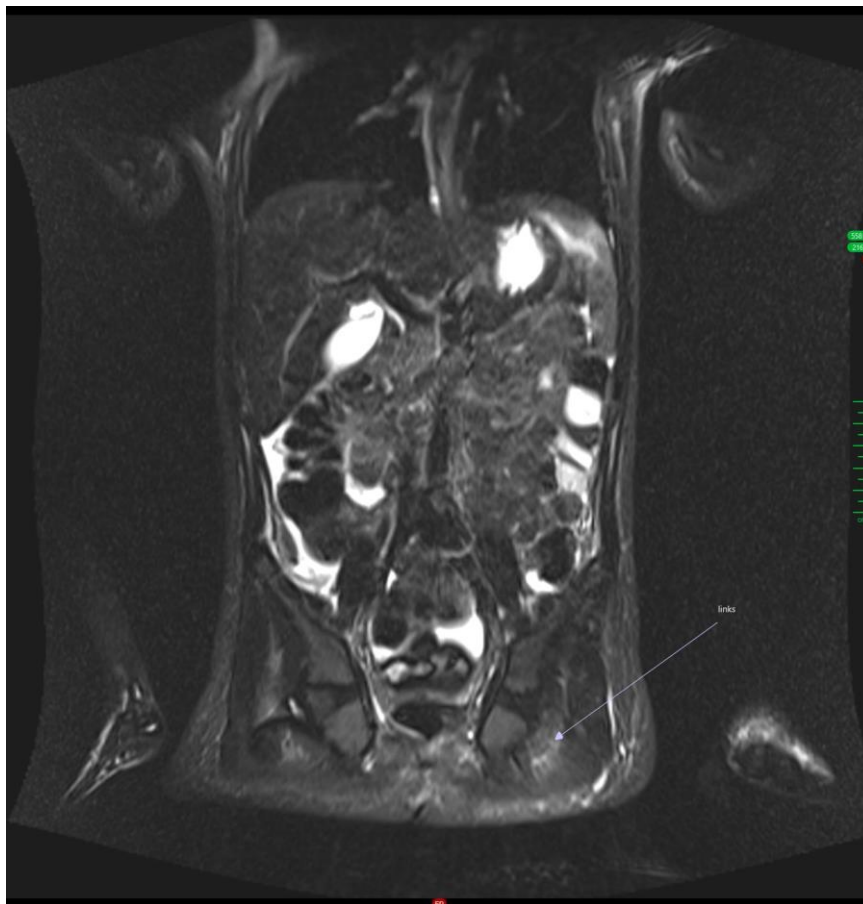


Figure 4: MRI finding: Pelvic muscles increased signal intensity indicating myositis




Figure 5: MRI finding: muscle increased signal indicating myositis

Initial Treatment and Outcome

The patient was treated with intravenous methylprednisolone (20 mg/kg) for three days, followed by oral prednisolone. His condition improved, with reduced swelling and pain, and he regained his ability to walk. After six weeks, he was discharged with instructions for follow-up and continued physiotherapy. On a maintenance dose of prednisone, his muscle power

and pain gradually improved, supported by his mother's adherence to the treatment. Epilepsy remained well-controlled with Valproate.

First Relapse (August 5, 2016)

Six months after stopping prednisolone, the child experienced his first relapse. Symptoms began with fever, stomatitis, leg pain, and reduced mobility. Upon

physical examination, his condition was notably reduced, with salivation, redness in the throat, swollen lips, serous-secreting lesions, a tongue ulcer, and redness in the right elbow with limited mobility. He developed progressive, symmetrical limb weakness, particularly in the proximal aspects of his upper and lower limbs. He struggled with tasks such as combing his hair, climbing stairs, and rising from a squatting position. This weakness was accompanied by muscle and joint pain.

Laboratory investigations revealed:

- Elevated CRP (136), ASL (3200), PCT (0.32), and ESR (80).

- High levels of creatine kinase.
- Normal renal function tests.

Blood culture, CSF analysis, and CSF culture were negative. Chest X-ray, blood smear, ECG, echocardiography, and abdominal ultrasound were unremarkable. An ophthalmologic consultation showed no abnormalities. A Streptococcus throat swab was positive, and he was treated with Penicillin for 14 days, but there was no improvement. MRI of the proximal legs showed increased signal intensity in muscular compartments, indicative of muscle and bone edema. Based on these clinical features, laboratory findings, and MRI results, a diagnosis of JDM relapse was made.

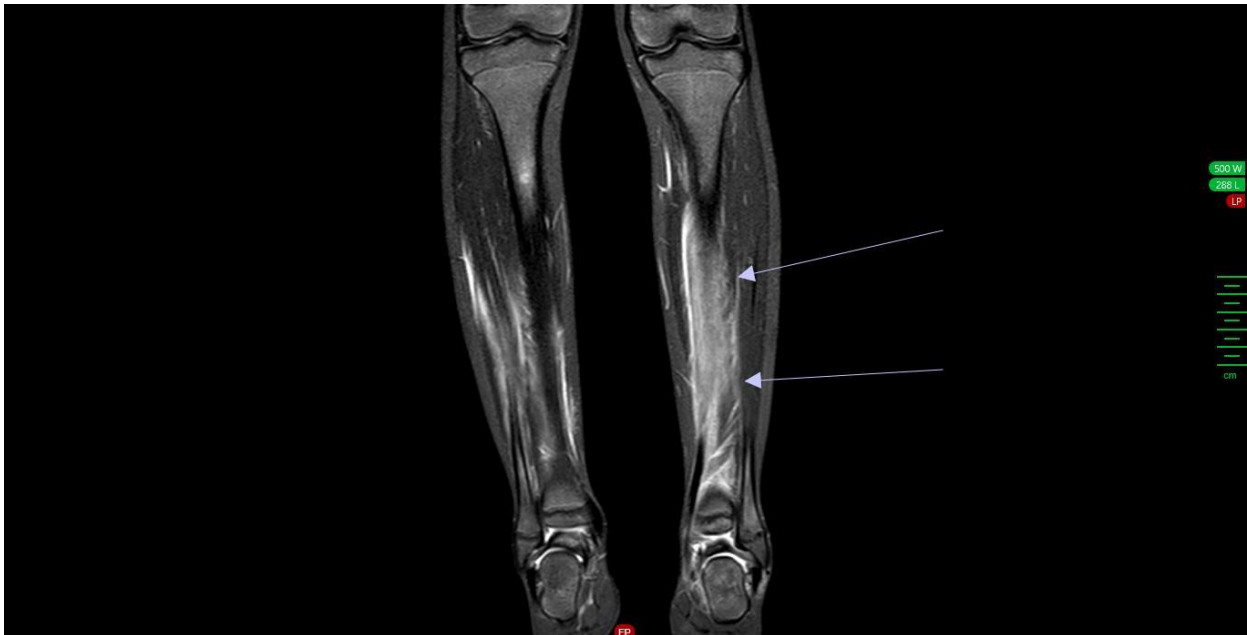

Figure 6: MRI finding: Bone increased signal intensity

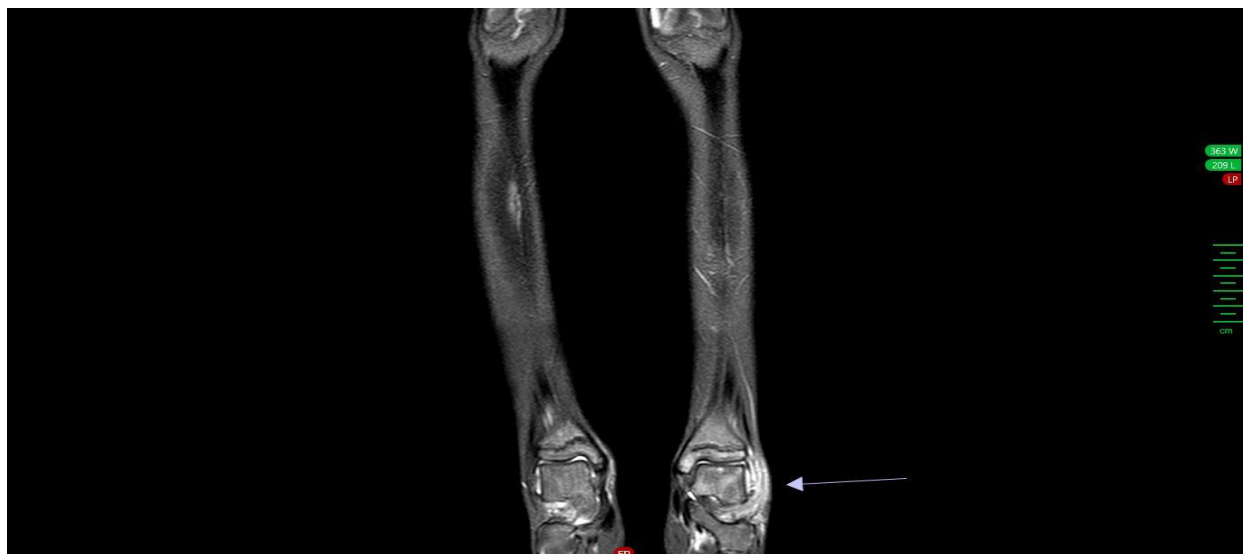


Figure 7: MRI finding: Bone increased signal intensity

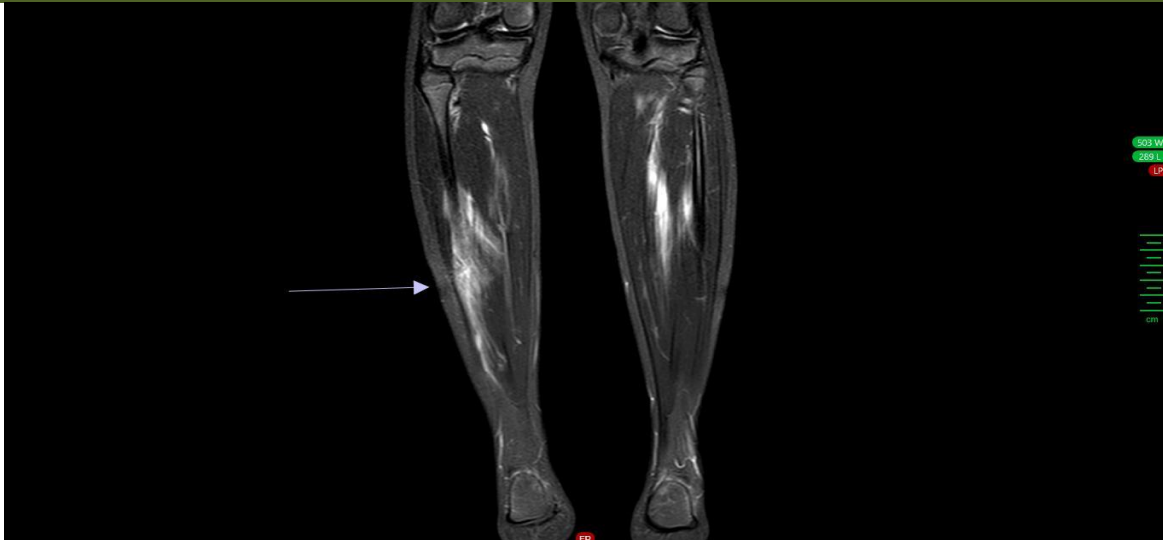

Figure 8: MRI finding: Bone increased signal intensity

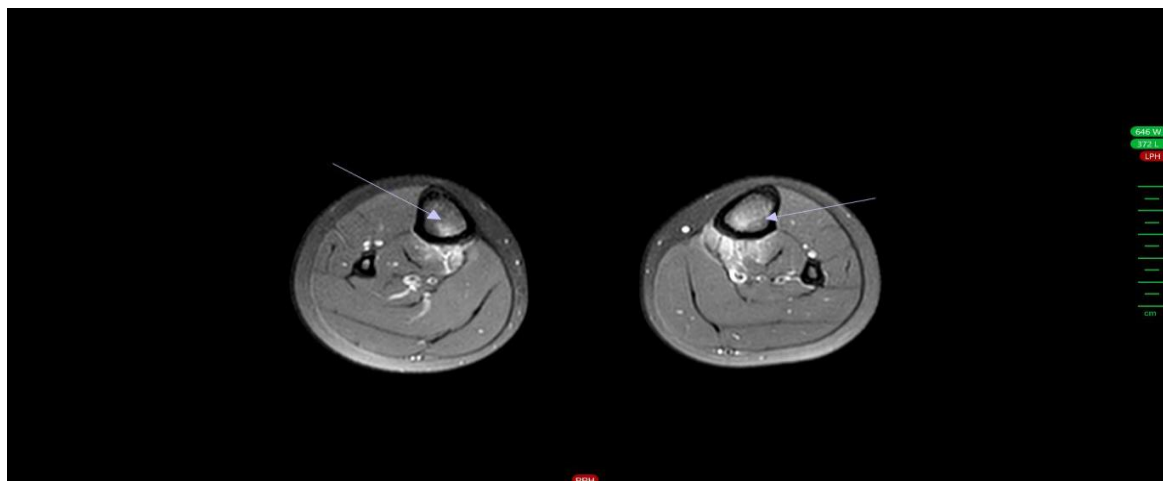


Figure 9: MRI finding: Bone increased signal intensity

The patient underwent treatment with intravenous methylprednisolone (20 mg/kg) for three days, followed by weekly subcutaneous methotrexate (15 mg) and oral folic acid. Despite initial treatments, his condition did not improve. Multiple cycles of intravenous methylprednisolone were administered, but there was still no significant improvement. Consequently, immunoglobulin therapy was started, requiring two doses of IV Ig. A central venous catheter (CVC) was placed, and intensive analgesic therapy,

including an intermittent pain relief pump with piritramide, was used for severe stomatitis. This treatment led to a significant improvement in his general condition, and CK and CRP levels decreased. He was discharged with plans for continued follow-up, treatment, and physiotherapy. Immunoglobulin IV therapy continued until January 2018, and methylprednisolone pulse therapy until December 18, 2018.

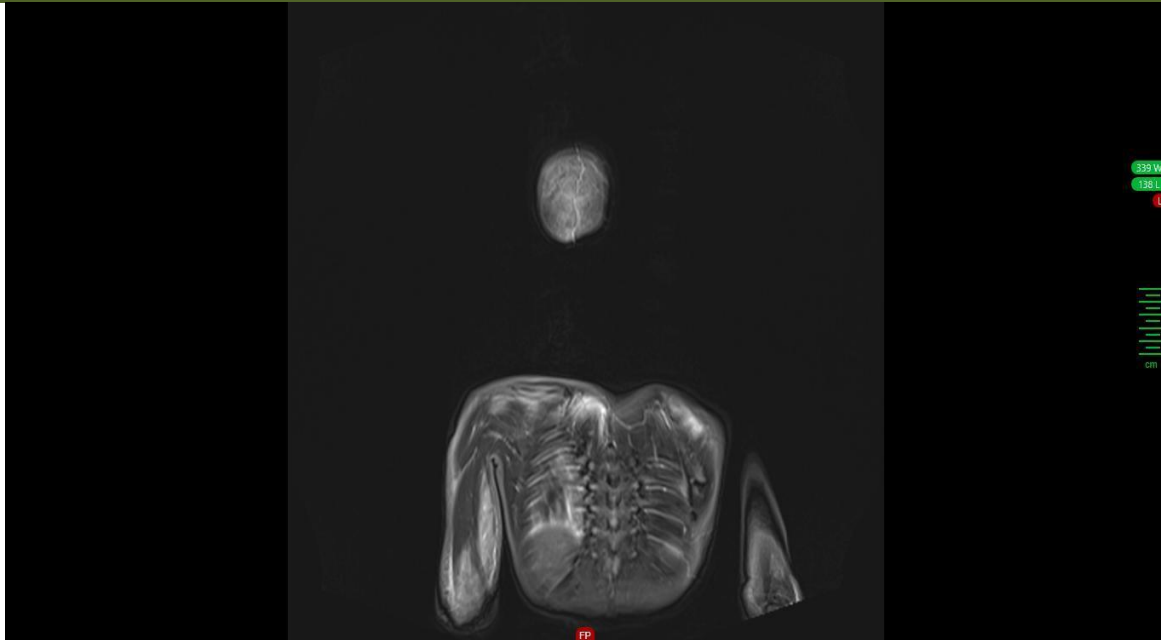


Figure 10: MRI finding. Normal muscle and bone intensity during remission

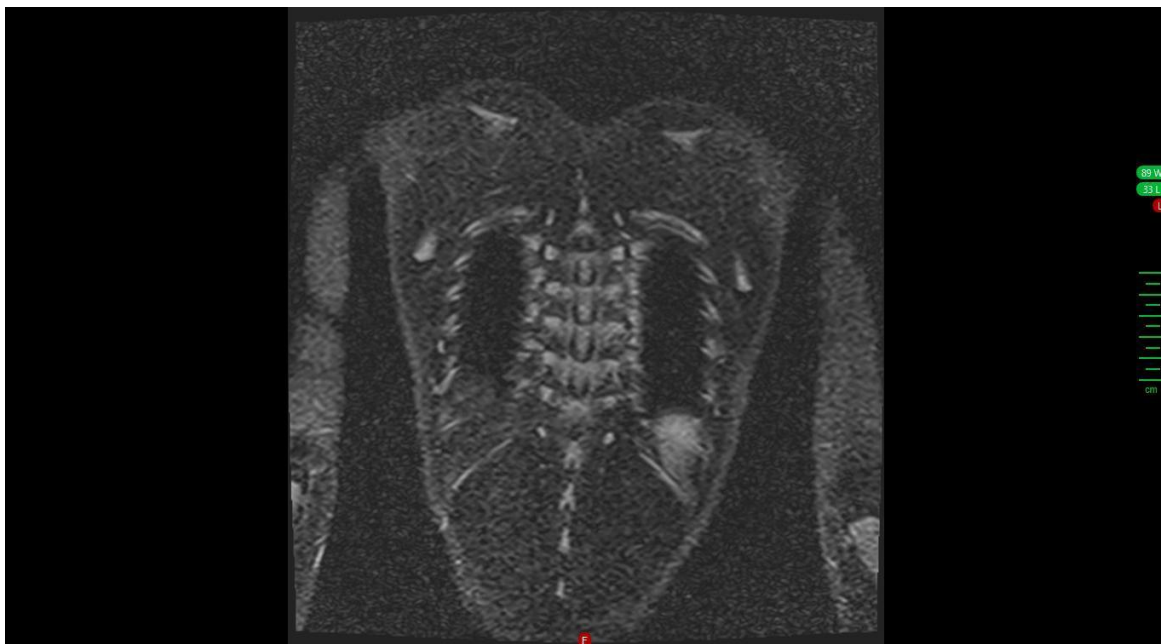

Figure 11: MRI finding: Normal muscle and bone intensity during remission

Methotrexate continued until April 2020. He was maintained on 15 mg methotrexate weekly and 5 mg daily folic acid. His muscle power and pain gradually improved, with good adherence to treatment, supported by his parents, and no adverse effects to the medication course.

Second Relapse (October 23, 2024)

Six months after discontinuing methotrexate, the child experienced a second relapse. Symptoms began with a four-day fever, followed by severe muscle pain in both lower legs, which made walking difficult. Confirmation of JDM was achieved via MRI.

He was treated with intravenous methylprednisolone (20 mg/kg) for three days, followed by weekly subcutaneous methotrexate (15 mg) and oral folic acid, along with daily physiotherapy. Despite these treatments, his condition did not improve, prompting a second opinion from a pediatric myositis expert at the University Medical Center Hamburg. The treatment plan was adjusted to include long-term prednisolone (1.5 mg/kg/day) until muscle strength normalized, immunoglobulins administered biweekly, followed by monthly doses to maintain IgG levels above 20 g/l, Nystatin for antifungal prophylaxis, and calcium and Vitamin D for osteoporosis prevention. The general condition and muscle strength improved under this

treatment. Daily monitoring of the Childhood Myositis Assessment Scale (CMAS) score was recommended at home to guide therapy adjustments.

Given the unusual nature of two relapses in dermatomyositis, the muscle biopsy taken initially was sent for specialized muscle pathology examination at a reference center for neuromuscular disorder. The findings are perivascular accentuated chronic inflammation with eosinophilic component. The inflammatory process extends minimally into the adjacent muscle fibers. Few perivascular muscle necrosis and atrophy are observed. A complete dermatomyositis picture is not present. However, the consulting specialists favor a diagnosis within the spectrum of dermatomyositis related disorders.

During treatment, liver function tests became markedly elevated. Hydroxychloroquine was initiated to stabilize liver function with good response and the route of immunoglobulin administration was switched from IV to subcutaneous (SC) to facilitate monthly therapy at home.

SCIg was initially administered biweekly, then every four weeks, and finally every six weeks for two years. Prednisolone was gradually tapered and continued at a maintenance dose of 2 mg/day. Hydroxychloroquine was discontinued in October 2023 with stable liver function. MRI findings showed gradual improvement.

DISCUSSION

Juvenile Dermatomyositis (JDM) is a rare autoimmune disease that primarily affects children and adolescents. This disease has an incidence of 2-7 cases per million children annually [3]. It manifests in various clinical forms, with Gottron's papules and heliotrope rash being pathognomonic. Calcinosis, which involves the deposition of calcium salts in the skin, subcutaneous tissues, or muscles, and muscle weakness are also common features.

The etiopathogenesis of JDM involves a complex interplay of environmental triggers, immune dysfunction, and specific tissue responses. Both cellular and humoral immune-mediated destruction of the vasculature, skin, and muscles are believed to be involved in its pathogenesis [3].

Diagnosis of JDM involves a combination of clinical evaluation, laboratory tests, imaging studies, and muscle biopsy. JDM is classified into three clinical types according to the post-treatment course [4].

1. **Monocyclic**: One episode with permanent remission within 2 years after diagnosis.
2. **Polycyclic**: Multiple relapses within 2 years.
3. **Continuous**: Pathologic states persisting for more than 2 years.

Treatment with prednisolone is suggested to limit the disorder to the monocyclic course [12]. There are only 2 case reports in the English-language literature where monocyclic JDM recurred more than 3 years after remission [13, 14].

Treatment often includes immunosuppressive therapy, physical therapy, and supportive care.

For newly diagnosed JDM, the combination of prednisone with methotrexate or cyclosporine is more effective than corticosteroid monotherapy. However, the combination of prednisone and methotrexate is recommended as the new standard due to better tolerability and steroid-sparing effects. The rate of adverse effects (skin, subcutaneous tissue, gastrointestinal system) is significantly higher with the prednisone and cyclosporine combination compared to the methotrexate combination [9].

High-dose recombinant human hyaluronidase-facilitated subcutaneous immune globulins (fSCIg) enable the administration of significantly higher doses of immune globulins compared to conventional subcutaneous immune globulin therapy, potentially serving as an alternative to IVIg. However, the safety and efficacy of fSCIg therapy in JDM remain unknown and require further investigation [8].

There are no established methods for predicting the clinical course of JDM. It is usually treated with corticosteroid therapy alone or in combination with immunosuppressive agents such as methotrexate [15]. Early and intensive corticosteroid-based therapy is suggested to lead to a monocyclic course [12]. Although clinical remission was achieved by early intensive treatment with methylprednisolone pulse therapy followed by oral treatment in the initial episode of JDM in our case, the maintenance therapy was discontinued at 6 months to prevent adverse events associated with long-term corticosteroid use. Because the treatment for JDM is usually continued for at least 2 Years [16, 17]. The duration of the initial treatment seems short. However, premature cessation of treatment usually leads to early relapses of JDM. Thus, the short duration of treatment may not have been associated with the relapse 6 months after the initial onset in our patient. The prognosis of late recurrent JDM is not fully understood. Of the 2 previously reported cases, one had been successfully treated with prednisolone monotherapy until the relapse, whereas the other showed spontaneous remission¹⁴. Although the initial episode of JDM was completely cured by short-term corticosteroid-based treatment, additional intensive immunosuppressive therapy SC Immunoglobulin was required to control the prolonged muscle weakness and pain in the relapse. Thus, the late recurrence of monocyclic JDM could be intractable and require attention.

High dose fSCIg is well-tolerated in patients with JDM, achieving high peak serum IgG levels, which are crucial for treatment success. Therefore, high-dose fSCIg could be a viable alternative to high-dose IVIg and warrants further study, as demonstrated in our Patient [8].

CONCLUSION

Juvenile Dermatomyositis (JDM) is a rare pediatric autoimmune disease with a variable course among affected individuals. There is a significant lack of data on optimal management strategies, so treatment decisions are often based on experts' opinions. In Germany, a survey was conducted to analyze current clinical practices to develop consensus-based treatment strategies for JDM [6].

REFERENCES

- Rider, L. G. (2007). The heterogeneity of juvenile myositis. *Autoimmunity reviews*, 6(4), 241-7.
- Feldman, B. M., Rider, L. G., Reed, A. M., & Pachman, L. M. (2008). Juvenile dermatomyositis and other idiopathic inflammatory myopathies of childhood. *The Lancet*, 371(9631), 2201-2212.
- Gupta, P., Shruti, S., Chaudhary, V., Khullar, G., & Siraj, F. (2019). Juvenile dermatomyositis: a case report and review of literature. *Cureus*, 11(1).
- Spencer, C. H., Hanson, V., Singen, B. H., Bernstein, B. H., Kornreich, H. K., & King, K. K. (1984). Course of treated juvenile dermatomyositis. *The Journal of pediatrics*, 105(3), 399-408.
- Kim, H., Huber, A. M., & Kim, S. (2021). Updates on juvenile dermatomyositis from the last decade: classification to outcomes. *Rheumatic Disease Clinics*, 47(4), 669-690.
- Hinze, C. H., Speth, F., Oommen, P. T., & Haas, J. P. (2018). Current management of juvenile dermatomyositis in Germany and Austria: an online survey of pediatric rheumatologists and pediatric neurologists. *Pediatric Rheumatology*, 16, 1-8.
- Kamoun, F., Laroussi, S., Mellouli, A., Jallouli, O., Feki, S., Sassi, S. B., & Triki, C. C. (2023). Juvenile Dermatomyositis Without Skin Lesions in an Antinuclear Matrix Protein 2 Antibody Seropositive Pediatric Case. *Journal of Clinical Neuromuscular Disease*, 25(1), 46-50.
- Speth, F., Haas, J. P., & Hinze, C. H. (2016). Treatment with high-dose recombinant human hyaluronidase-facilitated subcutaneous immune globulins in patients with juvenile dermatomyositis who are intolerant to intravenous immune globulins: a report of 5 cases. *Pediatric Rheumatology*, 14, 1-5.
- Juvenile Dermatomyositis: Standard für Therapie der seltenen Erkrankung gesetzt. *Dtsch Arztebl* 2016; 113(31-32): A-1445 / B-1221 / C-1201
- Bharani, A. T., Harshey, M., Khurana, R., & Raipurkar, S. (2017). A rare case of juvenile dermatomyositis and review of literature. *Indian Journal of Paediatric Dermatology*, 18(2), 107-109.
- Sharma, S., Kadian, P., & Benda, V. (2019). Case report section: paediatrics a rare case report of juvenile dermatomyositis. *Ann Int Med Dent Res*, 6(1), 2395-814.
- Christen-Zacch, S., Seshadri, R., Sundberg, J., Paller, A. S., & Pachman, L. M. (2008). Persistent association of nailfold capillaroscopy changes and skin involvement over thirty-six months with duration of untreated disease in patients with juvenile dermatomyositis. *Arthritis & Rheumatism: Official Journal of the American College of Rheumatology*, 58(2), 571-576.
- Jones, E. M., & Callen, J. P. (1991). Collagen vascular diseases of childhood. *Pediatric Clinics of North America*, 38(4), 1019-1039.
- Martini, A., & Ravelli, A. (1985). Unusual case of childhood dermatomyositis. *Annals of the Rheumatic Diseases*, 44(5), 356.
- Ramanan, A. V., Campbell-Webster, N., Ota, S., Parker, S., Tran, D., Tyrrell, P. N., ... & Feldman, B. M. (2005). The effectiveness of treating juvenile dermatomyositis with methotrexate and aggressively tapered corticosteroids. *Arthritis & Rheumatism*, 52(11), 3570-3578.
- Ruperto, N., Pistorio, A., Oliveira, S., Zulian, F., Cuttica, R., Ravelli, A., ... & Martini, A. (2016). Prednisone versus prednisone plus ciclosporin versus prednisone plus methotrexate in new-onset juvenile dermatomyositis: a randomised trial. *The Lancet*, 387(10019), 671-678.
- Feldman, B. M., Rider, L. G., Reed, A. M., & Pachman, L. M. (2008). Juvenile dermatomyositis and other idiopathic inflammatory myopathies of childhood. *The Lancet*, 371(9631), 2201-2212.