

Recurrent Thrombosis of a Mechanical Heart Valve During Pregnancy: A Case Report

Imad Daoudi^{1*}, Djoudline Doughmi¹, Said Benlamkaddem¹, Adnane Berdai¹, Mustapha Harandou¹¹Medical Doctor, Mother-Child ICU, Hassan II University Hospital, Faculty of Medicine, Pharmacy, and Dental Medicine, Sidi Mohamed Ben Abdellah University, 30 000, Fez, MoroccoDOI: <https://doi.org/10.36347/sjmcr.2025.v13i04.024>

| Received: 11.03.2025 | Accepted: 17.04.2025 | Published: 22.04.2025

*Corresponding author: Imad Daoudi

Medical Doctor, Mother-Child ICU, Hassan II University Hospital, Faculty of Medicine, Pharmacy, and Dental Medicine, Sidi Mohamed Ben Abdellah University, 30 000, Fez, Morocco

Abstract

Case Report

Recurrent thrombosis of mechanical heart valves during pregnancy is a rare but serious complication associated with significant maternal and fetal risks, largely due to the hypercoagulable state induced by pregnancy. Anticoagulation management in this context is particularly challenging, as it requires balancing the prevention of maternal thromboembolic events with minimizing fetal harm. This case report presents a 34-year-old pregnant woman at 33 weeks of gestation with a history of a mechanical mitral valve, recurrent miscarriages, and acute limb ischemia, who was admitted with exertional dyspnoea. Her anticoagulation regimen had been recently changed from Acenocoumarol to weight-adjusted Enoxaparin. She was diagnosed with mitral valve thrombosis and initially treated with unfractionated heparin, followed by surgical valve replacement. Postoperatively, the fetus showed no cardiac activity, leading to an emergency caesarean section. The patient subsequently developed another episode of valve thrombosis, initially managed with fibrinolysis, but ultimately requiring a second valve replacement with a bioprosthetic valve. Further workup identified lupus anticoagulant antibodies, suggestive of antiphospholipid syndrome. This case illustrates the heightened thrombotic risk in pregnancy for patients with mechanical valves, the limitations and complications of various anticoagulation strategies, and the critical need for a personalized, multidisciplinary approach to management. The findings underscore the importance of early recognition, timely intervention, and consideration of underlying prothrombotic disorders in cases of recurrent valve thrombosis during pregnancy.

Keywords: anticoagulation management, bioprosthetic valve replacement, fibrinolysis, lupus, mechanical heart valve, pregnancy complications, recurrent thrombosis, valve thrombosis.

Copyright © 2025 The Author(s): This is an open-access article distributed under the terms of the Creative Commons Attribution 4.0 International License (CC BY-NC 4.0) which permits unrestricted use, distribution, and reproduction in any medium for non-commercial use provided the original author and source are credited.

INTRODUCTION

Recurrent thrombosis of mechanical heart valves during pregnancy presents a significant clinical challenge due to the high risk of maternal and foetal complications. Pregnancy induces a hypercoagulable state, increasing the risk of thromboembolic events in patients with mechanical heart valves (Brenner, 2004; van Hagen *et al.*, 2015). Anticoagulation is crucial, but managing it during pregnancy is complex because of potential risks to the foetus (Steinberg *et al.*, 2017).

Prosthetic heart valve thrombosis (PVT) is uncommon, occurring in 0.1% to 5.7% of patients annually. However, during pregnancy, the procoagulant changes elevate the PVT risk to as high as 10%. Risk factors for valve thrombosis during pregnancy are the same as in nonpregnant women, which are a prosthetic

valve in the mitral position and subtherapeutic anticoagulation (Casais & Rolandi, 2013).

This case report details a pregnant patient with a mechanical heart valve who experienced recurrent thrombosis and had a history of recurrent miscarriages. During our investigations, we suspected antiphospholipid syndrome (APS) as an underlying cause. We also review the current literature on managing similar cases to provide insights into optimal treatment strategies.

CASE REPORT

A 34-year-old woman, gravida 4 para 0, at 33 weeks of gestation, presented to the emergency department with progressive exertional dyspnoea. She had a history of mechanical mitral valve replacement nine years earlier due to rheumatic heart disease, along

with three prior miscarriages and an episode of acute limb ischemia two years earlier related to inadequate anticoagulation, which was managed with surgical embolectomy. One week prior to admission, her cardiologist switched her anticoagulation therapy from Acenocoumarol (a vitamin K antagonist) to weight-adjusted low molecular weight heparin (Enoxaparin, twice daily) in anticipation of delivery.

On examination, she was tachypnoeic at 30 breaths per minute and in atrial fibrillation with a heart

rate of 140 bpm. Blood pressure was stable, and pulmonary auscultation revealed bilateral crackles. She was admitted to the maternal intensive care unit, placed in a semi-sitting position, and started on oxygen therapy. Transthoracic echocardiography revealed a high trans-mitral gradient (maximum 27.89 mmHg, mean 16.44 mmHg), increased peak velocity (2.64 m/s), good left ventricular function, and a dilated left atrium (Figure 1). A transoesophageal echocardiogram confirmed the diagnosis of mechanical mitral valve thrombosis.

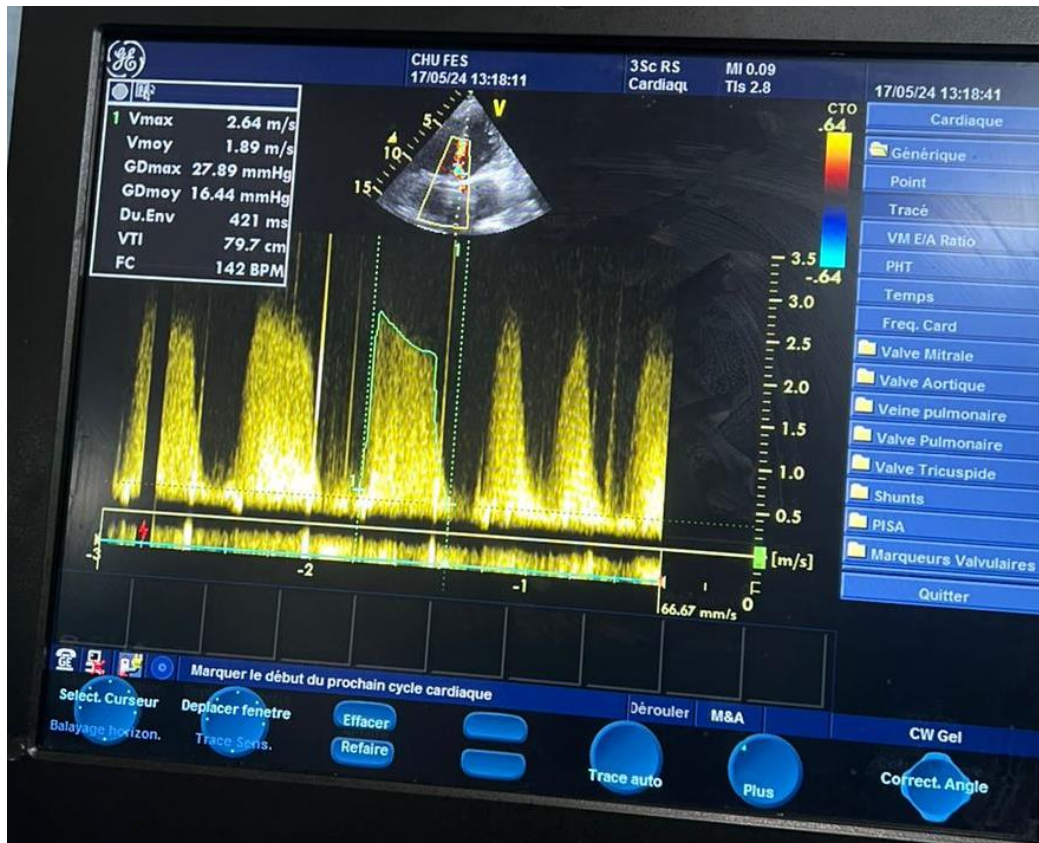

Figure 1: Transthoracic Echocardiography on Admission

The echocardiographic image displays a continuous trans-mitral Doppler flow, indicating an elevated trans-mitral gradient with a peak value of 27.89 mmHg and a mean value of 16.44 mmHg.

A multidisciplinary discussion involving cardiology, cardiac surgery, anesthesiology, and obstetrics led to the decision for urgent surgical valve replacement. Unfractionated heparin (UFH) was initiated, targeting an activated partial thromboplastin time (aPTT) 2–3 times the upper limit of normal. Informed consent was obtained from the patient, with clear explanation of maternal and fetal risks.

Preoperative fetal heart monitoring showed positive cardiac activity.

Under general anesthesia, the patient underwent replacement of the thrombosed valve using cardiopulmonary bypass (CPB) (Figure 2). Anesthetic management was adapted for pregnancy, including bispectral index (BIS) monitoring to minimize anesthetic exposure, maintenance of normothermia, and mean arterial pressure >75 mmHg. CPB flow was maintained between 3 and 3.5 L/min. CPB time was two hours. Postoperative transthoracic echocardiography showed a mean mitral gradient of 7 mmHg with preserved ventricular function. The patient was extubated and resumed on UFH 12 hours later.

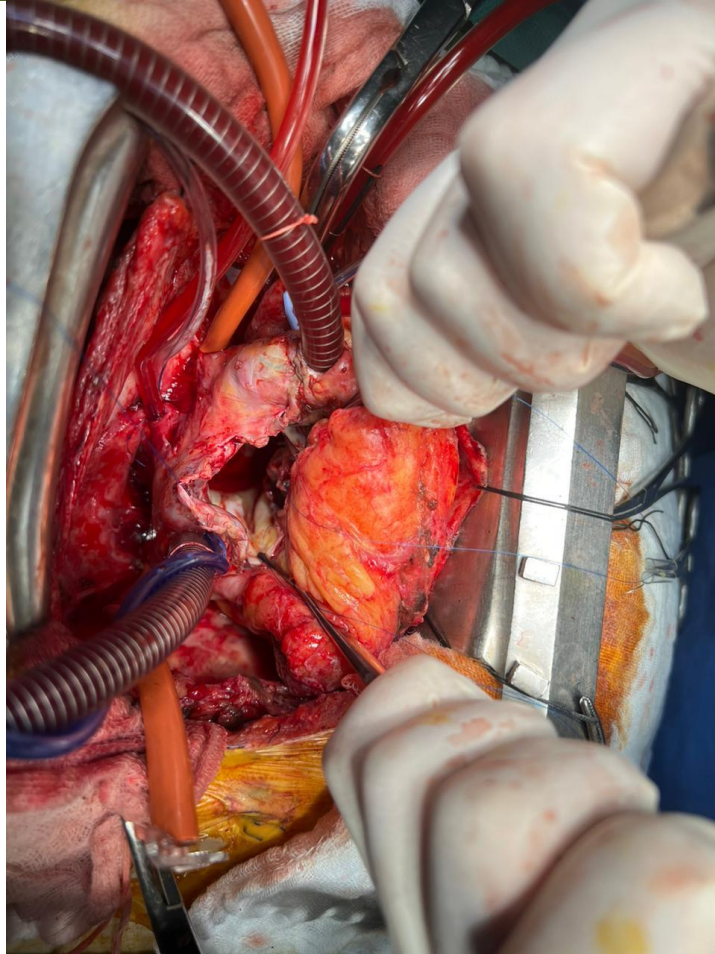


Figure 2: Intraoperative Image During Valve Replacement Surgery

The image captures the first surgical procedure involving the replacement of a thrombosed valve with a new mechanical prosthesis, performed under cardiopulmonary bypass.

On postoperative day 1, fetal ultrasound revealed absence of cardiac activity. A decision was made to perform an emergency cesarean section under general anesthesia after a 4-hour UFH suspension to permit timely re-initiation postoperatively. The surgery was uneventful.

Four days after surgery, the patient developed respiratory deterioration with tachypnoea and desaturation. Lung ultrasound revealed signs of pulmonary congestion. Echocardiography showed a new trans-mitral gradient of 20.87 mmHg, and transoesophageal imaging confirmed recurrent thrombosis of the newly implanted mechanical valve (Figure 3). Thrombolysis with continuous infusion of alteplase was administered (1 mg/h for 25 hours), but no clinical or echocardiographic improvement was observed.

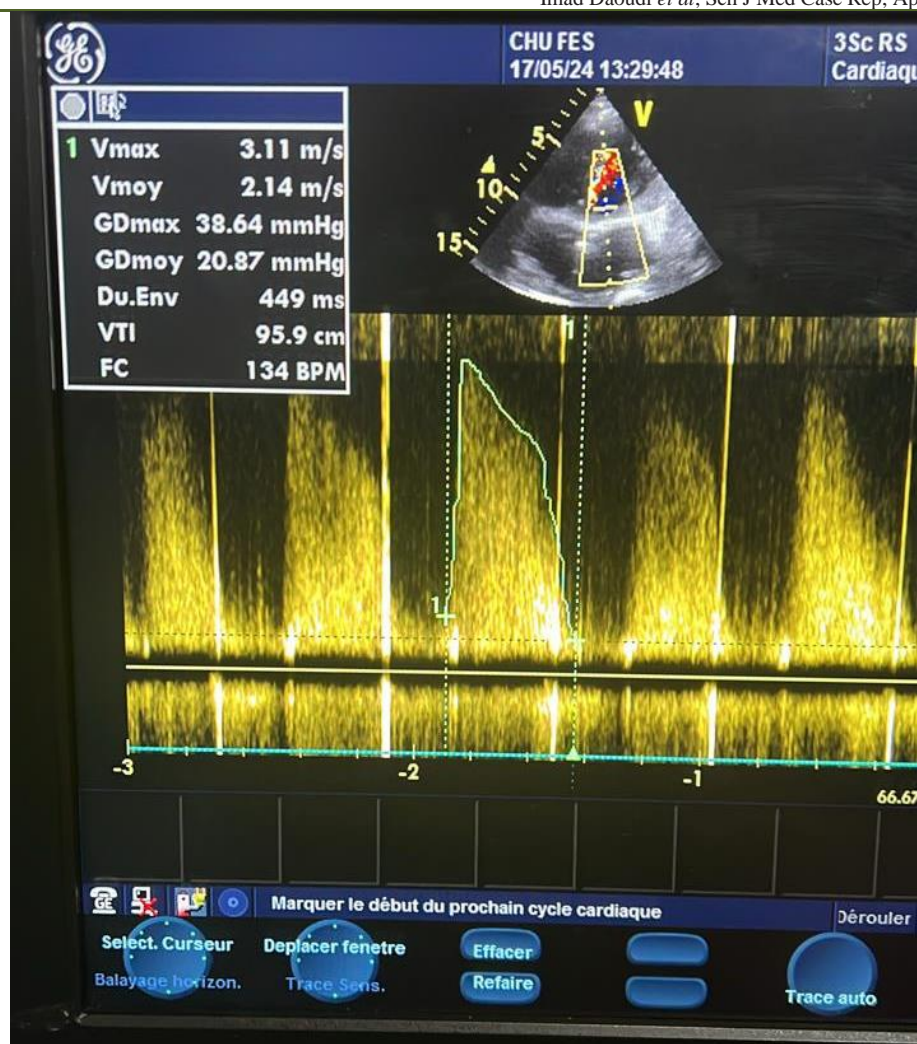


Figure 3: Transthoracic Echocardiography on Postoperative Day 4

The echocardiographic image reveals continuous transmitral Doppler flow with an elevated trans-mitral gradient, showing a peak value of 38.64 mmHg and a mean value of 20.87 mmHg.

A second surgery was performed to replace the mechanical valve with a bioprosthesis. The CPB time was three hours, and postoperative echocardiography showed a mean gradient of 7 mmHg without paravalvular leak. The patient was extubated, resumed on UFH at 12 hours, and transitioned to vitamin K antagonists within 24 hours.

An etiological assessment revealed positive lupus anticoagulant antibodies, indicating antiphospholipid syndrome (APS). The patient was transferred to the internal medicine department for further evaluation and long-term management.

DISCUSSION

This case highlights the complex management of recurrent mechanical heart valve thrombosis during pregnancy, a rare but life-threatening condition. A 34-year-old woman at 33 weeks of gestation was diagnosed

with mitral valve thrombosis shortly after her anticoagulation therapy was switched from Acenocoumarol to Enoxaparin. Despite surgical replacement of the valve and initiation of unfractionated heparin, the patient experienced a second episode of valve thrombosis. Fibrinolytic therapy failed, necessitating a second surgical replacement with a bioprosthesis. Further investigations revealed positive lupus anticoagulant antibodies, suggesting antiphospholipid syndrome (APS) as a contributing factor.

Pregnancy significantly heightens the risk of thromboembolic events in patients with mechanical heart valves due to the hypercoagulable state it induces (van Hagen *et al.*, 2015). Hormonal changes, increased blood volume, and modified hemodynamics collectively contribute to a higher propensity for clot formation (Brenner, 2004). Mechanical valves themselves are inherently thrombogenic, and pregnancy exacerbates this risk, making vigilant anticoagulation management paramount. However, anticoagulation during pregnancy presents a complex challenge because of the potential teratogenic effects of certain anticoagulants and the

increased bleeding risk for both the mother and foetus (Steinberg *et al.*, 2017).

The anticoagulation therapy in pregnant patients is addressed in the Guidelines of the European Society of Cardiology (ESC) 2021 and Guidelines of the American Heart Association/American College of Cardiology (AHA/ACC) 2020 (Otto *et al.*, 2021; Vahanian *et al.*, 2022). The guidelines recommend that women should be switched from vitamin K antagonists (VKA) to low molecular weight heparin (LMWH) at least one week before their planned delivery to minimize bleeding risk. However, maintaining therapeutic levels of LMWH can be challenging, and inadequate anticoagulation increases the risk of valve thrombosis (Xu *et al.*, 2016). In our case, the patient's history of recurrent miscarriages and acute limb ischemia underscores the critical importance of rigorous monitoring and precise adjustment of anticoagulation therapy during pregnancy. Targeting anti-Xa activity levels between 0.8 and 1.2 U/mL (measured 4 to 6 hours post-dose) is essential for effectively managing thrombotic risks and ensuring optimal maternal and fetal outcomes (Otto *et al.*, 2021).

The management of valve thrombosis during pregnancy necessitates a multidisciplinary approach involving cardiologists, cardiac surgeons, anesthesiologists and obstetricians. The primary options for managing thrombosis include surgical intervention or fibrinolysis. Surgical valve replacement, although associated with significant maternal and foetal risks, can be life-saving and may be preferred in cases of severe valve obstruction, as seen in this patient (Otto *et al.*, 2021; Vahanian *et al.*, 2022).

The use of CPB during surgery is particularly risky due to potential hemodynamic instability and adverse effects on the foetus. However, the risk can be minimized with continuous monitoring of the mother, foetus, and uterine tone. Sustained uterine contractions during CPB, particularly during the cooling and rewarming phases, are a leading cause of foetal death. To prevent early labour, tocolytic therapy can be discussed, and post-operative hormonal administration may be considered (Yuan, 2014). Minimizing CPB time is crucial. Hypothermia during CPB can adversely affect placental perfusion through acid-base imbalances, alterations in the coagulation pathway, and sustained uterine contractions. Maintaining normothermia or mild hypothermia ($T > 35^{\circ}\text{C}$) has been shown to improve foetal outcomes. Ensuring adequate pump flow ($> 2.5 \text{ L/min/m}^2$), mean arterial pressure ($> 70 \text{ mmHg}$), and haematocrit levels $> 28\%$ during CPB is recommended for optimal utero-placental perfusion. Despite these precautions, the reported feoto-neonatal mortality remains high, around 20% (Jafferani *et al.*, 2011; Yuan, 2014). In our case, unfortunately, the foetus did not survive.

Fibrinolysis with agents such as alteplase offers a non-surgical alternative, potentially avoiding the immediate risks associated with surgery (Özkan *et al.*, 2015). However, the efficacy of fibrinolysis can be variable, and the risk of bleeding complications remains a significant concern (Karthikeyan *et al.*, 2013). In this case, despite initial fibrinolytic therapy, the persistent high trans-mitral gradient necessitated surgical intervention, ultimately leading to the replacement of the mechanical valve with a bioprosthetic valve. This highlights the complexities and limitations of fibrinolysis in managing valve thrombosis during pregnancy.

Recurrent thrombosis of a mechanical heart valve during pregnancy, while rare, poses a significant clinical challenge. The incidence of PVT in the general population ranges from 0.1% to 5.7% annually, but pregnancy elevates this risk to approximately 10% due to the procoagulant changes inherent in pregnancy (Casais & Rolandi, 2013). The literature on managing recurrent thrombosis specifically during pregnancy is limited, with few case reports addressing this issue (Jimenez *et al.*, 1988; Kalcik *et al.*, 2014; Lisowska *et al.*, 2004; Sathananthan *et al.*, 2019; Vrkcova *et al.*, 2016). Treatment typically involves fibrinolysis or surgical intervention, combined with optimized anticoagulation strategies to prevent future events.

The etiological factors contributing to recurrent thrombosis can include mechanical valve dysfunction, subtherapeutic anticoagulation, and underlying hypercoagulable states such as APS and systemic lupus erythematosus (SLE) (Gencbay *et al.*, 1998). APS, characterized by recurrent thrombotic events and pregnancy morbidity, was suspected in this patient due to her history of recurrent miscarriages and acute limb ischemia (Ruiz-Irastorza *et al.*, 2010). While initial tests for anticardiolipin antibodies were negative, further investigation revealed positive lupus anticoagulant antibodies, suggesting an underlying autoimmune pathology contributing to the thrombotic events.

CONCLUSION

Managing recurrent thrombosis of a mechanical heart valve during pregnancy presents significant clinical challenges, requiring a delicate balance between anticoagulation, fibrinolysis, and surgical intervention. This case illustrates that even with appropriate anticoagulation, patients may suffer severe complications, especially when underlying prothrombotic conditions such as antiphospholipid syndrome are present. The recurrence of thrombosis and need for multiple surgeries highlight the limitations of current protocols and the importance of early recognition and individualized treatment. A thorough etiological workup is essential to guide management decisions, particularly in high-risk patients. Multidisciplinary coordination among cardiologists, cardiac surgeons, anesthesiologists, obstetricians, and internists is critical

to optimize outcomes for both mother and fetus. While both surgical and medical approaches remain valid, each carries significant maternal and fetal risks, reinforcing the need for personalized, risk-adapted strategies. Future research should focus on refining anticoagulation protocols and exploring targeted therapies for patients with underlying autoimmune or hypercoagulable disorders.

Acknowledgements: None.

Conflict of interest

The authors declare that they have no conflict of interest.

Ethics, Informed Consent, and Data Confidentiality Statement

We confirm that oral and written informed consent was obtained from the patient and her relatives for the publication of this clinical case. All clinical data were handled in compliance with confidentiality standards, ensuring that the patient's privacy and personal information remain protected.

REFERENCES

- Brenner, B. (2004). Haemostatic changes in pregnancy. *Thrombosis Research*, 114(5–6), 409–414. <https://doi.org/10.1016/j.thromres.2004.08.004>
- Casais, P., & Rolandi, F. (2013). Prosthetic Valve Thrombosis in Pregnancy. *Circulation*, 128(5), 481–482. <https://doi.org/10.1161/CIRCULATIONAHA.113.004259>
- Gencbay, M., Turan, F., Degertekin, M., Eksi, N., Mutlu, B., & Unalp, A. (1998). High prevalence of hypercoagulable states in patients with recurrent thrombosis of mechanical heart valves. *The Journal of Heart Valve Disease*, 7(6), 601–609.
- Jafferani, A., Malik, A., Khawaja, R. D. A., Sheikh, L., & Sharif, H. (2011). Surgical management of valvular heart diseases in pregnancy. *European Journal of Obstetrics and Gynecology and Reproductive Biology*, 159(1), 91–94. <https://doi.org/10.1016/j.ejogrb.2011.07.032>
- Jimenez, M., Vergnes, C., Brottier, L., Dequeker, J. L., Billes, M. A., Lorient Roudaut, M. F., Choussat, A., & Boisseau, M. R. (1988). [Recurrent thrombosis of an aortic valve prosthesis in a pregnant woman. Treatment with urokinase]. *Journal Des Maladies Vasculaires*, 13(1), 46–49.
- Kalcik, M., Gursoy, M. O., Karakoyun, S., Yesin, M., Astarcioğlu, M. A., & Ozkan, M. (2014). Potential Inherited Causes of Recurrent Prosthetic Mitral Valve Thrombosis in a Pregnant Patient Suffering from Recurrent Miscarriage. *Korean Circulation Journal*, 44(4), 268–270. <https://doi.org/10.4070/kcj.2014.44.4.268>
- Karthikeyan, G., Senguttuvan, N. B., Joseph, J., Devasenapathy, N., Bahl, V. K., & Airan, B. (2013). Urgent surgery compared with fibrinolytic therapy for the treatment of left-sided prosthetic heart valve thrombosis: A systematic review and meta-analysis of observational studies. *European Heart Journal*, 34(21), 1557–1566. <https://doi.org/10.1093/eurheartj/ehs486>
- Lisowska, A., Prokop, J., Hirnle, T., Juszczak, G., Skibińska, E., Musiał, W. J., & Klonowska-Dziatkiewicz, E. (2004). [Recurrent thrombosis of a mitral mechanical heart valve prosthesis during puerperium—A case report]. *Kardiologia Polska*, 61(7), 49–51; discussion 52.
- Otto, C. M., Nishimura, R. A., Bonow, R. O., Carabello, B. A., Erwin, J. P., Gentile, F., Jneid, H., Krieger, E. V., Mack, M., McLeod, C., O’Gara, P. T., Rigolin, V. H., Sundt, T. M., Thompson, A., & Toly, C. (2021). 2020 ACC/AHA Guideline for the Management of Patients With Valvular Heart Disease: Executive Summary: A Report of the American College of Cardiology/American Heart Association Joint Committee on Clinical Practice Guidelines. *Circulation*, 143(5), e35–e71. <https://doi.org/10.1161/CIR.0000000000000932>
- Özkan, M., Gündüz, S., Gürsoy, O. M., Karakoyun, S., Astarcioğlu, M. A., Kalçık, M., Aykan, A. Ç., Çakal, B., Bayram, Z., Oğuz, A. E., Ertürk, E., Yesin, M., Gökdeniz, T., Duran, N. E., Yıldız, M., & Esen, A. M. (2015). Ultraslow thrombolytic therapy: A novel strategy in the management of PROsthetic MEchanical valve Thrombosis and the prEdictors of outcomE: The Ultra-slow PROMETEE trial. *American Heart Journal*, 170(2), 409–418. <https://doi.org/10.1016/j.ahj.2015.04.025>
- Ruiz-Irastorza, G., Crowther, M., Branch, W., & Khamashta, M. A. (2010). Antiphospholipid syndrome. *Lancet (London, England)*, 376(9751), 1498–1509. [https://doi.org/10.1016/S0140-6736\(10\)60709-X](https://doi.org/10.1016/S0140-6736(10)60709-X)
- Sathananthan, G., Johal, N., & Grewal, J. (2019). A case report: Mechanical tricuspid valve thrombosis necessitating cardiac surgery during pregnancy. *European Heart Journal - Case Reports*, 3(2), ytz080. <https://doi.org/10.1093/ehjcr/ytz080>
- Steinberg, Z. L., Dominguez-Islas, C. P., Otto, C. M., Stout, K. K., & Krieger, E. V. (2017). Maternal and Fetal Outcomes of Anticoagulation in Pregnant Women with Mechanical Heart Valves. *Journal of the American College of Cardiology*, 69(22), 2681–2691. <https://doi.org/10.1016/j.jacc.2017.03.605>
- Vahanian, A., Beyersdorf, F., Praz, F., Milojevic, M., Baldus, S., Bauersachs, J., Capodanno, D., Conradi, L., De Bonis, M., De Paulis, R., Delgado, V., Freemantle, N., Gilard, M., Haugaa, K. H., Jeppsson, A., Jüni, P., Pierard, L., Prendergast, B. D., Sádaba, J. R., ... ESC/EACTS Scientific Document Group. (2022). 2021 ESC/EACTS Guidelines for the management of valvular heart disease. *European Heart Journal*, 43(7), 561–632. <https://doi.org/10.1093/eurheartj/ehab395>
- van Hagen, I. M., Roos-Hesselink, J. W., Ruys, T. P. E., Merz, W. M., Golland, S., Gabriel, H.,

- Lelonek, M., Trojnarska, O., Al Mahmeed, W. A., Balint, H. O., Ashour, Z., Baumgartner, H., Boersma, E., Johnson, M. R., Hall, R., & ROPAC Investigators and the EURObservational Research Programme (EORP) Team*. (2015). Pregnancy in Women With a Mechanical Heart Valve: Data of the European Society of Cardiology Registry of Pregnancy and Cardiac Disease (ROPAC). *Circulation*, 132(2), 132–142. <https://doi.org/10.1161/CIRCULATIONAHA.115.015242>
16. Vrkocova, K., Plasek, J., Veiser, T., & Homza, M. (2016). Rare case of a patient with recurrent thrombosis of a mechanical valve during pregnancy. *Cor et Vasa*, 58(4), e451–e456. <https://doi.org/10.1016/j.crvasa.2015.06.002>
17. Xu, Z., Fan, J., Luo, X., Zhang, W.-B., Ma, J., Lin, Y.-B., Ma, S.-H., Chen, X., Wang, Z.-P., Ou, J.-S., & Zhang, X. (2016). Anticoagulation Regimens During Pregnancy in Patients With Mechanical Heart Valves: A Systematic Review and Meta-analysis. *The Canadian Journal of Cardiology*, 32(10), 1248.e1-1248.e9. <https://doi.org/10.1016/j.cjca.2015.11.005>
18. Yuan, S.-M. (2014). Indications for Cardiopulmonary Bypass During Pregnancy and Impact on Fetal Outcomes. *Geburtshilfe Und Frauenheilkunde*, 74(1), 55–62. <https://doi.org/10.1055/s-0033-1350997>