

Colorectal Cancer in Pregnant Women: A Diagnostic and Therapeutic Challenge in an Extremely Rare Situation

Abderrahmane Jallouli^{1*}, Mouna El Bouatmani¹, Nidale Laghfiri¹, Oussama Nacir¹, Fatimaezzahra Lairani¹, Adil Ait Errami¹, Sofia Oubaha², Zouhour Samlani¹, Khadija Krati¹

¹Hepato-gastroenterology Department, University Hospital of Mohammed VI, Marrakesh, Morocco

²Physiology Laboratory, Faculty of Medicine and Pharmacy, Cadi Ayyad University, Marrakesh, Morocco

DOI: <https://doi.org/10.36347/sjmcr.2025.v13i04.040>

| Received: 14.03.2025 | Accepted: 19.04.2025 | Published: 26.04.2025

*Corresponding author: Abderrahmane Jallouli

Hepato-gastroenterology Department, University Hospital of Mohammed VI, Marrakesh, Morocco

Abstract

Case Report

Colorectal cancer (CCR) during pregnancy is a rare condition, with an incidence ranging from 0.0008% to 0.008%. The symptoms of CCR, such as nausea and rectal bleeding, can easily be mistaken for typical pregnancy-related complaints, which delays both diagnosis and treatment. This article reports the case of an invasive rectal cancer diagnosed during an investigation of rectal bleeding in a 37-year-old pregnant woman at 16 weeks of gestation. A multidisciplinary team decided to terminate the pregnancy to allow for optimal cancer management, including surgery and further treatment. The article discusses the challenges in diagnosing and managing colorectal cancer during pregnancy, emphasizing the importance of early detection, imaging, and the need for a multidisciplinary approach to treatment.

Keywords: Colorectal Cancer (CRC), Pregnancy, Diagnosis, Rectal Bleeding, Management.

Copyright © 2025 The Author(s): This is an open-access article distributed under the terms of the Creative Commons Attribution **4.0 International License (CC BY-NC 4.0)** which permits unrestricted use, distribution, and reproduction in any medium for non-commercial use provided the original author and source are credited.

INTRODUCTION

Colorectal cancer (CRC) during pregnancy is extremely rare, with an incidence ranging from 0.0008% to 0.008% [1]. It presents a significant diagnostic and therapeutic challenge. Patients may confuse colorectal cancer symptoms, such as nausea and rectal bleeding, with symptoms of pregnancy, which can delay diagnosis and treatment [2, 3]. This report presents a case of invasive rectal cancer revealed during an investigation of rectal bleeding in a pregnant woman.

CASE

A 37-year-old patient, mother of four children, 16 weeks pregnant, with no significant medical history, presents with intermittent and mild rectal bleeding, evolving for three months. This rectal bleeding is associated with rectal syndrome, including tenesmus, false urges, and intermittent mild to moderate rectal pain, worsened by defecation. No other symptoms were reported. The clinical course occurred in a stable hemodynamic context, but a gradual deterioration of the general condition was noted, resulting in a weight loss of 15 kilograms, suggesting associated malnutrition.

Clinical examination revealed, during rectal palpation, a bulging tumor located approximately 3.5 cm

from the anal margin, affecting the anterior wall of the rectum. A rectosigmoidoscopy revealed an ulcerated, bulging, hemorrhagic process with central necrosis areas, extending over approximately 6 cm from 4 cm from the anal margin (Figure 1). Several biopsies were taken, and histological examination revealed a rectal adenocarcinoma, developed from a tubular adenoma with high-grade dysplasia. A subsequent total colonoscopy showed no synchronous lesions in the entire colonic framework.

Pelvic magnetic resonance imaging (MRI) revealed a large tumor localized in the lower and middle rectum, with infiltration of adjacent tissues, including the posterior vaginal wall. This tumor mass was associated with mesorectal and locoregional lymphadenopathy. The MRI classified the tumor as T4bN2bMx, indicating extensive local invasion and significant lymphadenopathy (Figure 2).

The patient's case was discussed during a multidisciplinary team meeting (RCP) including hepatogastroenterologists, surgeons, gynecologists, oncologists, and radiotherapists. The committee decided to opt for a therapeutic abortion (TA) to allow optimal tumor management due to the need for aggressive treatment and the advanced stage of the disease.

Citation: Abderrahmane Jallouli, Mouna El Bouatmani, Nidale Laghfiri, Oussama Nacir, Fatimaezzahra Lairani, Adil Ait Errami, Sofia Oubaha, Zouhour Samlani, Khadija Krati. Colorectal Cancer in Pregnant Women: A Diagnostic and Therapeutic Challenge in an Extremely Rare Situation. Sch J Med Case Rep, 2025 Apr 13(4): 740-742.

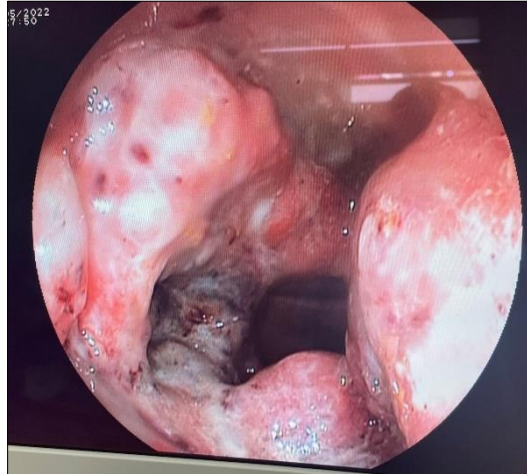


Figure 1: Rectosigmoidoscopy revealing an ulcerated and hemorrhagic process with central necrosis areas, extending over approximately 6 cm from 4 cm from the anal margin

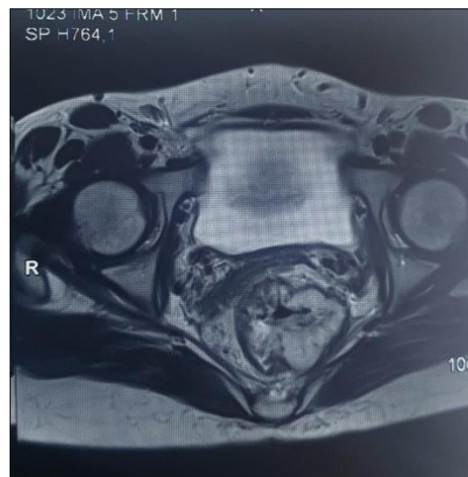


Figure 2: pelvic MRI showing a large tumor localized in the lower and middle rectum, with infiltration of adjacent tissues

DISCUSSION

Colorectal cancer (CRC) during pregnancy is a rare condition [4, 5]. According to available data, the median age of patients diagnosed with CRC during pregnancy is 31 years, with a range of 16 to 48 years [6]. Tumors are mostly localized in the rectum or sigmoid colon, and diagnosis is often made at an advanced stage. Specifically, 60% of cases are classified as stage C or higher according to Dukes' classification [7].

The exact causes of CRC during pregnancy are poorly understood, although around 23% of patients have a family history of the disease. Identified risk factors include Lynch syndrome, familial adenomatous polyposis, Gardner syndrome, Peutz-Jeghers syndrome, and chronic inflammatory bowel diseases. However, these factors concern only a minority of cases [8].

Clinically, common symptoms of CRC during pregnancy include nausea, vomiting, abdominal pain, constipation, anemia, and rectal bleeding [9]. However,

these symptoms can be confused with the normal physiological changes related to pregnancy.

One of the main challenges lies in differentiating between pregnancy-related symptoms and those caused by a tumor. A thorough clinical evaluation of abdominal pain, along with a detailed physical examination, is essential. When an abdominal or rectal mass is suspected, further examinations should be performed. Among the available tools, ultrasound, MRI, and rectosigmoidoscopy are considered safe for the fetus [10]. Colonoscopy with biopsy remains the gold standard for diagnosis.

Regarding therapeutic management, when CRC is diagnosed before 20 weeks of pregnancy, delaying treatment can lead to tumor progression, putting the mother's life at risk. Thus, abortion is often recommended to allow for prompt surgical intervention [11].

CONCLUSION

Colorectal cancer in pregnant women remains a rare yet complex condition, both diagnostically and therapeutically. Delayed diagnosis is frequent due to the similarity of symptoms to those of pregnancy, which requires heightened vigilance from healthcare professionals. The case presented in this article illustrates the difficulty in making an early diagnosis, as symptoms are often interpreted as normal manifestations of pregnancy. However, imaging and colonoscopy can confirm the diagnosis. In terms of management, therapeutic abortion may sometimes be necessary to optimize tumor treatment, especially when diagnosed at an advanced stage. The challenges also include the need to reconcile oncological treatments with the preservation of maternal and fetal health, justifying a multidisciplinary approach in managing these patients. Although treatments remain challenging and prognosis is often poor, early detection and appropriate intervention can improve the mother's chances of survival.

Funding: The author(s) received no financial support for the research, authorship, and/or publication of this article.

Declaration of Conflicting Interests: The author(s) declared no potential conflicts of interest with respect to the research, authorship, and/or publication of this article.

Consent to Publication:

The patients had declared their consent freely and in an informed manner, in order to allow the production and publication of this manuscript.

Ethical Approval: Ethical approval is not required at our institution to publish an anonymous case report.

REFERENCES

1. Chan YM, *et al.*, Colorectal Cancer during Pregnancy: A Clinical Challenge. *J Clin Oncol.* 2019;37(12):1025-1032.
2. Smith D, *et al.*, Challenges in Diagnosing Colorectal Cancer in Pregnant Women. *Cancer Res.* 2021;81(5):2201-2210.
3. American College of Radiology. Guidelines for Imaging in Pregnancy. ACR Practice Parameters, 2020.
4. World Health Organization (WHO). Guidelines on Cancer Management during Pregnancy. WHO Publications, 2021.
5. National Cancer Institute. Colorectal Cancer and Pregnancy: Incidence and Management. *NCI Bull.* 2022.
6. European Society of Gastroenterology. Recommendations for Gastrointestinal Cancer Management in Pregnancy. ESG Consensus Report, 2020.
7. Dukes CE, *et al.*, Revised Dukes Classification of Colorectal Cancer Staging. *Ann Surg Oncol.* 2018;25(3):765-775.
8. Oncology Reviews. Risk Factors and Genetic Predisposition in Colorectal Cancer. *Oncol Rev.* 2019;43(4):312-325.
9. Journal of Obstetrics and Gynaecology. Management of Cancer during Pregnancy: Obstetric and Oncologic Considerations. *J Obstet Gynaecol.* 2020;40(6):892-904.
10. International Journal of Radiation Oncology. Radiotherapy Considerations in Pregnant Patients with Pelvic Tumors. *Int J Radiat Oncol Biol Phys.* 2021;110(8):2145-2152.
11. Chan YM, *et al.*, Survival Rates and Prognostic Factors in Pregnant Women Diagnosed with Colorectal Cancer. *J Clin Oncol.* 2019;37(18):1347-1355.