

Red Nose, Deeper Cause: Lupus Pernio as A Sentinel Sign of Systemic Sarcoidosis

Rasha Moumna^{1*}, Zakia Douhi¹, Hanane Baybay¹, Sara Elloudi¹, Meryem Soughi¹, Fatima Zahra Mernissi¹

¹Dermatology Department, Hassan II University Hospital, Fez, Morocco

DOI: <https://doi.org/10.36347/sjmcr.2025.v13i05.070> | Received: 03.04.2025 | Accepted: 08.05.2025 | Published: 20.05.2025

*Corresponding author: Rasha Moumna

Dermatology Department, Hassan II University Hospital, Fez, Morocco

Abstract

Case Report

Lupus pernio (LP) is a rare but distinctive manifestation of cutaneous sarcoidosis, often reflecting systemic involvement, particularly of the upper respiratory tract. We report the case of a 53-year-old woman presenting with an asymptomatic violaceous plaque on the nose evolving over eight months, associated with nasopharyngeal symptoms. Imaging revealed a pseudotumoral thickening of the posterior nasopharyngeal wall, and biopsies confirmed the diagnosis of sarcoidosis with concurrent cutaneous and nasopharyngeal involvement. Further systemic workup revealed additional salivary gland and lymph node involvement. Treatment with systemic and topical corticosteroids combined with hydroxychloroquine led to significant clinical improvement. This case underscores the importance of recognizing LP as a sentinel sign of systemic sarcoidosis and highlights the need for early diagnosis, multidisciplinary evaluation, and appropriate therapy to prevent aesthetic sequelae and systemic progression.

Keywords: Lupus pernio; Sarcoidosis; Nasopharyngeal involvement; Cutaneous sarcoidosis; Dermoscopy; Case report.

Copyright © 2025 The Author(s): This is an open-access article distributed under the terms of the Creative Commons Attribution 4.0 International License (CC BY-NC 4.0) which permits unrestricted use, distribution, and reproduction in any medium for non-commercial use provided the original author and source are credited.

INTRODUCTION

Sarcoidosis is a multisystem granulomatous disease that can affect various organs, most commonly the lungs, lymphatic system, and skin. Cutaneous manifestations are highly polymorphic, ranging from nonspecific lesions such as erythema nodosum to more specific presentations. Lupus pernio (LP) is a rare but distinctive form of cutaneous sarcoidosis, typically reflecting a chronic or advanced stage of the disease. It is frequently associated with upper airway involvement, particularly affecting the nasal mucosa and sinuses [2]. This association underscores the importance of early recognition of LP, as it often signals broader systemic involvement [1].

We present a case of LP that served as a sentinel finding leading to the diagnosis of systemic sarcoidosis with nasopharyngeal involvement. We also discuss the differential diagnoses of LP, the contribution of dermoscopy, and the therapeutic implications.

CASE REPORT

A 53-year-old woman presented to our dermatology department with an asymptomatic nasal lesion evolving over the past eight months, more recently associated with nasopharyngeal symptoms, including unilateral nasal obstruction, hoarseness, and intermittent epistaxis. By the time of her consultation, the patient had already been evaluated by the ENT specialists and was scheduled for a nasopharyngeal biopsy following the discovery of a pseudotumoral thickening of the posterior nasopharyngeal wall on craniofacial CT scan.

On dermatologic examination, the patient exhibited a 6 cm infiltrated, scaly, violaceous, and telangiectatic plaque on the nose, associated with a rounded, firm, orangy-red papule under the columella (Figure 1). No ulcerations or perforations were observed on the visible nasal mucosa.

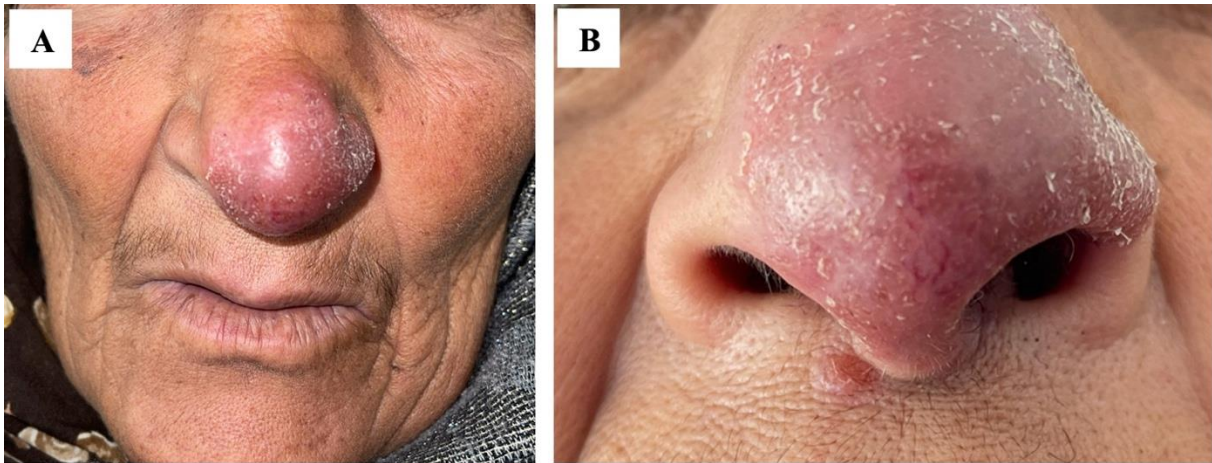


Figure 1: Clinical findings on admission showing a violaceous infiltrated plaque on the nose (A) and an orange-red infra-columellar papule (B)

Dermoscopy of the nasal plaque revealed a red-orange background associated with shiny white streaks (chrysalis structures), rosettes, follicular plugs, and telangiectasia. Dermoscopic examination with pressure applied to the infra-columellar papule revealed a

homogeneous yellow-orange globular pattern surrounded by telangiectasia (Figure 2). This lupoid aspect was highly suggestive of a granulomatous etiology.

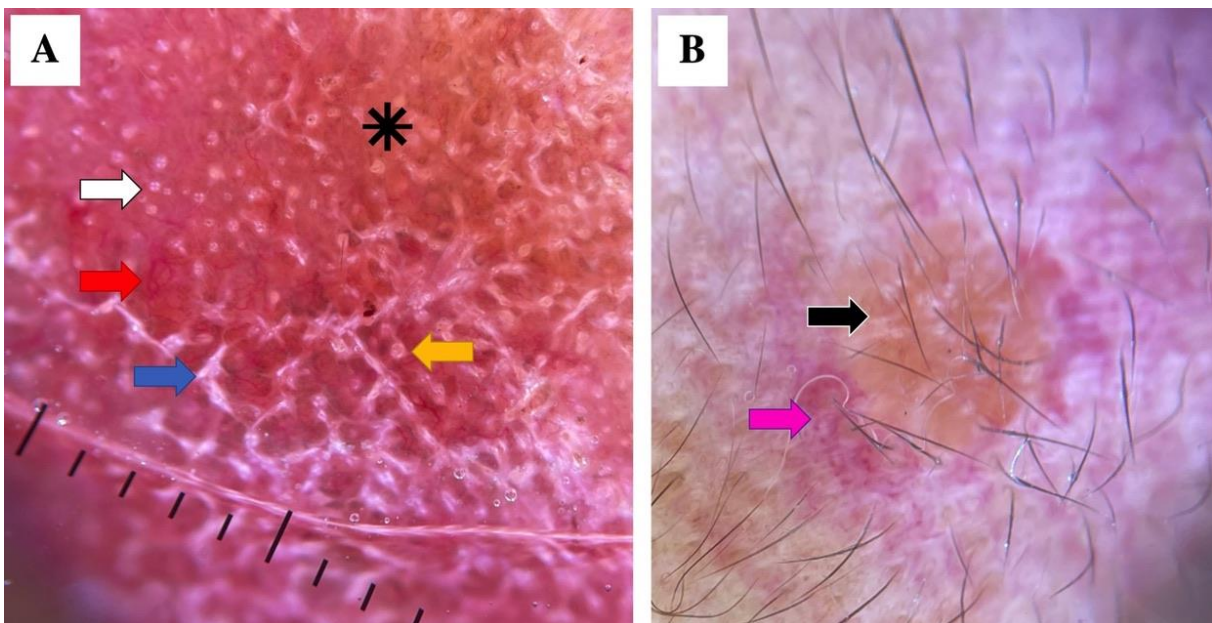


Figure 2: Dermoscopy of the nasal lesion (A) showing a red-orange background (black asterisk), shiny white streaks (blue arrow), rosettes (white arrow), follicular plugs (yellow arrow), and telangiectasia (red arrow). Dermoscopy of the infra-columellar papule (B) showing a homogeneous yellow-orange globular pattern (black arrow) surrounded by telangiectasia (pink arrow)

Routine laboratory investigations were unremarkable, apart from an elevation of angiotensin-converting enzyme levels. Specific infectious workups for tuberculosis (tuberculin skin test and interferon-gamma release assay) and leishmaniasis (skin smear) were negative.

Histopathological examination of both the skin and nasopharyngeal biopsies revealed numerous non-caseating epithelioid cell granulomas with Langhans giant cells and sparse lymphocytic infiltrate, without

evidence of necrosis. These findings confirmed the diagnosis of sarcoidosis, consistent with lupus pernio associated with nasopharyngeal involvement.

A further systemic evaluation was performed to assess disease extent. Chest radiography, pulmonary function tests (PFTs), ophthalmologic evaluation, and cardiac evaluation were normal. However, full-body imaging (CT scan and ultrasound) revealed multiple lymphadenopathies involving mediastinal, lumbo-aortic, and external iliac lymph nodes. Additionally, minor

salivary gland biopsy demonstrated non-caseating granulomas with mild surrounding lymphocytic infiltration and no evidence of infection.

The patient was initiated on high-potency topical corticosteroids applied to the nasal lesions, combined with oral hydroxychloroquine and low-dose prednisone. After four weeks, the lesions showed a marked reduction in induration and erythema, and no new lesions developed. Therefore, a progressive tapering of topical corticosteroids was initiated while systemic therapy was maintained. The patient continues to be monitored in collaboration with the Ear, Nose, and Throat (ENT) team for ongoing management of her upper airway sarcoidosis.

DISCUSSION

Lupus pernio (LP) was first described by Besnier in the late 19th century as a distinctive form of cutaneous sarcoidosis [2]. It is now recognized as a manifestation of chronic sarcoidosis, typically appearing at an advanced stage of the disease after years of silent progression. LP is also considered a predictive marker of systemic sarcoidosis, frequently correlating with thoracic involvement (e.g., lung and mediastinal lymph nodes) as well as extrathoracic involvement [3]. Importantly, the upper respiratory tract is reported to be the most commonly affected site in patients with LP [1], as exemplified in our case. Given this strong association, it is recommended that all patients presenting with LP undergo evaluation of the upper respiratory tract in collaboration with ENT specialists [4]. Early detection of sinonasal or nasopharyngeal sarcoidosis can guide appropriate therapy and prevent complications such as respiratory obstruction or tissue destruction.

Epidemiologically, LP tends to occur more frequently in middle-aged adults, with a predilection for females and individuals of African descent. Clinically, it usually presents as bluish-red or violaceous indurated plaques or nodules on the face, typically affecting the nose (alae, tip, and septum) and perinasal skin. These lesions can be disfiguring and may lead to complications such as nasal ulceration and even septal perforation in longstanding cases [2]. Less commonly, LP lesions may involve the cheeks, ears, lips (perioral area), and, exceptionally, the fingers and toes [4].

Dermoscopy has emerged as a helpful tool in the evaluation of cutaneous sarcoidosis. The most commonly described dermoscopic features of LP and other sarcoid lesions are translucent yellow to orange globules or structureless areas, corresponding to the granulomas in the dermis, accompanied by linear and branching vessels and sometimes shiny white streaks indicating fibrosis [5]. These dermoscopic findings, while not pathognomonic, support the clinical suspicion of granulomatous disease and can help distinguish sarcoidosis from other entities in the differential diagnosis.

Lupus pernio presents a diagnostic challenge due to its clinical polymorphism. The differential diagnosis of facial granulomatous lesions includes inflammatory diseases such as granulomatosis with polyangiitis, lupus vulgaris, and lupus tumidus, as well as neoplastic conditions like extranodal NK/T-cell lymphoma. Infectious etiologies such as leishmaniasis, syphilitic gummas, tuberculoid leprosy, and deep fungal infections must also be ruled out. Clinicopathological correlation is essential for a definitive diagnosis [2,4].

Histologically, LP is characterized by “naked” non-caseating granulomas composed of epithelioid cells and Langhans giant cells, sometimes containing asteroid or Schaumann bodies. The absence of central caseation helps differentiate sarcoidosis from infections. In our patient, biopsies showed numerous non-caseating granulomas with minimal inflammation, confirming sarcoidosis and ruling out infectious or neoplastic causes [2].

Management of LP is often difficult due to its chronic course and resistance to therapy. Topical corticosteroids, intralesional corticosteroids, and topical calcineurin inhibitors may provide partial improvement, but systemic therapy is frequently necessary. Oral corticosteroids remain the first-line treatment for extensive disease, often combined with steroid-sparing agents such as hydroxychloroquine, as used in our case.

In refractory or severe cases, immunomodulatory agents such as methotrexate, thalidomide, and minocycline can be considered. Biologic therapies, particularly TNF- α inhibitors like infliximab and adalimumab, have shown efficacy in resistant forms. Emerging treatments, including JAK inhibitors, have also shown promising results.

Effective management requires a multidisciplinary approach involving dermatologists, pulmonologists, and ENT specialists. Long-term follow-up is essential given the risk of recurrence and systemic progression [4].

CONCLUSION

Lupus pernio is a rare but important manifestation of sarcoidosis. Beyond causing skin lesions that can be both disfiguring and psychologically distressing, it frequently signals underlying systemic involvement, particularly of the respiratory tract. This case underscores the importance of recognizing the characteristic features of LP and conducting a thorough evaluation for systemic disease, including nasopharyngeal involvement. Early diagnosis of sarcoidosis enables timely initiation of therapy, which may prevent permanent scarring and systemic complications. Optimal management of lupus pernio requires a combination of local and systemic therapies, integrated within a multidisciplinary care approach.

Close collaboration between dermatologists and other specialists offers patients the best chance of achieving disease control while preserving both function and appearance.

Acknowledgements: The authors thank the Department of Otorhinolaryngology for their collaboration in the diagnosis and management of this patient's condition.

REFERENCES

1. James, D. G. (1992). Lupus pernio. *Lupus*, 1(3), 129–131. <https://doi.org/10.1177/096120339200100302>
2. Mañá, J., Marcoval, J., Graells, J., Salazar, A., Peyrí, J., & Pujol, R. (1997). Cutaneous involvement in sarcoidosis: relationship to systemic disease. *Archives of dermatology*, 133(7), 882-888. <https://doi.org/10.1001/archderm.1997.03890430098013>
3. Rottoli, P., Bargagli, E., Chidichimo, C., Nuti, D., Cintonino, M., Ginanneschi, C., & Caruso, G. (2006). Sarcoidosis with upper respiratory tract involvement. *Respiratory medicine*, 100(2), 253-257. <https://doi.org/10.1016/j.rmed.2005.04.018>
4. Condé, K., Guelngar, C. O., Mohamed, A., Adjibaye, E., & Cissé, F. A. (2021). Lupus pernio in chronic sarcoidosis. *Cureus*, 13(9), e18376. <https://doi.org/10.7759/cureus.18331>
5. Loo Lim, A. Y., Tang, P. Y., & Oh, C. C. (2021). Dermoscopy in cutaneous sarcoidosis. *Dermatology Online Journal*, 27(9), 13030. <https://doi.org/10.5070/D327955144>