

Endometrial Tuberculosis in a Postmenopausal Woman: A Rare Entity with Radiologic Implications

M. El Khalifa^{1*}, S. Ouassil¹, Choukri Ahmmanna¹, B. Zouita¹, D. Basraoui¹, H. Jalal¹

¹Department of Radiology, Mother and child hospital, Mohamed VI University Hospital, Cadi Ayyad University, Marrakech, Morocco

DOI: <https://doi.org/10.36347/sjmcr.2025.v13i06.004>

| Received: 24.04.2025 | Accepted: 27.05.2025 | Published: 03.06.2025

*Corresponding author: M. El Khalifa

Department of Radiology, Mother and child hospital, Mohamed VI University Hospital, Cadi Ayyad University, Marrakech, Morocco

Abstract

Case Report

Endometrial tuberculosis (ETB) is a rare form of genital tuberculosis, typically affecting women of reproductive age. Its occurrence in postmenopausal women is extremely uncommon and often mimics endometrial malignancy due to non-specific clinical and imaging features. We report a case of ETB in a 72 year-old woman presenting with postmenopausal bleeding, in which imaging played a key role in raising suspicion and guiding further management. This case highlights the importance of including ETB in the differential diagnosis of abnormal endometrial findings in postmenopausal women, especially in tuberculosis endemic regions.

Keywords: Endometrial Tuberculosis, Postmenopausal Woman, MRI.

Copyright © 2025 The Author(s): This is an open-access article distributed under the terms of the Creative Commons Attribution **4.0 International License (CC BY-NC 4.0)** which permits unrestricted use, distribution, and reproduction in any medium for non-commercial use provided the original author and source are credited.

INTRODUCTION

Genital tuberculosis accounts for 9–20% of extrapulmonary TB cases in women, with predominant involvement of the fallopian tubes and endometrium. Endometrial involvement is rare in postmenopausal women due to endometrial atrophy, low vascularity, and hormonal inactivity. However, in areas with high TB prevalence or in patients with a prior TB history, this diagnosis should not be overlooked. Imaging findings can overlap with malignancy, thus posing a diagnostic challenge. Radiologic evaluation, particularly MRI, plays a crucial role in early detection and differentiation.

CASE REPORT

A 72-year-old woman, gravida 4 para 4, presented with intermittent postmenopausal bleeding for

two months. She had no history of hormone replacement therapy or known malignancy. Past medical history revealed successfully treated pulmonary tuberculosis 20 years earlier. Gynecologic examination revealed a slightly enlarged uterus. . MRI of the pelvis showed a heterogeneously hypointense endometrium on T2-weighted imaging, and mild enhancement post-contrast. No myometrial invasion was observed.

An endometrial biopsy was performed, and histopathology revealed granulomatous endometritis with caseating necrosis. Ziehl-Neelsen staining confirmed the presence of acid-fast bacilli. A diagnosis of endometrial tuberculosis was established. The patient was started on 8 months anti-tuberculosis therapy.

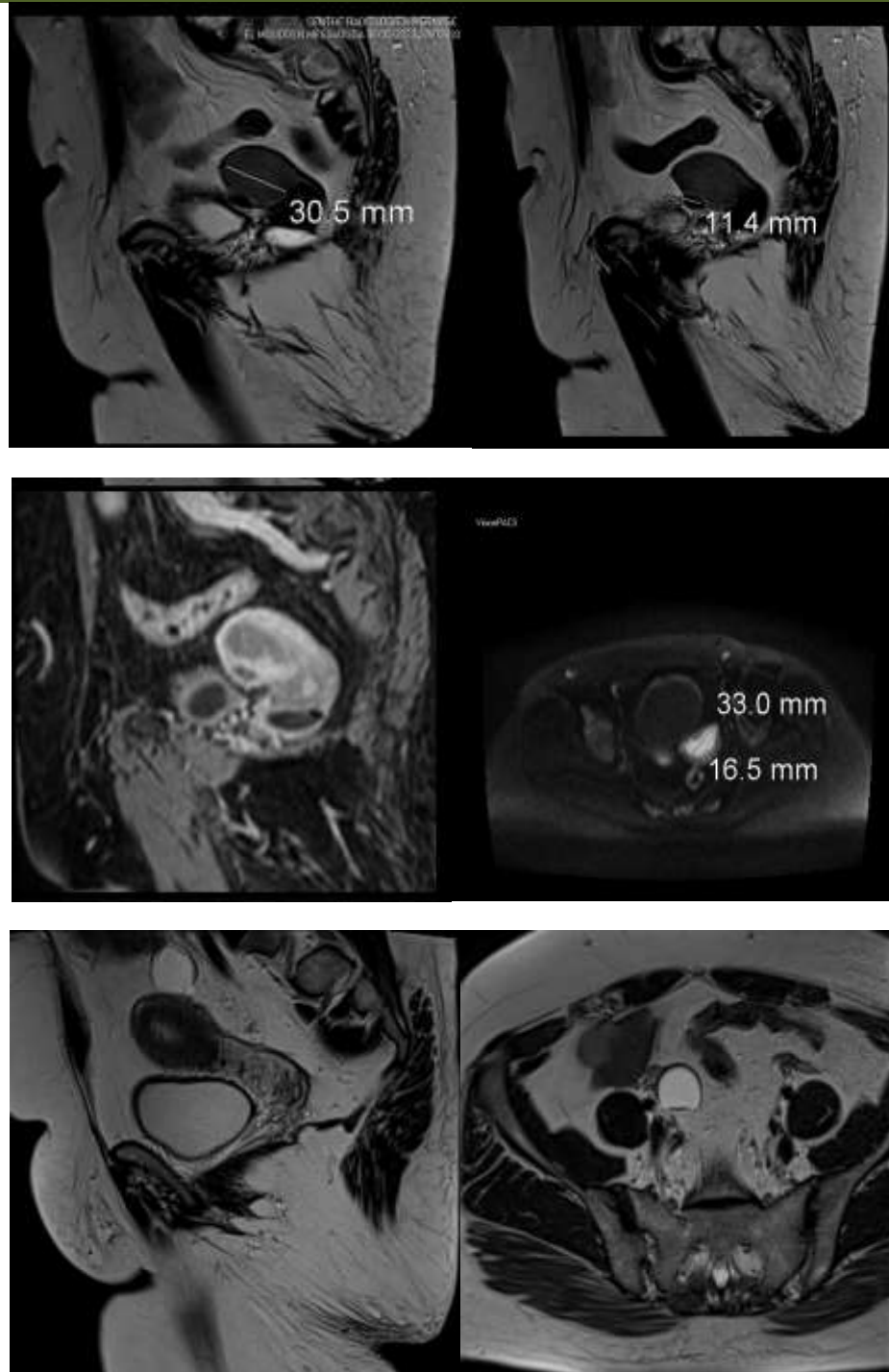


Figure 1: MRI of the pelvis showed a heterogeneously hypointense endometrium on T2-weighted imaging,s and mild enhancement post-contrast. No myometrial invasion was observed

DISCUSSION

Postmenopausal endometrial tuberculosis is extremely rare and poses significant diagnostic difficulties due to its overlap with endometrial carcinoma. In menopausal women, TB may reactivate in atrophic endometrium, often presenting with abnormal uterine bleeding or pyometra. Imaging plays a pivotal role in early suspicion:

Differential Diagnosis Includes: Endometrial carcinoma, chronic endometritis, endometrial polyps with calcifications

Clues Favoring TB on Imaging: Calcifications within the endometrium, No deep myometrial invasion, Clinical history of prior TB, Heterogeneous enhancement without mass effect.

Histological examination remains the gold standard, as imaging alone cannot distinguish granulomatous endometritis from malignancy with certainty. Early diagnosis avoids unnecessary hysterectomy and allows effective medical treatment.

CONCLUSION

Although rare, endometrial tuberculosis should be considered in postmenopausal women with endometrial thickening or abnormal bleeding, especially in endemic regions or with prior TB history. Radiologic features, while non-specific, may raise suspicion and guide appropriate biopsy. MRI, in combination with clinical and histological data, is essential for timely diagnosis and conservative management.

REFERENCES

- Kundu S, Bandyopadhyay R, Bhattacharyya A. Endometrial tuberculosis: hysteroscopic diagnosis and follow-up. *J Obstet Gynaecol Res*. 2014;40(7):1871–1874.
- Mondal SK, Histopathological spectrum of female genital tract tuberculosis: a 20-year retrospective study. *J Obstet Gynaecol India*. 2016;66(5):341–346.
- Outwater EK, Siegelman ES, Hunt JL. Ovarian teratomas: tumor types and imaging characteristics. *Radiographics*. 2001;21(2):475–490.
- Sharma JB. Female genital tuberculosis: a review. *Obstet Gynecol Surv*. 2015;70(6):373–379.