**Scholars Journal of Medical Case Reports**
Abbreviated Key Title: Sch J Med Case Rep
ISSN 2347-9507 (Print) | ISSN 2347-6559 (Online)
Journal homepage: https://saspublishers.com

OPEN ACCESS

**Surgery**

# Management of Posterior Tibial Plateau Fractures

Issoual Ilyass[1]*, Badredine Oussama[1], Habab Mohamed[1], Elkasseh Mostapha[1], Nassiri Mohamed[1], Achkoun Abdessalem[1], Chafik Rachid[1]

[1]Department of Orthopaedic and Trauma Surgery A, Mohammed VI University Hospital, Faculty of Medicine and Pharmacy, Cadi Ayyad University, Marrakech, Morocco

**DOI:** https://doi.org/10.36347/sjmcr.2026.v14i11.099 | **Received:** 19.09.2026 | **Accepted:** 21.11.2026 | **Published:** 26.11.2026

***Corresponding author:** Issoual Ilyass
Department of Orthopaedic and Trauma Surgery A, Mohammed VI University Hospital, Faculty of Medicine and Pharmacy, Cadi Ayyad University, Marrakech, Morocco

**Abstract** | **Original Research Article**

Tibial plateau fractures with a posterior component are often underestimated on plain radiographs, and the choice of surgical approach remains debated. This study aimed to evaluate the clinical, functional and radiological outcomes of their management. We conducted a retrospective descriptive study in the Department of Orthopaedic and Trauma Surgery A, Mohammed VI University Hospital, Marrakech, between January 2022 and December 2024. Of 122 tibial plateau fractures, 87 (71.3%) had a posterior component and 74 patients were included. Mean age was 47 years (range 19–92) and 77% were men. Road traffic accidents accounted for 87.8% of cases. Schatzker type VI predominated (56.8%). According to the revisited Schatzker classification, 49 fractures (66.2%) were antero-posterior and 23 (31.1%) purely posterior. Computed tomography was obtained in 52 patients (70.3%). Two patients were treated non-operatively and 72 underwent surgery: combined anterolateral and posteromedial approaches (44.4%), dual anterolateral and anteromedial approaches (43.1%), posterior or posterolateral approaches (8.3%) and Ilizarov circular external fixation (4.2%). At a mean follow-up of 14.6 months (range 6–24), all fractures had healed. The Hospital for Special Surgery (HSS) knee score was excellent in 29.7%, good in 39.2%, fair in 17.6% and poor in 13.5% of patients, giving 68.9% good to excellent results. Complications included knee stiffness (13.5%), two deep surgical site infections (2.7%), two cases of early osteoarthritis (2.7%), one superficial skin complication and one malalignment. Computed tomography with 3D reconstruction is essential to identify the posterior fragment and select the surgical approach. Anatomical reduction, direct buttressing of the posterior fragment and early rehabilitation determine the functional outcome.

**Keywords:** Tibial plateau, Posterior fracture, Revisited Schatzker classification, Computed tomography, Posteromedial approach, Internal fixation, HSS score.

**Copyright © 2026 The Author(s):** This is an open-access article distributed under the terms of the Creative Commons Attribution **4.0 International License (CC BY-NC 4.0)** which permits unrestricted use, distribution, and reproduction in any medium for non-commercial use provided the original author and source are credited.

## INTRODUCTION

Tibial plateau fractures account for approximately 1–2% of all fractures [1]. Among them, fractures with a posterior component form a distinct clinical and radiological entity that has long been underestimated. Depending on the series and the use of cross-sectional imaging, posterior involvement is found in 28–70% of tibial plateau fractures [2,3].

The posterior part of the tibial plateau forms an overhang that contributes to knee stability in flexion, particularly under varus or valgus stress [3,4]. Imperfect reduction of this area compromises joint congruence and exposes the patient to instability, stiffness and post-traumatic osteoarthritis [3,5]. These injuries mostly result from high-energy trauma, although minor trauma may suffice in osteoporotic bone.

Plain radiographs poorly detect the posterior fragment. Computed tomography (CT) with multiplanar and 3D reconstructions has become the reference examination to define fracture morphology and plan the approach [2,5]. The classic Schatzker classification does not describe the posterior component. It has been complemented by Luo's three-column concept and by the revisited Schatzker classification, which adds anterior (A) and posterior (P) modifiers [6,7].

Surgical management remains debated. It must restore the articular surface and mechanical axis and provide stable fixation allowing early mobilisation, while addressing associated injuries. There is no consensus on the choice between conventional approaches, direct posterior approaches and combined approaches.

The aim of this study was to describe the epidemiological, clinical and radiological features of posterior tibial plateau fractures managed in our department, and to evaluate their functional and radiological outcomes.

## Materials and Methods

**Study design.**

This was a retrospective, descriptive, single-centre study conducted in the Department of Orthopaedic and Trauma Surgery A, Mohammed VI University Hospital, Marrakech, over a 3-year period from January 2022 to December 2024.

**Population.**

We included patients older than 18 years admitted for a tibial plateau fracture with a posterior component and with regular follow-up. Fractures without a posterior component, incomplete records and patients lost to follow-up were excluded. Of 122 tibial plateau fractures, 87 had a posterior component. Thirteen patients were lost to follow-up, leaving 74 patients for analysis.

**Data collection.**

Epidemiological, clinical, radiological and therapeutic data were extracted from medical records using a standardised data collection form. Late outcomes were collected at outpatient visits, by recalling patients, or by telephone for those living far from Marrakech.

**Imaging and classification.**

All patients had anteroposterior and lateral knee radiographs, supplemented by oblique views in 7 patients. CT with multiplanar and 3D reconstructions was performed whenever available. Fractures were classified according to the Schatzker classification and the revisited Schatzker classification of Kfuri and Schatzker [6]. The latter divides the plateau into anterolateral (AL), anteromedial (AM), posterolateral (PL) and posteromedial (PM) quadrants using an equatorial line passing through the fibular head laterally and the posterior border of the medial collateral ligament medially. Soft-tissue status was graded according to Cauchoix and Duparc for open fractures and Oestern and Tscherne for closed fractures.

**Management.**

The choice of approach and implant was based on fracture line topography, displacement, articular depression and soft-tissue condition. All procedures were performed under a pneumatic tourniquet and fluoroscopic control. Patients received low-molecular-weight heparin thromboprophylaxis for 4–6 weeks and 48 hours of antibiotic prophylaxis. Open fractures additionally received amoxicillin–clavulanic acid for 6 weeks combined with gentamicin for 3–5 days. Rehabilitation aimed at full extension from the first postoperative days, followed by passive and active mobilisation and progressive muscle strengthening. Full weight-bearing was delayed for 3 months.

**Outcome assessment.**

Functional outcome was assessed at last follow-up using the Hospital for Special Surgery (HSS) knee score [8]: excellent (85–100 points), good (70–84), fair (60–69) and poor (< 60). Radiological assessment focused on bone union and limb alignment. Complications were recorded.

**Statistical analysis.**

Data were entered and analysed with Microsoft Excel 2019. Categorical variables are expressed as counts and percentages, and continuous variables as means with ranges.

## Results

**Epidemiological data.**

Fractures with a posterior component accounted for 71.3% (87/122) of all tibial plateau fractures over the study period, i.e. about 25 included cases per year. Mean age was 47 years (range 19–92) and the male-to-female ratio was 3.35. The left side was involved in 63.5% of cases. Twenty-one patients (28.4%) had a relevant medical history, mainly smoking (8.1%), diabetes (4.1%) and hypertension (4.1%). The main characteristics are summarised in Table 1.

**Table 1: Characteristics of the series (n = 74)**

| Variable | n | % |
|---|---|---|
| Male sex | 57 | 77.0 |
| Left side | 47 | 63.5 |
| ***Aetiology*** | | |
| Road traffic accident | 65 | 87.8 |
| Fall from height | 5 | 6.8 |
| Domestic accident | 2 | 2.7 |
| Assault | 2 | 2.7 |
| ***Mechanism*** | | |
| Mixed compression | 35 | 47.3 |
| Lateral compression | 27 | 36.5 |
| Axial compression | 12 | 16.2 |
| | | |

| ***Associated injuries*** | | |
|---|---|---|
| Open fracture (Cauchoix I: 7; II: 1; III: 1) | 9 | 12.2 |
| Closed soft-tissue injury (Tscherne 1: 13; Tscherne 2: 10) | 23 | 31.1 |
| Fibular head fracture | 23 | 31.1 |
| Other fractures (patella 4, femur 4, leg 2, pelvis 2) | 12 | 16.2 |
| Ligament injury (ACL 3, MCL 2, LCL 2) | 7 | 9.5 |
| Meniscal detachment (lateral 5, medial 2) | 7 | 9.5 |

**Clinical data.**

All patients presented with pain and complete loss of function. Knee swelling was found in 73 patients (98.6%), patellar ballottement in 30 (40.5%) and deformity in 11 (14.9%). Associated bone injuries were present in 35 patients (47.3%). No neurovascular injury was found; angiography performed in one patient with absent distal pulses was normal. Two polytrauma patients with craniofacial injuries were first stabilised in the intensive care unit.

**Imaging and classification.**

CT was performed in 52 patients (70.3%); no patient had preoperative MRI. The distribution according to both classifications is shown in Table 2.

**Table 2: Distribution according to the Schatzker and revisited Schatzker classifications (n = 74)**

| Classification | n | % |
|---|---|---|
| ***Schatzker*** | | |
| Type I | 3 | 4.1 |
| Type II | 8 | 10.8 |
| Type III | 0 | 0 |
| Type IV | 10 | 13.5 |
| Type V | 11 | 14.9 |
| Type VI | 42 | 56.8 |
| ***Revisited Schatzker*** | | |
| A + P (antero-posterior) | 49 | 66.2 |
| P (purely posterior) | 23 | 31.1 |
| AM + PM + PL | 1 | 1.4 |
| AL + PL + PM | 1 | 1.4 |

**Treatment.**

Two patients (2.7%) were treated non-operatively for an undisplaced fracture: a long leg cast for 6 weeks in a 60-year-old patient with an embolic heart disease (type I-P), and a hinged knee brace in an 88-year-old diabetic woman (type III-P). The remaining 72 patients underwent surgery after a mean delay of 3 days (range 1–18). Anaesthesia was spinal in 56 patients and general in 16, including 8 conversions. Patients were positioned supine with the knee flexed at 60° in 66 cases, prone in 4 cases, and repositioned intraoperatively in 2 cases; Ilizarov frames were applied on a traction table. Surgical approaches are detailed in Table 3.

**Table 3: Surgical approaches and fixation methods (n = 72 operated patients)**

| Approach / fixation | n | % |
|---|---|---|
| Anterolateral + posteromedial | 32 | 44.4 |
| Anterolateral + anteromedial | 31 | 43.1 |
| Direct posterior, prone | 2 | 2.8 |
| Posteromedial (Luo), prone | 2 | 2.8 |
| Modified Frosch posterolateral, without fibular osteotomy | 1 | 1.4 |
| Posteromedial + modified Frosch | 1 | 1.4 |
| Ilizarov circular external fixator | 3 | 4.2 |

A submeniscal arthrotomy was performed in 54% of patients to check articular reduction and explore the menisci. Depressed fragments were elevated en bloc with a bone tamp. Internal fixation (69 patients) used T- or L-shaped tibial plateau buttress plates, occasionally anatomical locking plates, and distal radius T-plates for small posterior fragments. Subchondral 3.5-mm cancellous screws were placed as a raft in 8 patients, and an iliac crest corticocancellous graft filled the metaphyseal void in 3 patients. The three Ilizarov frames were used for open fractures or severe soft-tissue compromise. All 7 meniscal detachments were reattached. The 7 ligament injuries were treated by screw fixation of the anterior tibial spine, transosseous suture of the lateral collateral ligament or screw fixation of a femoral avulsion of the medial collateral ligament. Mean hospital stay was 9 days (range 3–21).

Rehabilitation was early in 34 patients (45.9%) and delayed in 32 (43.2%); 8 patients (10.8%) had none because of lack of access. Its mean duration was 26 days (range 15 days to 12 months).

**Functional and radiological outcomes.**

At a mean follow-up of 14.6 months (range 6–24), all fractures had healed and no secondary displacement was observed. The HSS score was good or excellent in 51 patients (68.9%) (Table 4). Full weight-bearing was resumed at 3 months in 90% of patients and between 5 and 6 months in the others. Thirty-two patients (43.2%) reported occasional pain, 7 (9.5%) knee laxity and 10% a persistent limp.

**Table 4: Functional outcome according to the HSS score and complications (n = 74)**

| Outcome | n | % |
|---|---|---|
| ***HSS score*** | | |
| Excellent (85–100) | 22 | 29.7 |
| Good (70–84) | 29 | 39.2 |
| Fair (60–69) | 13 | 17.6 |
| Poor (< 60) | 10 | 13.5 |
| ***Complications*** | | |
| Stiffness (flexion ≤ 90°: 9; 10° flexion contracture: 1) | 10 | 13.5 |
| Deep surgical site infection | 2 | 2.7 |
| Early osteoarthritis | 2 | 2.7 |
| Superficial skin complication | 1 | 1.4 |
| Malalignment (non-operatively treated patient) | 1 | 1.4 |

Both deep infections healed after surgical debridement without implant removal and targeted antibiotic therapy. No thromboembolic or nerve complication, complex regional pain syndrome or nonunion was observed.

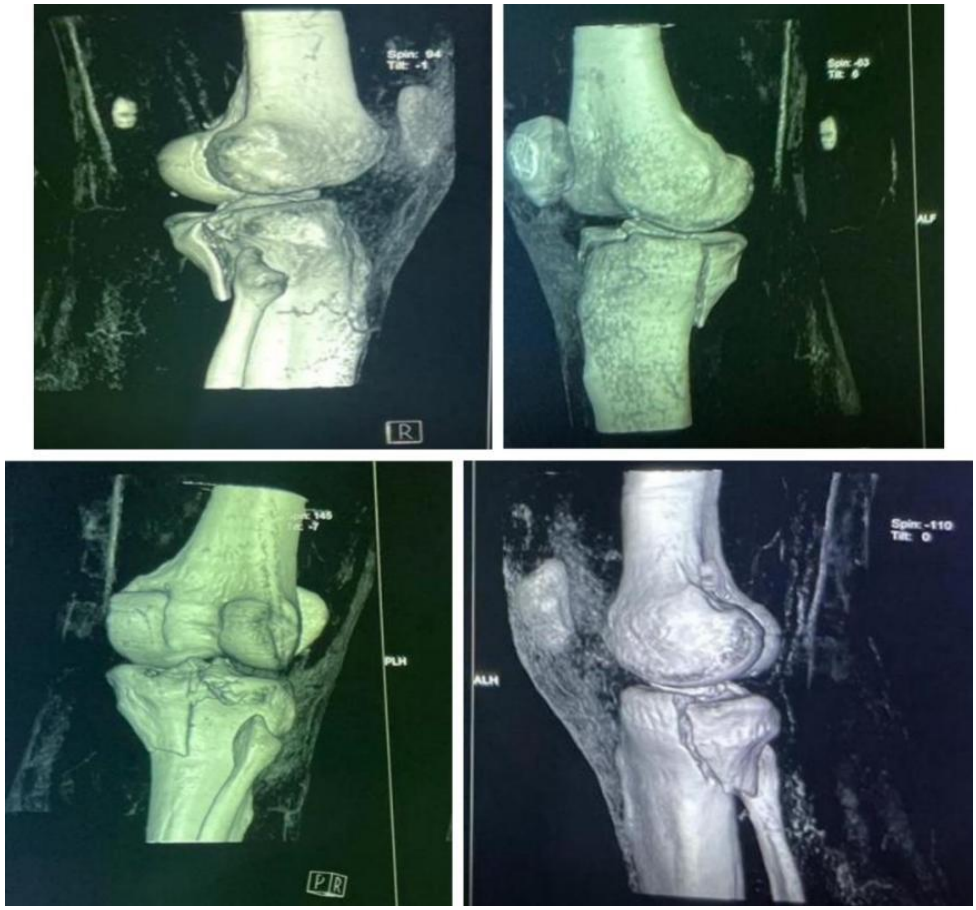

**Figure 1: 3D CT reconstructions of a medial and lateral split fracture classified as revisited Schatzker IV A-PM and IV AL.**




**Figure 2: Intraoperative anteroposterior fluoroscopic view after fixation with a lateral L-plate and a distal radius T-plate for the posteromedial fragment**



**Figure 3: Direct fixation of the posterior tibial plateau with a distal radius T-plate through a posterior approach in the prone position**

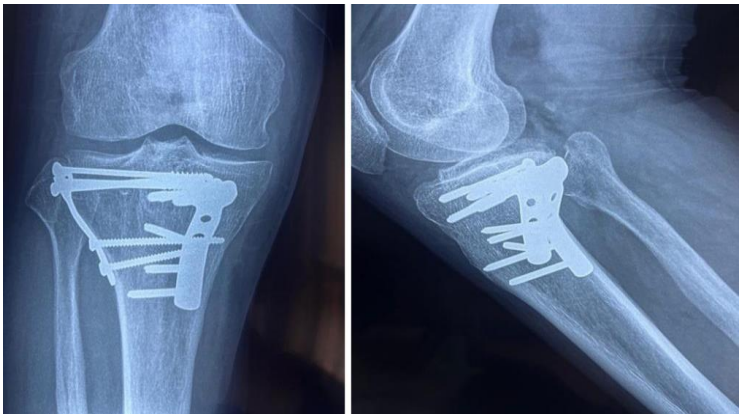

**Figure 4: Anteroposterior and lateral radiographs at one-year follow-up of a fracture classified as revisited Schatzker III AL-PM**

# DISCUSSION

In our series, 71.3% of tibial plateau fractures had a posterior component. This rate lies at the upper end of the published range (28–70%) [2,3]. It reflects both the predominance of high-energy trauma and the wide use of CT. The posterior fragment is therefore not a rare variant but a component to be sought systematically.

**Epidemiological profile.**

The mean age of 47 years is close to published data. It is higher in populations where falls predominate, such as in Denmark (52.6 years) [9], and lower where road traffic accidents affect young people [10,11]. Male predominance (77%) is consistent with the 69–73% reported in China and Colombia [10,12]. The left side was more often involved (63.5%) than in the series of Liu *et al.,*(56.6%) [13]. Road traffic accidents accounted for 87.8% of cases, compared with 95.7% in Colombia [12]. This profile highlights the importance of road safety prevention in our setting. Mixed compression was the most frequent mechanism (47.3%). Flexion mechanisms combined with varus or valgus concentrate stress on the posterior wall, which explains the frequency of posteromedial and posterolateral fragments [14,15].

**Imaging and classification.**

Schatzker type VI accounted for 56.8% of our fractures, compared with about 20% in general series [12,16]. This proportion reflects the high energy of the trauma. Plain radiographs often miss the posterior fragment, especially in comminuted fractures [16]. CT, performed in 70.3% of our patients, locates fracture lines, quantifies depression and guides the choice of approach and patient positioning. Luo's three-column classification [7] and the revisited Schatzker classification [6] both incorporate the posterior component. The latter keeps the familiarity of the Schatzker system, and its A and P modifiers directly guide the choice of approach: in our series, 97.3% of fractures were A + P or P. In our view, CT should be systematic for every tibial plateau fracture.

**Associated injuries.**

The open fracture rate (12.2%) is close to published data [17]. Fibular head fracture, found in 31.1% of cases, is comparable to the 29.9% reported by Zheng *et al.,*[18]. It indicates a high-energy mechanism and posterolateral displacement. In contrast, our rates of ligament (9.5%) and meniscal (9.5%) injuries are much lower than in the literature. Stannard *et al.,* found at least one ligament rupture in 71% of patients [19] and Risitano *et al.,* in 73.7% [20]. Meniscal tears affect 53–67% of operatively treated fractures [21,22]. With preoperative MRI, more than 90% of tibial plateau fractures show a ligament or meniscal injury [23,24]. This gap is explained by the absence of MRI in our practice, for reasons of cost and availability: our injuries were identified only intraoperatively or on a visible bony avulsion. They are therefore probably underestimated. Rigorous ligament testing after fixation, and MRI or arthroscopy when in doubt, seem necessary.

**Surgical approaches and fixation.**

The posterior fragment is poorly controlled by indirect anteroposterior fixation with a lateral plate or isolated screws. Its reduction and direct buttressing justify a posterior approach [3,5]. The posteromedial approach of Galla and Lobenhoffer exposes the posteromedial fragment through the interval between the medial gastrocnemius and the semimembranosus, with limited dissection [25]. Direct posterior approaches, S-shaped or in the prone position, provide wider exposure of the posterior column at the cost of more extensive dissection [26,27]. Luo proposed a floating position allowing combined anterolateral and posteromedial approaches without repositioning the patient [7]. In our series, the combined anterolateral and posteromedial approach was the most frequently used (44.4%), in the supine position with the knee flexed, which avoids most changes of position. The modified Frosch approach described by Mancini *et al.,* allows fixation of lateral and posterolateral fragments through a single incision, without fibular osteotomy [28]. It requires neurolysis of the common peroneal nerve and has a learning curve; we used it in two cases. For small posterior fragments, distal radius T-plates provide buttressing adapted to their size. Arthroscopic assistance is an option for isolated posterolateral depressions, but it does not replace direct exposure for large fragments requiring a buttress plate [29]. In open fractures or compromised soft tissues, the Ilizarov circular fixator limits soft-tissue damage and gives good results in complex fractures [30,31]. The posterolateral fragment then remains difficult to reduce because of the proximity of the common peroneal nerve. Finally, repair of meniscal detachments should be preferred, as meniscectomy promotes osteoarthritis [32].

**Functional outcomes.**

We obtained 68.9% good to excellent results according to the HSS score. Series dedicated to posterior fractures report 62–100% good to excellent results, with various functional scores [33–36]. Several factors explain our more modest results: the predominance of types V and VI, probably missed ligament and meniscal injuries and, above all, insufficient rehabilitation. Only 45.9% of our patients received early rehabilitation and 10.8% received none.

**Complications.**

Stiffness (13.5%) was our main complication, much more frequent than the 2.9% reported by Yao *et al.,*[37]. Distance from rehabilitation centres, appointment delays, cost and poor compliance were the main causes. Our deep infection rate (2.7%) is lower than the 7.8–11.1% reported in the literature [38,39]; both cases healed without implant removal. We observed no secondary displacement, nonunion or thromboembolic complication. Early osteoarthritis (2.7%) was far less

frequent than the 17.4% reported by Yao *et al.,*[37], but our follow-up is too short to assess this risk [40].

**Limitations.**

This study is retrospective and single-centre, without a control group. It therefore does not allow comparison of approaches. Thirteen patients were lost to follow-up. CT was not performed in all patients and none had MRI. The mean follow-up of 14.6 months is insufficient to assess post-traumatic osteoarthritis. Finally, reduction quality was not measured as articular step-off on postoperative CT.

## CONCLUSION

A posterior component is present in most high-energy tibial plateau fractures in our series and is often missed on plain radiographs. CT with 3D reconstruction and the revisited Schatzker classification allow it to be identified and guide the choice of approach. Anatomical reduction with direct buttressing of the posterior fragment, most often through combined anterolateral and posteromedial approaches, achieved union in all fractures and 68.9% good to excellent results. Better outcomes will require systematic screening for meniscal and ligament injuries, ideally by MRI, and real access to early rehabilitation. Road safety prevention remains essential to reduce these injuries.

**Conflicts of interest:** The authors declare no conflicts of interest.

**Funding:** None.

## REFERENCES

1. Albuquerque, R. P., Hara, R., Prado, J., Schiavo, L., Giordano, V., & do Amaral, N. P. (2013). Epidemiological study on tibial plateau fractures at a level I trauma center. *Acta Ortopédica Brasileira, 21*(2), 109–115.
2. Yang, G., Zhai, Q., Zhu, Y., Sun, H., Putnis, S., & Luo, C. (2013). The incidence of posterior tibial plateau fracture: An investigation of 525 fractures by using a CT-based classification system. *Archives of Orthopaedic and Trauma Surgery, 133*(7), 929–934.
3. Van den Berg, J. D., Quintens, L., Zhan, Y., & Hoekstra, H. (2020). Why address posterior tibial plateau fractures? *Injury, 51*.
4. Bryson, W. N., Fischer, E. J., Jennings, J. W., Hillen, T. J., Friedman, M. V., & Baker, J. C. (2021). Three-column classification system for tibial plateau fractures: What the orthopedic surgeon wants to know. *RadioGraphics, 41*(1), 144–155.
5. Chen, H., Chang, S., & Pan, J. (2015). Recent progress in the diagnosis and treatment of posterior tibial plateau fractures. *International Journal of Clinical and Experimental Medicine.*
6. Kfuri, M., & Schatzker, J. (2018). Revisiting the Schatzker classification of tibial plateau fractures. *Injury, 49*(12), 2252–2263.
7. Luo, C. F., Sun, H., Zhang, B., & Zeng, B. F. (2010). Three-column fixation for complex tibial plateau fractures. *Journal of Orthopaedic Trauma, 24*(11), 683–692.
8. Insall, J. N., Ranawat, C. S., Aglietti, P., & Shine, J. (1976). A comparison of four models of total knee-replacement prostheses. *Journal of Bone and Joint Surgery. American Volume, 58*(6), 754–765.
9. Elsoe, R., Larsen, P., Nielsen, N. P. H., Swenne, J., Rasmussen, S., & Ostgaard, S. E. (2015). Population-based epidemiology of tibial plateau fractures. *Orthopedics, 38*(9), e780–e786.
10. Yuwen, P., Lv, H., Chen, W., Wang, Y., Yu, Y., Hao, J., *et al.,*(2018). Age-, gender- and AO type-specific clinical characters of adult tibial plateau fractures. *International Orthopaedics.*
11. Kevin, V., Rajiv, C., Tapendranath, S., Subhankar, M., Arunabha, S., Golam, H., & Indrajit, S. (2021). Study of functional outcome of tibial plateau fractures treated with anatomical contoured locking compression plate. *Indian Journal of Orthopaedics Surgery.*
12. Reátiga Aguilar, J., Ríos, X., González Edery, E., De La Rosa, A., & Arzuza Ortega, L. (2022). Epidemiological characterization of tibial plateau fractures. *Journal of Orthopaedic Surgery and Research.*
13. Liu, Y., Liao, Z., Shang, L., Huang, W., Zhang, D., & Pei, G. (2017). Characteristics of unilateral tibial plateau fractures among adult patients. *Scientific Reports.*
14. Hua, K., Jiang, X., Zha, Y., Chen, C., Zhang, B., & Mao, Y. (2019). Retrospective analysis of 514 cases of tibial plateau fractures based on morphology and injury mechanism. *Journal of Orthopaedic Surgery and Research.*
15. Xie, X., Zhan, Y., Wang, Y., Lucas, J. F., Zhang, Y., & Luo, C. (2020). Comparative analysis of mechanism-associated 3-dimensional tibial plateau fracture patterns. *Journal of Bone and Joint Surgery. American Volume.*
16. Markhardt, B. K., Gross, J. M., & Monu, J. U. (2009). Schatzker classification of tibial plateau fractures: Use of CT and MR imaging improves assessment. *RadioGraphics, 29*(2), 585–597.
17. Reátiga Aguilar, J., Gonzalez Edery, E., Guzmán Badrán, J., Molina Gandara, J., Arzuza Ortega, L., Ríos Garrido, X., & Medina Monje, C. (2023). Open tibial plateau fractures: Infection rate and functional outcomes. *Injury.*
18. Zheng, Z., Yu, Y., Chang, H., Liu, H., Zhou, H., & Zhang, Y. (2019). Classification of tibial plateau fracture associated with proximal fibular fracture. *Orthopaedic Surgery.*
19. Stannard, J. P., Lopez, R., & Volgas, D. (2010). Soft tissue injury of the knee after tibial plateau fractures. *Journal of Knee Surgery, 23*(4), 187–192.

20. Risitano, S., Giustra, F., Bosco, F., Rea, A., Cacciola, G., Rizzolo, R., Sabatini, L., Capella, M., & Massè, A. (2024). Tibial plateau fractures are associated with ligamentous and meniscal injuries: Preoperative evaluation of magnetic resonance imaging influences surgical treatment. *European Journal of Trauma and Emergency Surgery, 50*, 2367–2374.
21. Deng, X., Hu, H., Wang, Y., Shao, D., & Zhang, Y. (2021). Arthroscopically assisted evaluation of frequency and patterns of meniscal tears in operative tibial plateau fractures. *Journal of Orthopaedic Surgery and Research, 16*, 117.
22. Chang, H., Zheng, Z., Shao, D., Yu, Y., Hou, Z., & Zhang, Y. (2018). Incidence and radiological predictors of concomitant meniscal and cruciate ligament injuries in operative tibial plateau fractures: A prospective diagnostic study. *Scientific Reports, 8*. https://doi.org/10.1038/s41598-018-31705-x
23. Thürig, G., Korthaus, A., Frosch, K.-H., & Krause, M. (2023). The value of magnetic resonance imaging in the preoperative diagnosis of tibial plateau fractures: A systematic literature review. *European Journal of Trauma and Emergency Surgery, 49*, 661–679.
24. Joo, Y.-B., Kim, Y.-M., Park, Y.-C., Chae, S.-H., & Kim, D.-H. (2024). Evaluating meniscus, ligament and soft tissue injury using MRI in tibial plateau fractures. *Medicina.*
25. Galla, M., & Lobenhoffer, P. (2003). The direct, dorsal approach to the treatment of unstable tibial posteromedial fracture-dislocations. *Der Unfallchirurg, 106*(3), 241–247. https://doi.org/10.1007/s00113-002-0554-9
26. Bhattacharyya, T., McCarty, L. P., Harris, M. B., Morrison, S. M., Wixted, J. J., Vrahas, M. S., & Smith, R. M. (2005). The posterior shearing tibial plateau fracture: Treatment and results via a posterior approach. *Journal of Orthopaedic Trauma, 19*(5), 305–310.
27. Lin, K.-C., Tarng, Y.-W., Lin, G.-Y., Yang, S.-W., Hsu, C.-J., & Renn, J.-H. (2015). Prone and direct posterior approach for management of posterior column tibial plateau fractures. *Orthopaedics & Traumatology: Surgery & Research, 101*(4), 477–482. https://doi.org/10.1016/j.otsr.2014.12.021
28. Mancini, N., Salvato, D., Delmastro, E., Belluati, A., Salini, V., & Placella, G. (2023). A modified Frosch approach for posterior tibial plateau fractures: Technical note and case series. *Injury, 54*, S9–S14. https://doi.org/10.1016/j.injury.2021.03.030
29. Ackermann, C., Frings, J., Alm, L., & Frosch, K.-H. (2019). Arthroscopic controlled closed reduction and percutaneous fixation of posterolateral tibia plateau impression fractures. *Arthroscopy Techniques, 8*(8), e867–e874. https://doi.org/10.1016/j.eats.2019.04.001
30. El Barbary, H., Abdel Ghani, H., Misbah, H., & Salem, K. (2005). Complex tibial plateau fractures treated with Ilizarov external fixator with or without minimal internal fixation. *International Orthopaedics, 29*(3), 182–185. https://doi.org/10.1007/s00264-005-0638-6
31. Katsenis, D., Dendrinos, G., & Kontos, S. (2009). High energy tibial plateau fractures treated with hybrid external fixation. *Journal of Orthopaedic Trauma, 23*(7), 493–501.
32. Ruiz-Ibán, M. Á., Diaz-Heredia, J., Elías-Martín, E., Moros-Marco, S., & Cebreiro Martinez del Val, I. (2012). Repair of meniscal tears associated with tibial plateau fractures: A review of 15 cases. *American Journal of Sports Medicine, 40*(10), 2289–2295.
33. Huo, Y., Xu, G., Yin, Z., Yu, J., Sun, X., Li, L., Gu, G., Sheng, L., & Sun, H. (2020). Effects of surgical approaches and morphological characteristics on the follow-up outcomes of patients with posterolateral tibial plateau fractures. *Medicine, 99*(16), e19854.
34. Chen, Y.-F., Ren, D., Geng, L.-D., Yao, S.-Q., Song, Z.-H., Guang, L., Wang, T.-C., & Wang, P.-C. (2021). Treatment of posterolateral tibial plateau fractures with a rotational support plate and special pressurizer: Technical note and retrospective case series. *Journal of Orthopaedic Surgery and Research, 16*, 407.
35. Hong, G., Huang, X., Lv, T., & Li, X. (2020). An analysis on the effect of the three-incision combined approach for complex fracture of tibial plateau involving the posterolateral tibial plateau. *Journal of Orthopaedic Surgery and Research, 15*, 43.
36. Wang, S.-Q., Gao, Y.-S., Wang, J.-Q., Zhang, C.-Q., Mei, J., & Rao, Z.-T. (2011). Surgical approach for high-energy posterior tibial plateau fractures. *Indian Journal of Orthopaedics, 45*(2), 125–131.
37. Yao, Y., Lv, H., Zan, J., Li, J., Zhu, N., & Jing, J. (2014). Functional outcomes of bicondylar tibial plateau fractures treated with dual buttress plates and risk factors: A case series. *Injury, 45*(12), 1980–1984. https://doi.org/10.1016/j.injury.2014.10.004
38. Colman, M., Wright, A., Gruen, G., Siska, P., Pape, H.-C., & Tarkin, I. (2013). Prolonged operative time increases infection rate in tibial plateau fractures. *Injury, 44*(2), 249–252. https://doi.org/10.1016/j.injury.2012.10.032
39. Momaya, A. M., Hlavacek, J., Etier, B., Johannesmeyer, D., Oladeji, L. O., Niemeier, T. E., Herrera, N., & Lowe, J. A. (2016). Risk factors for infection after operative fixation of tibial plateau fractures. *Injury, 47*(7), 1501–1505. https://doi.org/10.1016/j.injury.2016.04.011
40. Gálvez-Sirvent, E., Ibarzábal-Gil, A., & Rodríguez-Merchán, E. C. (2022). Complications of the surgical treatment of fractures of the tibial plateau: Prevalence, causes, and management. *EFORT Open Reviews, 7*(8), 554–568.