

## The Interest of Tenon Grafting in the Therapeutic Management of Corneal Perforations: About A Series of 24 Cases: Preliminary Results

Meryem Mouajab<sup>1\*</sup>, Hassan Moutei<sup>1</sup>, Fouad Chraibi<sup>1</sup>, Meriem Abdellaoui<sup>1</sup>, Idriss Benatiya<sup>1</sup><sup>1</sup>Ophthalmology Department, HASSAN II Hospital, Sidi Mohamed Ben Abdallah University FEZ MoroccoDOI: <https://doi.org/10.36347/sjmcr.2026.v14i04.020>

| Received: 22.02.2026 | Accepted: 01.04.2026 | Published: 11.04.2026

**\*Corresponding author:** Meryem Mouajab

Ophthalmology department, HASSAN II hospital, sidi Mohamed ben Abdallah university FEZ Morocco

## Abstract

## Case Series

Corneal perforations are defined by a total loss of the various corneal layers of varying significance, which may be of infectious, traumatic, trophic, immunological, or inflammatory origin, affecting both the functional and anatomical prognosis of the eye. Management involves closing the corneal perforation as soon as possible for optimal anatomical and functional recovery. Objective: To define Tenon patch grafting as an effective and promising surgical technique in the management of corneal perforations, especially in developing countries with good anatomical and functional results. Methods: Prospective study collecting epidemiological and clinical data as well as anatomical and functional outcomes of 24 patients treated with this surgical technique over a one-year period, between January 2021 and December 2021; whose follow-up was conducted both by the slit lamp and anterior segment OCT during the follow-up period. Results: The Tenon's capsule graft has demonstrated its effectiveness in the management of corneal perforations, with immediate closure of the corneal perforation achieved in 23 cases, representing 95.83% of our study. Regarding the functional outcomes of our series, the mean final visual acuity was 2.04 Log MAR. Our study has demonstrated that the OCT of the anterior segment constitutes a non-invasive, effective, and objective means in the follow-up period. Conclusion: Tenon graft is effective, promising, and less costly surgical technique, as shown by several studies, particularly useful when corneal grafts are not available and especially in emergencies.

**Keywords:** corneal perforation; Tenon's capsule graft; corneal graft; keratitis.

Copyright © 2026 The Author(s): This is an open-access article distributed under the terms of the Creative Commons Attribution 4.0 International License (CC BY-NC 4.0) which permits unrestricted use, distribution, and reproduction in any medium for non-commercial use provided the original author and source are credited.

### INTRODUCTION

Corneal perforations constitute an ophthalmologic ocular emergency requiring rapid closure of the corneal defect. They represent a significant cause of ocular morbidity and blindness [1,2]. Their causes are multiple and can be either traumatic, infectious, or immune in origin. Their therapeutic management is surgical, and it must be rapid and appropriate to establish the integrity of the ocular globe and to prevent endophthalmitis. The therapeutic management of these corneal perforations is based on well-established surgical treatments, the indication of which depends on the size, type, and etiology of these perforations. Among these different surgical techniques are the application of cyanoacrylate biological glue, corneal grafting, Tenon patch grafting, amniotic membrane grafting, or fibrin membrane grafting [3]. These several surgical techniques can be used, but they are not always available. Tenon patch grafting aims to restore the integrity of the ocular globe and thus allow proper healing, subsequently enabling a corneal graft.

The use of a Tenon graft provides an advantage in the management of corneal perforations given its availability compared to other therapeutic means, especially in urgent situations, as well as the absence of risk of rejection during its use. This technique, which is little described in the literature, was initially used in the management of scleromalacia after pterygium excision, or rather in cases of post-traumatic scleral perforations, or perforations of filtration blebs following trabeculectomy [4, 5, 6, 7, and 8]. The objectives of this study are to report and describe a series of cases of corneal perforations, whether of traumatic, infectious, or immune origin, and to define the modalities of their management by Tenon's graft in a center where emergency access to amniotic membrane grafts and corneal grafts is limited, but also to report the anatomical and functional outcomes of this procedure performed and to demonstrate the contribution of anterior segment OCT as a means of non-invasive and effective monitoring in this surgical procedure.

**Citation:** Meryem Mouajab, Hassan Moutei, Fouad Chraibi, Meriem Abdellaoui, Idriss Benatiya. The Interest of Tenon Grafting in the Therapeutic Management of Corneal Perforations: About A Series of 24 Cases: Preliminary Results. Sch J Med Case Rep, 2026 Apr 14(4): 665-670.

## MATERIALS AND METHODS

• **Type of study:** This is a prospective study of a series of 24 patients managed in the ophthalmology department at Hassan II University Hospital in Fez over a period of one year, from January 2021 to December 2021.

• **Surgical technique:** The Tenon capsule is harvested from the same affected eye. Any Tenon harvesting site can be chosen, but the temporal side is preferable due to the ease of harvesting and its management. The harvesting technique is performed by injecting 0.1 to 0.2 cc of 0.9% saline sub-conjunctivally to facilitate the dissection of the two layers: conjunctiva and Tenon, after which the Tenon capsule is harvested according to the size of the perforation, as shown in image 1. Generally, a patch slightly larger than the size of the perforation should be taken. The surgery is performed under topical or general anesthesia and includes the following steps: [7]

1. At the beginning of the procedure, the size of the corneal perforation is measured using a compass or a millimeter ruler.
2. The Tenon's tissue is harvested according to the size of the perforation.
3. The perforation site is debrided with excision of necrotic tissue.
4. Creation of a 360-degree stromal pocket around the perforation using a crescent knife, thereby defining the TUCK-IN TENON PATCH GRAFT technique, followed by fixation of the patch with buried sutures in the pocket, or the harvested Tenon's tissue can be fixed directly over the perforation without creating this stromal pocket.
5. Suturing the conjunctiva at the donor site with 7/0 Vicryl.
6. The anterior chamber is formed with an air bubble to prevent the formation of a leukoma.
7. A contact lens may subsequently be placed.

• **Inclusion and exclusion criteria:** We included all patients with a corneal perforation, regardless of its etiology and location (axial, paracentral, or peripheral). The size of the perforation was limited to 6 mm. For all patients with a perforation larger than 6 mm, an emergency penetrating keratoplasty was proposed immediately.

• **Data collection:** For each patient, we recorded using an exploitation form the age, sex, preoperative and postoperative visual acuity, as well as the characteristics of the perforation, its etiology, and the anatomical and functional evolution during the follow-up period.

• **Follow-up procedures:** Postoperative follow-up of patients was conducted on day 1, day 7, day 15, day 28, day 60, and day 90 through slit-lamp examination as well as anterior segment optical coherence tomography, also performed on day 1, day 7, day 15, day 28, and day 60.

The main postoperative monitoring parameters to assess the effectiveness of the surgical technique were the formation of the anterior chamber, the integration of the Tenon patch, and the stability of the corneal stromal thickness, either on slit-lamp examination or anterior segment optical coherence tomography.

• **Anatomical success:** it is defined by the formation of the anterior chamber on day 1 post-operation, visualized using a slit lamp as well as anterior segment OCT.

• **Functional success:** it is defined by a gain of one line or more of visual acuity after 1 month of follow-up.

• **Statistical analysis:** The collected data were classified and analyzed using Excel 2019 software.

## RESULTS

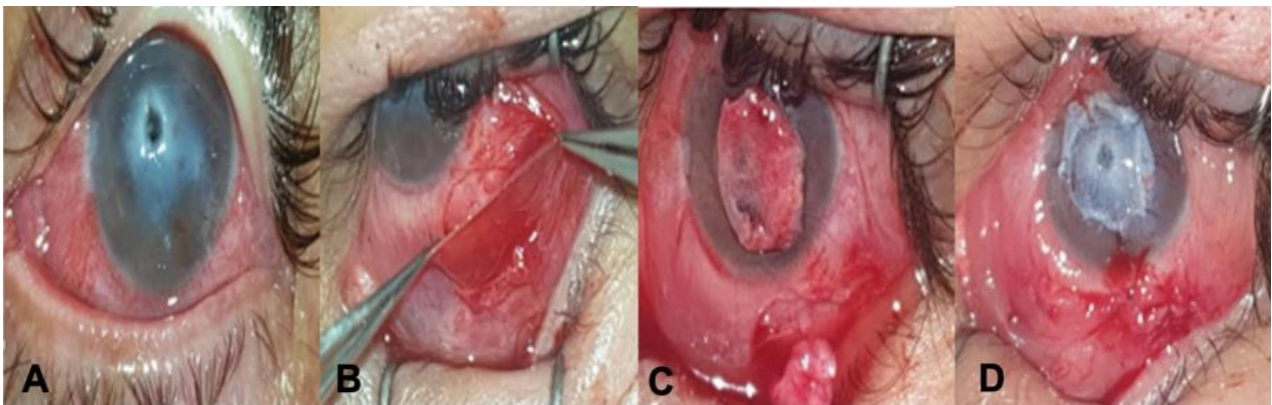
A total of 24 eyes (24 patients) were included in this study, all of whom underwent Tenon patch grafts harvested from the same patient's eye to seal the corneal perforation. The sutures were performed using 10/0 monofilament. The mean age of our patients was 55 years, with an age range from 5 to 89 years, and a male predominance of 70.84% (17 men and 7 women). The main etiology of corneal perforation in our series was corneal abscess, observed in 54.1% of cases (13 eyes), followed by traumatic causes in 20.9% of cases (5 eyes), immunological ulcers in 16.6% of cases (4 eyes), and finally neurotrophic keratitis in 8.4% of cases (2 eyes) (Table 1). Preoperative visual acuity ranged from positive light perception to 1/10. The average was 1.98 Log MAR. The average size of the corneal perforation was 4 mm, with intervals ranging from 3 to 4.5 mm. Immediate closure of the corneal perforation was achieved in 100% of cases (24 eyes), with formation of the anterior chamber observed in all our patients on postoperative day 1. For our anatomical results, out of the 24 patients during the follow-up period, 23 patients achieved preservation of the ocular globe, meaning that 95.83% experienced complete fibrosis of the perforation thanks to the Tenon graft, with restoration of corneal thickness and corneal regeneration, thus enabling these patients to be referred for a corneal transplant. Only one patient experienced therapeutic failure following the occurrence on day 30 of a Tenon capsule dehiscence; the patient underwent evisceration. Regarding the functional outcome of our series, the mean final visual acuity was 2.04 Log MAR. The average duration of the patient healing was approximately 82.1 days. According to the etiologies of corneal perforations, only a single case of anatomical failure was observed in a patient with neurotrophic keratitis. Functional results were better in patients with post-traumatic causes with a gain of one line in visual acuity in this category. For patients with infectious keratitis, regardless of the causative pathogens, a decrease of 1 line in visual acuity is observed. The mean postoperative visual acuity was 2.04 Log MAR compared to the initial visual acuity, which

was 1.98 Log MAR, resulting in a slight loss of 0,6 lines indicating no clinically significant improvement. On anterior segment OCT(AS-OCT), the mean thickness of stromal peri-lesional edema decreased from 801  $\mu\text{m}$  (day 0) to 645  $\mu\text{m}$  (day 15), corresponding to a rate of reduction of 10.4  $\mu\text{m}$  per day. The thinnest corneal thinning zone increased from 107  $\mu\text{m}$  (day 0) to 406  $\mu\text{m}$

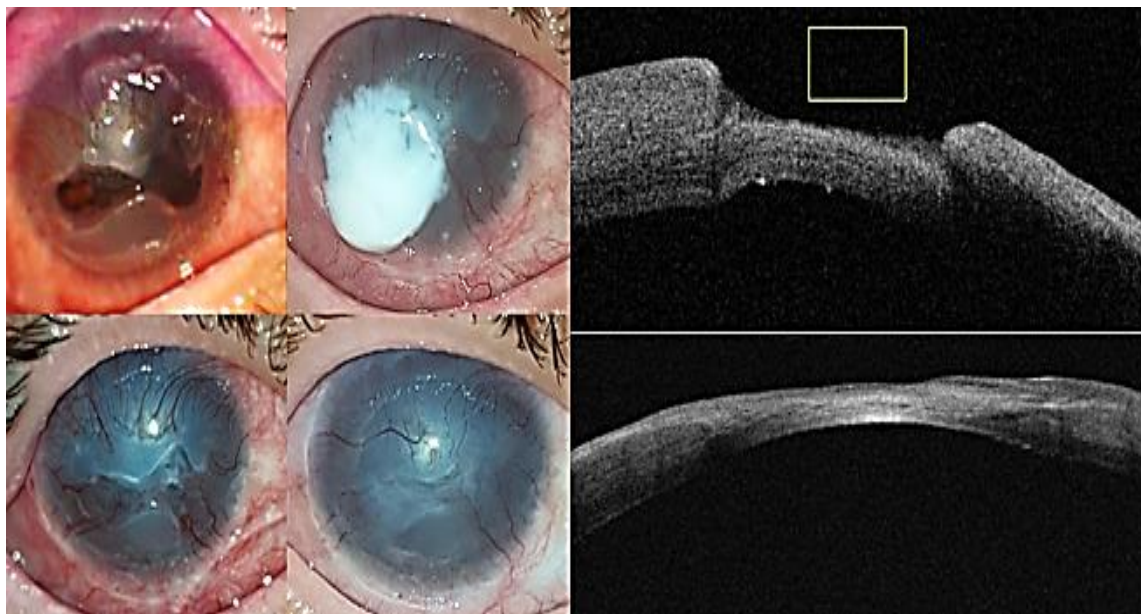
(day 15) and then to 312  $\mu\text{m}$  (day 60). These objective findings observed on anterior segment OCT are consistent with the subjective clinical improvement noted on slit-lamp examination in all our patients. The integration of the tenon capsule is observed on day 15 in 95.84% (23 cases).

**Table 1: The distribution of the etiologies of corneal perforations**

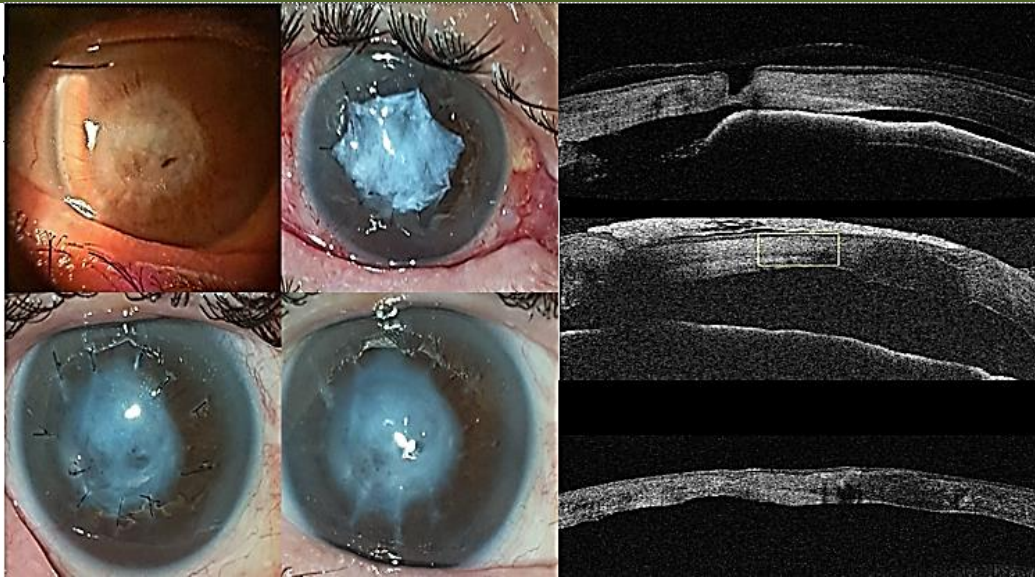
Etiology		Number	Percentage (%)
Infectious keratitis	Bacterial	5	20.9%
	Mycotic	1	4.1%
	No germs found	7	29.1%
Post-traumatic		5	20.9%
Immunological ulcer	Mooren's ulcer	1	4.1%
	Rheumatoid polyarthritis	3	12.5%
Neurotrophic keratitis		2	8.4%



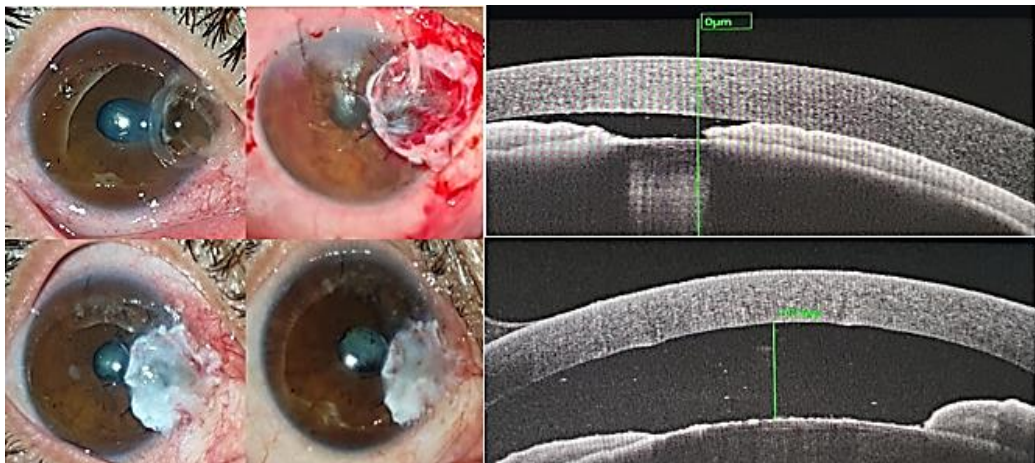
**Image 1: Intraoperative images showing the different steps carried out to obtain a Tenon's tissue sample for grafting. A: Corneal perforation due to abscessed neurotrophic keratitis. B: Harvesting the Tenon's patch. C: Placement of the Tenon's patch over the perforation. D: Fixation of the Tenon's patch onto the cornea using 10-0 monofilament**



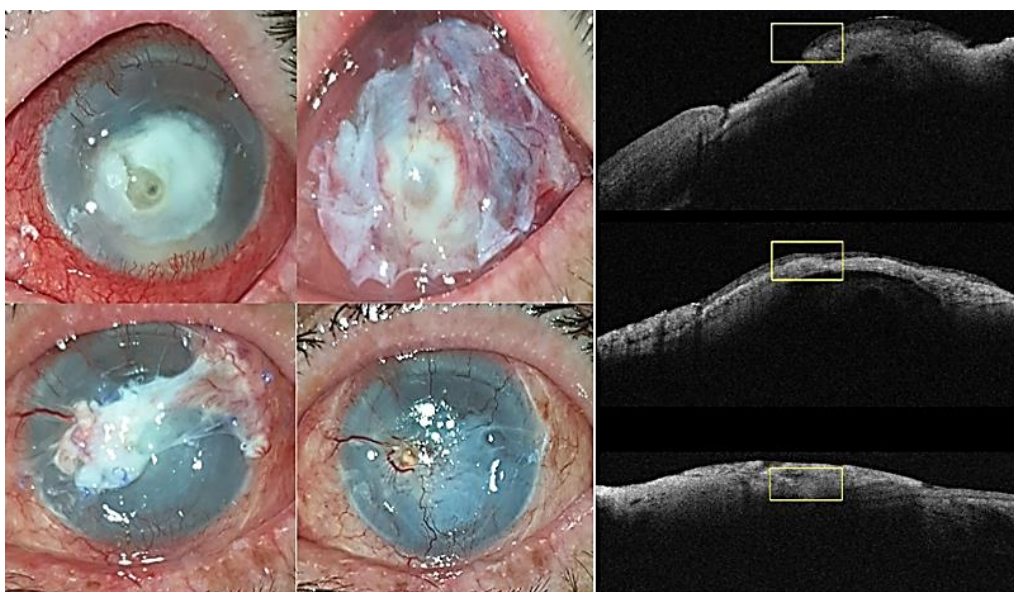
**Image 2: Evolution of a post-traumatic ulcer secondary to a chemical burn**



**Image 3: Evolution of an immunologically induced ulcer treated with Tenon**



**Image 4: Evolution of an ulcer of immunological origin secondary to rheumatoid arthritis treated with tenon; note the formation of the anterior chamber on the anterior segment OCT**



**Image 5: Evolution of a perforated infectious keratitis of fungal origin treated with Tenon patch**

## DISCUSSION

In our series of 24 cases, which represent preliminary results, our anatomical outcomes were superior to those reported in the literature by Korah and Sharma [9 and 8]. Our success rate was higher than that reported by Korah *et al.*, [9] and Sharma *et al.*, [10], with a percentage of 95.83% compared to 74% and 83.7%, respectively. This percentage rate can be explained by the way the tenon is fixed. Korah *et al.*, [9], in a 6-year retrospective study, described this technique using cyanoacrylate glue in 27 cases. Meanwhile, Sharma *et al.*, [10], in another retrospective study of 31 cases, reported this technique using a stromal pocket around 360 degrees of the corneal perforation and then securing it with 10/0 monofilament. In our prospective series of 24 cases, the technique also involved using the Tenon's capsule, but by fixing it directly without creating a pocket with 10/0 monofilament. This allows saving operative time but also achieving good anatomical results. The mean visual acuity in Log MAR before the transplant was 1.98 Log MAR and increased to 2.04 Log MAR, representing a slight loss of 0.6 lines; this can be explained by the fact that the Tenon's capsule is a fibrous, opaque tissue that does not resorb, especially since the location of the perforations is central and therefore the visual axis will be compromised. These functional results are consistent with those of Sharma *et al.*, who also found a decrease in visual acuity after the transplant. The follow-up of the Tenon graft in our study was conducted both through slit-lamp examination and anterior segment optical coherence tomography; this has not been described in any study in the literature. This is an additional examination that allows for follow-up that is more objective than the clinical slit-lamp examination. The limitation of this surgical technique remains that it is an opaque tissue, and therefore there is a risk of reducing visual acuity, especially in the case of axial corneal perforation. One drawback also of this technique is seen mainly in large corneal perforations where the tenon cannot replace the cornea biomechanically, leading to corneal ectasia and anterior segment staphyloma [11,12]. This was not observed in our series. The Tenon's capsule remains an autologous tissue, easily available, inexpensive [13], and effective without the risk of rejection or disease transmission. Its use occupies an important place in developing countries where there is a shortage of donors for corneal transplantation. Moreover, this technique increases the chance of a potential keratoplasty [14]. This surgical technique has its place today in the management of corneal perforations; it is described as an effective means in its management, as shown by Rakhi Kusumesh *et al.*, [15]. The limitation of our study remains the small number of patients involved in this study, as well as the duration of long-term follow-up of our patients compared to other studies described in the literature.

## CONCLUSION

This surgical procedure represents a promising, simple, and low-cost technique for managing corneal perforations when other therapeutic options are unavailable, especially in emergency situations. Our results allowed us to conclude and recommend this technique in urgent situations, thereby providing hope to patients, particularly those from developing countries, to preserve the morphology of the eyeball, which subsequently allows for a corneal transplant to be performed. Few studies have been published on this technique, which could help better define its indications as well as its long-term complications, thus encouraging further clinical research on this subject.

## REFERENCES

1. Vishal Jhanji, MD, Alvin L. Young, MMedSc (Hons), FRCSEd, Jod S. Mehta, MD, Namrata Sharma, MD, Tushar Agarwal, MD, and Rasik B. Vajpayee, MS, FRCS (Edin), FRANZCO. Management of Corneal Perforation. *Surv Ophthalmol* 56 :522-538, 2011
2. Stamate AC, Tătaru CP, Zemba M. Update on surgical management of corneal ulceration and perforation. *Rom J Ophthalmol*. 2019 Apr-Jun ;63(2) :166-173. PMID : 31334396; PMCID : PMC6626930.
3. C. Vasseneix, D. Toubeau, G. Brasseur, M. Muraine. Surgical management of nontraumatic corneal perforations: an 8-year retrospective study. *French Journal of Ophthalmology* Volume 29, Issue 7, September 2006, Pages 751-762. [https://doi.org/10.1016/S0181-5512\(06\)73844-X](https://doi.org/10.1016/S0181-5512(06)73844-X)
4. Morris DA, Ramocki JM, Shin DH, et al. Use of autologous tenons capsule and scleral patch grafts for repair of excessively draining fistulas with leaking filtering blebs. *J Glaucoma*. 1998; 7:417-419.
5. Lee JS, Shin MK, Park JH, et al. Autologous advanced tenon grafting combined with conjunctival flap in scleromalacia after pterygium excision. *J Ophthalmol*. 2015; 2015:547276.
6. Bae JH, Seon HK, Kim HK, et al. Use of autologous tenons capsule graft for repair of traumatic scleral perforation [in Korean]. *J Korean Ophthalmol Soc*. 2008; 49:1706-1710.
7. Maharana P, Singhal D, Sahay P, et al. Tenon patch graft for corneal fistula: a rare entity treated by a simple technique. *BMJ Case Rep*. 2017.
8. Singhal D, Sahay P, Maharana PK, et al. Clinical presentation and management of corneal fistula. *Br J Ophthalmol*. 2018 [epub ahead of print].
9. Korah, Sanita MS, DO, DNB; Selvin, Satheesh S. T. MS, DO; Pradhan, Zia S. DNB, FRCOphth; Jacob, Pushpa DNB, FRCS (Ed), FRCS (Glas); Kuriakose, Thomas DNB, FRCS (Ed). Tenons Patch Graft in the Management of Large Corneal Perforations.

- Cornea 35(5): p 696-699, May 2016. | DOI: 10.1097/ICO.0000000000000808
10. Sharma et al Tuck-In Tenon Patch Graft in Corneal Perforation Cornea\_ Volume 38, Number 8, August 2019(Cornea 2019;38:951–954).
  11. Shekhawat, Nakul Singh MD, MPH\*; Kaur, Bhavleen MBBS, MS, FICO†; Edalati, Armand BS‡; Abousy, Mya BA\*; Eghrari, Allen Omid MD, MPH\*. Tenon Patch Graft with Vascularized Conjunctival Flap for Management of Corneal Perforation. Cornea 41(11): p 1465-1470, November 2022. | DOI: 10.1097/ICO.0000000000003068
  12. Kate, A., Vyas, S., Bafna, R. K., Sharma, N., & Basu, S. (2022). Tenon's Patch Graft: A Review of Indications, Surgical Technique, Outcomes and Complications. *Seminars in Ophthalmology*, 37(4), 462–470. <https://doi.org/10.1080/08820538.2021.2017470>
  13. Johnson, SM., and Blanton, WB., 2025. Review of the uses of patch grafts in ophthalmology. *Medical Research Archives*, [online] 13(7). <https://doi.org/10.18103/mra.v13i7.6753>
  14. Smith, B., MacDonald, T., McClellan, S.F. *et al*. Management of traumatic corneal wounds that do not seal after primary closure: a systematic review. *Eye* (2026). <https://doi.org/10.1038/s41433-026-04352-0>
  15. Kusumesh R, Kishore A, Venugopal A, Shah SG, Vanathi M. Clinical application and outcome of Tenon's patch graft: A comprehensive review. *Indian J Ophthalmol* 2024; 72:1714-20.