

Management of a Giant Distal Ureteral Calculus in a Patient with Prior Bladder Exstrophy Repair: A Case Report

Ayoub MAMAD^{1*}, Mohammed Amine ELAFARI¹, Mohammed Amine BIBAT¹, Dr Omar Zineedine¹, Dr Bentaleb Youssef¹, Pr Amine SLAOU¹, Pr Tarik KARMOUNI¹, Pr Abdelatif KOUTANI¹, Pr Khalid ELKHADER¹

¹Urology B Department, Ibn Sina Hospital, University Hospital Center IBN SINA, University Mohammed V, Rabat, Morocco

DOI: <https://doi.org/10.36347/sjmcr.2026.v14i04.046> | Received: 07.03.2026 | Accepted: 19.04.2026 | Published: 23.04.2026

*Corresponding author: Ayoub MAMAD

Urology B Department, Ibn Sina Hospital, University Hospital Center IBN SINA, University Mohammed V, Rabat, Morocco

Abstract

Case Report

Adults with repaired bladder exstrophy may develop late upper urinary tract obstruction and stone disease due to complex reconstructed anatomy. Obstructive acute pyelonephritis is a urological emergency requiring urgent drainage and antimicrobial therapy, followed by delayed definitive stone treatment once infection is controlled. We report the case of a 31-year-old man with a history of bladder exstrophy reconstruction, including bilateral ureteral reimplantation in infancy and a Mitrofanoff catheterizable channel, who presented with febrile right flank pain. Computed tomography demonstrated right hydronephrosis caused by a large distal ureteral stone [30 × 13 mm; 1200 HU] at the iliac segment, associated with severe stenosis at the reimplanted ureteral orifice. He received intravenous antibiotics and urgent right percutaneous nephrostomy drainage. Renal scintigraphy performed after infection resolution showed reduced right differential renal function [22%]. Definitive surgery was performed via a right iliac approach. The stone was extracted through ureterotomy; double-J stent placement was initially impossible due to tight terminal ureteral stenosis. The ureter was transected proximal to the stenosis, a double-J stent was placed, and redo ureteroneocystostomy was completed after bladder identification by filling through the Mitrofanoff channel. Postoperative recovery was uncomplicated, with drain removal on postoperative day 2, nephrostomy removal intraoperatively, and discharge after 5 days. The ureteral stent was removed 1 month later. Follow-up to date is favorable, with no dilation on imaging and serum creatinine improving to 9 mg/L.

Keywords: Bladder exstrophy, Ureteral stone, Ureteroneocystostomy, Mitrofanoff procedure, Obstructive pyelonephritis, Reconstructive urology.

Copyright © 2026 The Author(s): This is an open-access article distributed under the terms of the Creative Commons Attribution 4.0 International License (CC BY-NC 4.0) which permits unrestricted use, distribution, and reproduction in any medium for non-commercial use provided the original author and source are credited.

INTRODUCTION

Bladder exstrophy is a rare congenital anomaly that requires complex reconstruction and lifelong follow-up. As repaired patients reach adulthood, late complications such as urinary tract infections, stone disease, and upper tract obstruction may occur, particularly in those with prior ureteral reimplantation and continent catheterizable channels [e.g., Mitrofanoff] [1,2]. Management of ureteral stones is usually guided by stone size and location; however, altered anatomy and reimplant-related ureterovesical junction stenosis can limit endoscopic access and may require open or reconstructive approaches [3,4]. We report a case of giant impacted distal ureteral calculus in an adult with bladder exstrophy repair and Mitrofanoff channel, complicated by severe stenosis at the reimplanted

ureteral orifice, managed by staged drainage followed by open ureterolithotomy and redo ureteroneocystostomy.

CASE PRESENTATION

A 31-year-old man with a complex surgical history for bladder exstrophy presented with febrile right lumbar pain suggestive of obstructive acute pyelonephritis. His childhood surgical history included bilateral ureteral reimplantation at 40 days of age and construction of a Mitrofanoff catheterizable channel. Physical examination revealed right costovertebral angle tenderness without peritoneal signs. Laboratory testing showed elevated serum creatinine of 11 mg/L. Contrast-enhanced abdominopelvic computed tomography demonstrated right pyelocaliceal dilation upstream of a large distal ureteral stone located at the iliac segment,

measuring 30×13 mm with an estimated density of 1200 Hounsfield units [Figure1].

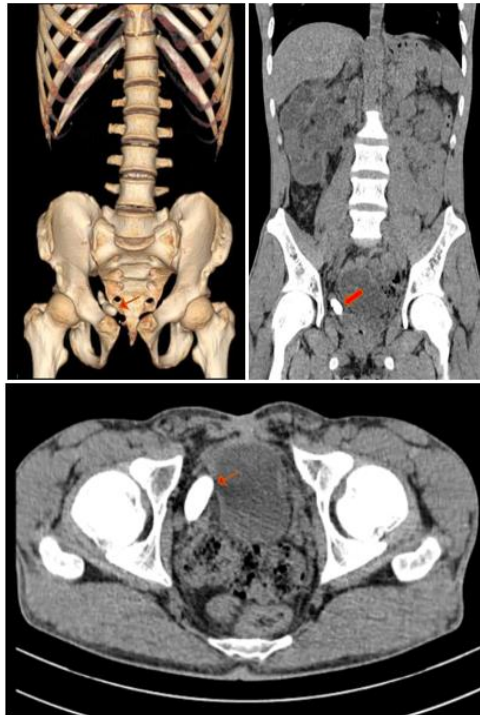

Figure 1: CT scan showing a large distal ureteral stone [red arrow] at the iliac segment with upstream right pyelocaliceal dilatation

Initial management consisted of appropriate intravenous antibiotic therapy and urgent right percutaneous nephrostomy drainage for temporary urinary diversion. After resolution of the infectious episode, renal scintigraphy showed reduced right differential renal function of 22% compared with 78% on the left.

Definitive surgical management was then performed via a right iliac approach [figure2-A]. A curved oblique incision of approximately 10 cm was made about 4 cm from the right anterior superior iliac spine, directed inferomedially. Dissection progressed

layer-by-layer through the musculoaponeurotic planes to the pelvic retroperitoneum. The iliac vessels were identified. The vas deferens was recognized and ligated to facilitate exposure. The pelvic ureter was exposed and dissected to its terminal portion [figure2-B]. The stone was localized by palpation and extracted through ureterotomy using an appropriate forceps [figure 2-C]. Attempted placement of a double-J stent failed due to severe stenosis of the terminal ureter at its vesical implantation site. The ureter was transected proximal to the stenotic segment, and a double-J stent was placed [figure2-B].

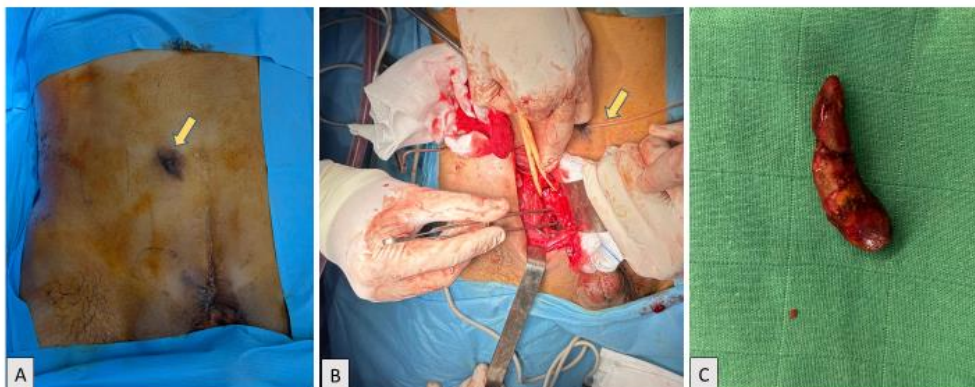

Figure 2: Definitive surgical management through a right iliac approach. [A] Right iliac incision; the yellow arrow indicates the Mitrofanoff channel. [B] Intraoperative dissection and exposure of the pelvic ureter. [C] Distal ureteral stone after extraction

The bladder was filled with 500 mL of normal saline through the Mitrofanoff channel to facilitate identification and safe dissection [figure 2-B]. Redo ureteroneocystostomy was performed using two running hemi-sutures with 4-0 polyglactin [Vicryl]. A Redon drain [CH 16] was placed, and the wound was closed in layers. Final fluoroscopic control confirmed satisfactory positioning of the proximal and distal coils of the ureteral

stent [figure 3]. The nephrostomy tube was removed intraoperatively [figure 3]. Postoperative recovery was uneventful; the drain was removed on postoperative day 2, and the patient was discharged after 5 days without complications. The ureteral stent was removed 1 month after surgery. Follow-up to date is favorable with no hydronephrosis on imaging and improvement in serum creatinine to 9 mg/L.

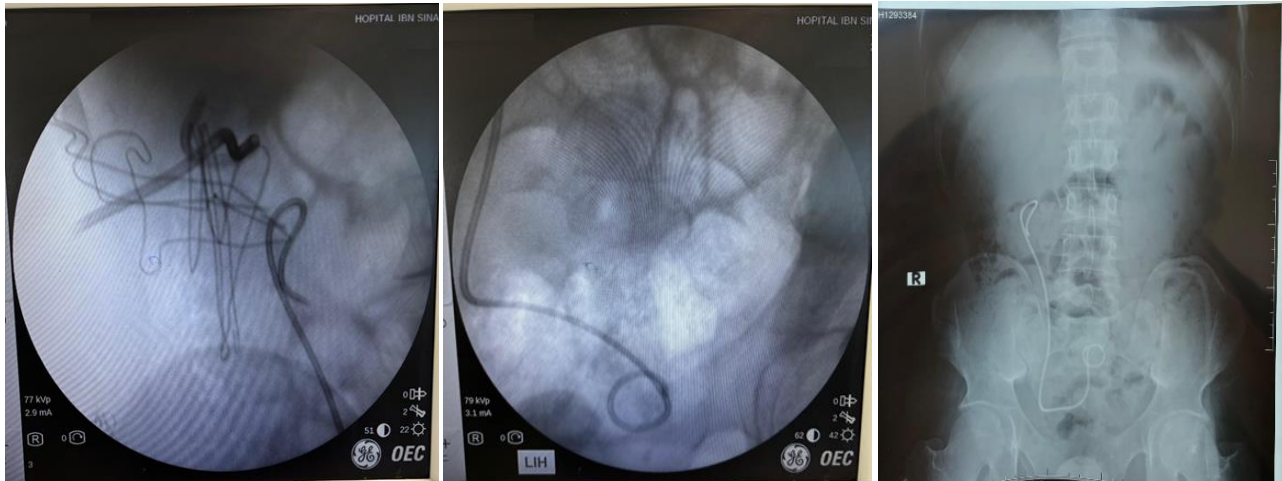


Figure 3: Intraoperative and postoperative imaging confirming satisfactory positioning of the ureteral stent after redo ureteroneocystostomy

DISCUSSION

Obstructive acute pyelonephritis is a urological emergency, and current recommendations emphasize urgent decompression of the collecting system with antibiotics, followed by delayed definitive stone treatment after infection control [3,5]. In patients with complex reconstructed anatomy after bladder exstrophy repair, retrograde access may be difficult, and percutaneous nephrostomy provides a reliable method for emergent drainage.

In the present case, definitive endoscopic management was limited by a large impacted distal ureteral stone and severe stenosis at the reimplanted ureterovesical junction. Impacted ureteral stones are associated with higher rates of ureteral injury and postoperative stricture, particularly after traumatic manipulation, reinforcing the importance of selecting an approach that minimizes ureteral damage in complex cases [6]. When distal ureteral stenosis coexists, combined stone removal and reconstructive repair may be required to restore durable drainage.

Although ureteroscopy is first-line for many ureteral stones, ureterolithotomy remains an option for selected patients, including those with very large or impacted stones, difficult access, or when concomitant reconstructive surgery is necessary [4]. In this patient, an open iliac approach allowed direct stone extraction and immediate definitive correction of the stenotic distal ureter by redo ureteroneocystostomy, after failure to pass a stent across the stenosis.

Functional assessment was important in surgical decision-making. The affected kidney contributed 22% of total renal function, supporting renal preservation. Emerging evidence suggests that ureteral reconstruction can still be successful in obstructed kidneys with very low differential function, and may be considered before nephrectomy in appropriately selected patients [7]. Intraoperatively, bladder identification in a previously reconstructed pelvis can be challenging; controlled filling via a Mitrofanoff channel can facilitate safe dissection and reconstruction. Catheterizable channels themselves have known long-term complication profiles, and familiarity with these diversions is essential when planning adult urologic surgery and follow-up [2,8].

Overall, this case illustrates a practical staged strategy: urgent decompression and infection control, delayed functional assessment, and definitive combined stone removal plus ureteral reconstruction adapted to complex post-exstrophy anatomy.

CONCLUSIONS

In adults with prior bladder exstrophy reconstruction, giant impacted distal ureteral stones may occur in association with stenosis at a reimplanted ureteral meatus, limiting endoscopic options. A staged approach—urgent drainage and antibiotics followed by functional evaluation and definitive ureterolithotomy with redo ureteroneocystostomy—can effectively relieve obstruction and preserve renal function, with favorable early outcomes.

DECLARATION:

Ethics approval and consent to participate: Ethical approval is not applicable. The case report does not contain any personal information.

Consent for publication: Written informed consent for publication of the clinical details and images was obtained from the patient.

Declaration of interests: The authors declare that they have no known competing financial interests or personal relationships that could have appeared to influence the work reported in this paper.

Funding: Not applicable

Acknowledgements: Not applicable

REFERENCES

- Morrill CC, Haffar A, Harris TGW, Crigger C, Gearhart JP. Current management of classic bladder exstrophy in the modern era. *African Journal of Urology*. 2023;29[1]:27.
- Chua ME, Rivera K, Romao R, Kim JK, Varghese A, Rickard M, *et al.*, Mitrofanoff complications: time-to-event analysis of split versus intact appendix and meta-analysis. *World J Urol*. 2025;43[1]:90.
- Skolarikos A, Geraghty R, Somani B, Tailly T, Jung H, Neisius A, *et al.*, European association of urology guidelines on the diagnosis and treatment of urolithiasis. Vol. 88, *European Urology*. Elsevier; 2025. p. 64–75.
- Mandhani A, Kapoor R. Laparoscopic ureterolithotomy for lower ureteric stones: Steps to make it a simple procedure. *Indian J Urol* [Internet]. 2009;25[1]:140–2. Available from: <http://europepmc.org/abstract/MED/19468448>
- Gnech M, Bujons A, Radmayr C, Hoen L, Bogaert G, Burgu B, *et al.*, Update and summary of the EAU/ESPU paediatric guidelines on urinary tract infection in children. *J Pediatr Urol*. 2025;
- Tonyali S YMTLEEDCVKEMA. Predictors of Ureteral Strictures after Retrograde Ureteroscopic Treatment of Impacted Ureteral Stones: A Systematic Literature Review. *J Clin Med*. 2023 May 22;12[10].
- Grimaud LW, Sury K, Salvino M, Livingston A, Lentz AC, Peterson AC. Ureteral reconstruction is safe and successful in poorly functioning kidneys. *Frontiers in Urology*. 2025; 5:1593307.
- Lopez AD SNDHWDHLA. Bladder exstrophy in adulthood: A narrative review of transitional health. *J Pediatr Urol*. 2025 Apr;21[2]:338–47.