

Descending Necrotizing Mediastinitis: Radiological Insights in Two Cases with Distinct Cervical Origins

I. Kazouini¹*, O. Fahir¹, Y. Bouktib¹, A. Elhajjami¹, B. Boutakioute¹, M. Ouali Idrissi¹, N. Cherif Idrissi Ganouni¹

¹Department of Radiology, Arrazi Hospital, Mohammed VI University Hospital, Cadi Ayad University, Marrakech

DOI: <https://doi.org/10.36347/sjmcr.2026.v14i05.064>

| Received: 24.03.2026 | Accepted: 08.05.2026 | Published: 22.05.2026

*Corresponding author: I. Kazouini

Department of Radiology, Arrazi Hospital, Mohammed VI University Hospital, Cadi Ayad University, Marrakech

Abstract

Case Report

Descending necrotizing mediastinitis (DNM) is a life-threatening infection originating from cervical or oropharyngeal sources and spreading into the mediastinum through fascial planes. Early diagnosis relies heavily on imaging, particularly contrast-enhanced computed tomography (CT). We report two cases of DNM with distinct etiologies. In both cases, CT imaging revealed characteristic findings including mediastinal air collections, fat stranding, and cervical-to-mediastinal continuity of infection. CT imaging is the cornerstone for early diagnosis and assessment of DNM. Recognition of key imaging features is essential to guide urgent management and improve prognosis.

Keywords: Descending necrotizing mediastinitis, Retropharyngeal abscess, Cervical fasciitis, CT imaging.

Copyright © 2026 The Author(s): This is an open-access article distributed under the terms of the Creative Commons Attribution 4.0 International License (CC BY-NC 4.0) which permits unrestricted use, distribution, and reproduction in any medium for non-commercial use provided the original author and source are credited.

INTRODUCTION

Descending necrotizing mediastinitis (DNM) is a rare, severe and potentially fatal pathology characterized by the downward spread of odontogenic, oropharyngeal or cervicofacial infections within the mediastinum through continuous deep fascial planes [1-2].

The physiopathology involves rapid extension of infection through the pretracheal, lateral, retropharyngeal or “danger” spaces, that provide direct anatomical communication between the neck and mediastinum [3-4].

Early clinical symptoms are often non-specific, which may delay diagnosis and worsen prognosis [3].

Imaging, particularly contrast-enhanced computed tomography (CT), plays a crucial role in diagnosis, evaluation of disease extent, establishing optimal management and serves as a point of comparison for postoperative control [5-6]. CT is considered the gold standard imaging modality due to its high sensitivity in detecting air collections, fluid collections, and mediastinal involvement [4].

Despite advances in critical care, improvements in radiographic imaging, antimicrobial therapy, and

prompt surgical treatment, DNM remains associated with high mortality rates ranging up to 40% [2-3-7].

In this paper, we present two cases of DNM with different etiologies, highlighting the radiological features and underscoring diagnostic value of CT imaging.

CASE REPORTS

Case 1

A 53-year-old male with a history of insulin-dependent diabetes was admitted for a retropharyngeal abscess following ingestion of a foreign body. The patient subsequently developed chest pain three days after admission.

Contrast-enhanced CT scan of the neck and chest revealed diffuse extension of the initial retropharyngeal abscess (Figure 1) downward through the cervicothoracic junction, involving all mediastinal compartments. The infection was characterized by extensive air bubbles within the mediastinum associated with mediastinal fat infiltration and cervico-mediastinal lymphadenopathy. (Figure 2).

These findings were consistent with the diagnosis of descending necrotizing mediastinitis secondary to retropharyngeal abscess. Patient was

admitted for intensive care, including surgical management.

Case 2

A 56-year-old male with history of hypertension and diabetes treated with oral antidiabetic drugs, was recently diagnosed with laryngeal cancer and underwent tracheostomy. Few days later, the patient developed painful and massive anterior neck swelling with fever. Blood test examinations revealed increased amount of white blood cells, neutrophils, and the level of C-reactive protein. Cervicothoracic CT scan was performed and demonstrated marked infiltration and

densification of anterior cervical soft tissues with pneumatization extending into the upper mediastinum. (Figure 3).

The patient was therefore diagnosed with cervical necrotizing fasciitis complicated by descending necrotizing mediastinitis. At this time, antibiotic therapy was initiated.

CT imaging was pivotal in both cases, revealing hallmark features of DNM.

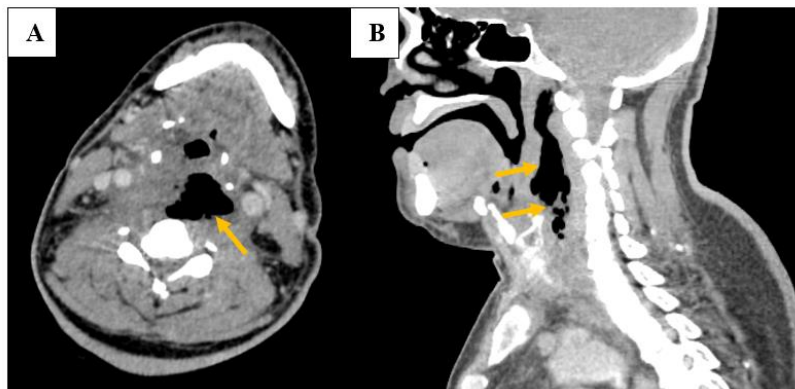


Figure 1: Initial contrast-enhanced axial (A) and sagittal (B) CT scan of the neck demonstrating a quite well limited retropharyngeal abscess containing air bubbles (yellow arrows)

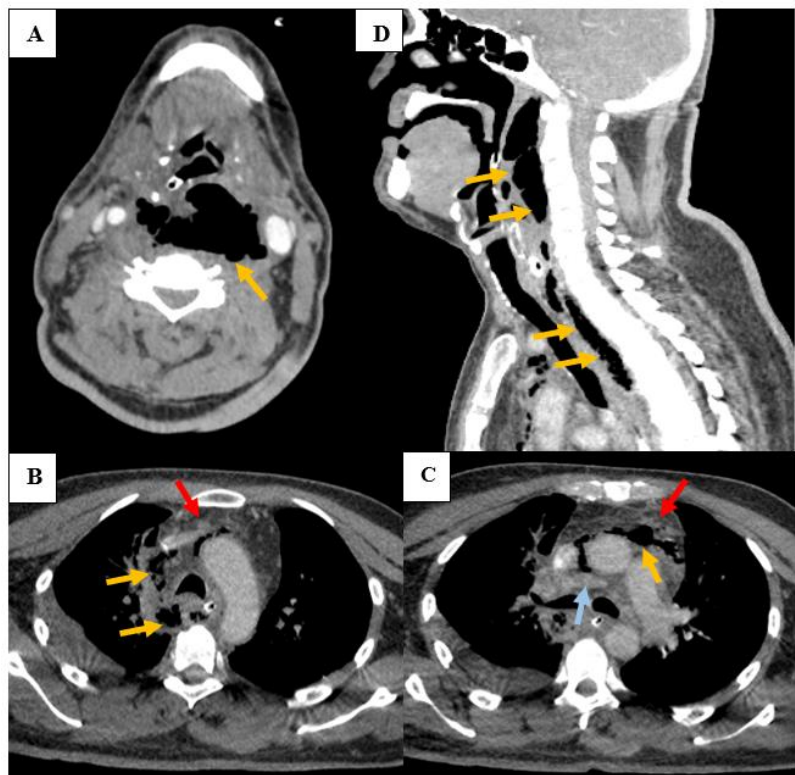


Figure 2: Follow-up axial (A, B, C) and sagittal (D) CT scan of the neck and chest revealing diffuse extension of the initial retropharyngeal abscess (Figure 1) downward through the cervicothoracic junction, involving all mediastinal compartments (yellow arrows), characterized by extensive air bubbles, mediastinal fat infiltration (red arrows) and lymphadenopathy (blue arrow)

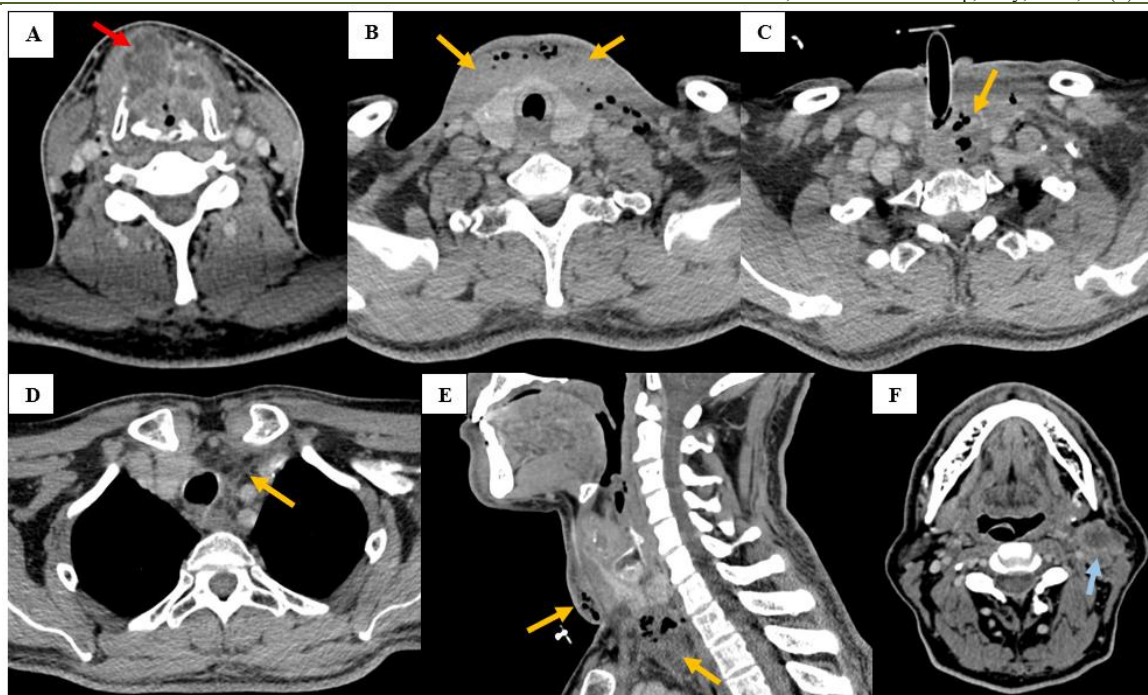


Figure 3: Cervicothoracic axial (A, B, C, D) and sagittal (E) CT scan demonstrating laryngeal cancer (red arrow) and revealing marked infiltration and densification of anterior cervical soft tissues with pneumatization extending into the upper mediastinum (yellow arrows), associated with necrotic left cervical lymphadenopathy (F) (blue arrow)

DISCUSSION

DNM was first described by Pearse in 1938 (4,8). It is a rare but rapidly progressive and often life-threatening form of mediastinitis [6-8].

It originates from infections of the oral cavity, pharynx, or cervical spaces spreading rapidly downward via anatomical fascial planes into mediastinum [3-5-6]. DNM is also caused by infection after trauma or esophageal perforations [10].

Research shows there are three pathways through which oropharyngeal infections can spread along the fascial planes to the mediastinum: the pretracheal route leading to the anterior mediastinum, the lateral pharyngeal route leading to the middle mediastinum; and the retropharyngeal route leading to the posterior mediastinum [3-11]. The “danger” space lies posterior to the retropharyngeal space and is named so because of the potential for rapid dissemination of infection to the posterior mediastinum through the lax areolar tissue [4-11].

In terms of potential risk factors, several pre-existing comorbidities and predisposing factors have been proven to promote the downward spread of infection, such as diabetes, severe chronic nicotine and alcohol abuse, immunocompromised state, present tumor illness and chronic pulmonary and cardiovascular diseases [2-8-12].

The refinement of diagnostic techniques, such as neck and chest CT, has significantly improved the

prognosis of these patients, allowing an early diagnosis, staging and assessing right treatment [7-13].

Typical CT features include gas locules in cervical and mediastinal spaces, fluid collections with rim enhancement, signs of inflammation such as fat stranding and edema, and lymphadenopathy [4-6-14].

In addition, CT scan is crucial not only for the initial diagnosis but also for identifying residual abscesses and for ongoing surveillance throughout the treatment process [1].

Plain radiograph findings are often non-specific, with the most common finding being mediastinal widening [4]. Sometimes tracheal displacement, air-fluid level, pneumonia or pleural effusion may be identified [2].

Magnetic resonance imaging (MRI) offers superior soft-tissue contrast but it is more susceptible to motion artifacts, more expensive and more time-consuming in emergency settings, making it less suitable for rapid diagnosis [1-2].

DNM is classified by Endo *et al.* according to the extent of infectious spread as demonstrated on CT: localized types confined to the upper mediastinum above the tracheal carina (Type I), infection extending into the lower anterior mediastinum (Type IIa), and diffused with involvement of both anterior and posterior mediastinum (Type IIb) [2-3-5-15].

Based on this, our first clinical case likely corresponds to DNM-type IIb, and the second categorize as DNM-type I.

Laboratory findings are typically non-specific but include an increased white blood cell count and elevated inflammatory markers [4]. Microbiological culture usually reveals polymicrobial infection with aerobic / anaerobic organisms corresponding to its pharyngeal or odontogenic origins [7-9].

DNM should be treated adequately and promptly once the diagnosis is established to reduce mortality and optimize prognosis [4-11]. No standard treatment protocol has yet been established because the causes and locations of infection vary widely [2-10].

A multidisciplinary team is required to reduce mortality, with airway management, intravenous broad-spectrum antibiotics, and surgical treatment through the drainage and debridement of the involved tissues [6-10-11]. Occasionally, only injectable antibiotic treatment is sufficient in patients who present only cellulitis or a small abscess [11].

Prognosis depends heavily on time to diagnosis and drainage, age, and DNM grade [4].

CONCLUSION

DNM remains life-threatening condition that requires rapid diagnosis and management. Imaging is mandatory to help improve clinical outcome. The presented cases highlight the central role of CT scan in identifying the descending spread of infection from cervical origins to the mediastinum, grading and evaluating its extent, then aiding scheduling therapeutic strategy.

REFERENCES

1. Parjica CP, Sievert M, Haj Khalaf MA, Ihmsen H, Higaze M, Gehrking M, et al. Management and Outcomes of Descending Necrotizing Mediastinitis: A 15-Year Experience. *J Clin Med*. 2025 Jan;14(5):1593. doi:10.3390/jcm14051593
2. Avgoustou E, Avgoustou C. Deep Neck Infections and Descending Necrotising Mediastinitis: Multidis- ciplinary Approach. A Review. 2026.
3. Benedetto C, Tanzariello VN, Militi A, Fallica GE, Marco DD, Monaco F, et al. Catastrophic descending necrotizing mediastinitis of the anterior and posterior compartments: A case report. *Radiol Case Rep*. 2020 Aug 8;15(10):1832–6. doi:10.1016/j.radcr.2020.07.040 PubMed PMID: 32802242; PubMed Central PMCID: PMC7417671.
4. Nwia SM, Huebner CD, Nguyen JB. Descending necrotizing mediastinitis secondary to retropharyngeal abscess. *J Radiol Case Rep*. 2023 Aug 31;17(8):21–8. doi:10.3941/jrcr.v17i8.5095

5. I. Kazouini *et al*, Sch J Med Case Rep, May, 2026; 14(5): 1138-1142 PubMed PMID: 38090639; PubMed Central PMCID: PMC10713229.
5. Guo J, Lin L, Zhou H, Yang W, Shi S. Descending necrotizing mediastinitis caused by Streptococcus constellatus: A case report and review of the literature. *Medicine (Baltimore)*. 2023 Apr 7;102(14):e33458. doi:10.1097/MD.00000000000033458
6. Department of Emergency Radiology, University Hospital Ibn Sina, Abderrahim Bouabid Avenue, Rabat, Morocco, Adil H, Jroundi L, Department of Emergency Radiology, University Hospital Ibn Sina, Abderrahim Bouabid Avenue, Rabat, Morocco, Laamrani FZ, Department of Emergency Radiology, University Hospital Ibn Sina, Abderrahim Bouabid Avenue, Rabat, Morocco. Imaging of descending necrotizing mediastinitis: A report of 11 cases and review of the literature. *J Clin Images Med Case Rep*. 2022 Feb 10;3(4). doi:10.52768/2766-7820/1648
7. De Palma A, Cantatore MG, Di Gennaro F, Signore F, Panza T, Brascia D, et al. Multidisciplinary Approach in the Treatment of Descending Necrotizing Mediastinitis: Twenty-Year Single-Center Experience. *Antibiotics*. 2022 May;11(5):664. doi:10.3390/antibiotics11050664
8. Reuter TC, Korell V, Pfeiffer J, Ridder GJ, Ketterer MC, Becker C. Descending necrotizing mediastinitis: etiopathogenesis, diagnosis, treatment and long-term consequences—a retrospective follow-up study. *Eur Arch Otorhinolaryngol*. 2023 Apr 1;280(4):1983–90. doi:10.1007/s00405-022-07769-x
9. Okumura T, Tetsuka N, Yamaguchi M, Suzuki T, Torii Y, Kawada J ichi, et al. A Case of Descending Necrotizing Mediastinitis in a Previously Healthy Child. Chiu NC, editor. *Case Rep Pediatr*. 2021 Jan;2021(1):3159092. doi:10.1155/2021/3159092
10. Ho CY, Chin SC, Chen SL. Management of Descending Necrotizing Mediastinitis, a Severe Complication of Deep Neck Infection, Based on Multidisciplinary Approaches and Departmental Co-Ordination. *Ear Nose Throat J*. 2024 Sep 1;103(9):572–9. doi:10.1177/01455613211068575
11. Cobzeanu BM, Moisiu L, Palade OD, Ciofu M, Severin F, Dumitru M, et al. Management of Deep Neck Infection Associated with Descending Necrotizing Mediastinitis: A Scoping Review. *Medicina (Mex)*. 2025 Feb;61(2):325. doi:10.3390/medicina61020325
12. Sarna T, Sengupta T, Miloro M, Kolokythas A. Cervical Necrotizing Fasciitis with Descending Mediastinitis: Literature Review and Case Report. *J Oral Maxillofac Surg*. 2012 Jun 1;70(6):1342–50. doi: 10.1016/j.joms.2011.05.007
13. Akman C, Ayarcan Y, Bozkurt K, Tutluoglu B, Yaman M. Descending necrotizing mediastinitis: a case report. *Eur J Radiol Extra*. 2004 Feb 1;49(2):53–6. doi:10.1016/S1571-4675(03)00120-2

14. Scaglione M, Pinto A, Giovine S, Di Nuzzo L, Giuliano V, Romano L. CT features of descending necrotizing mediastinitis—a pictorial essay. *Emerg Radiol.* 2007 Jun 1;14(2):77–81. doi:10.1007/s10140-007-0606-0
15. Endo S, Murayama F, Hasegawa T, Yamamoto S, Yamaguchi T, Sohara Y, *et al*. Guideline of surgical management based on diffusion of descending necrotizing mediastinitis. *Jpn J Thorac Cardiovasc Surg.* 1999 Jan 1;47(1):14–9. doi:10.1007/BF03217934