

A Rare Case of Periductal Mastitis in a Male

P Manimekhala^{1*}, L Aruna², VasireddyGuvera³, O Sirisha⁴, V.VijayaSreedhar⁵

^{1,3}Associate Professor, Upgraded Department of Pathology, Osmania General Hospital Hyderabad India.

²Associate Professor, Upgraded Department of Pathology, Osmania General Hospital Hyderabad India.

⁴Senior Resident, Upgraded Department of Pathology, Osmania General Hospital Hyderabad India.

⁵Professor & HOD, Upgraded Department of Pathology, Osmania General Hospital Hyderabad India.

*Corresponding Author:

Name: Dr.P. Mani Mekhala

Email: manimekhalarao@email.com

Abstract: Periductal mastitis is extremely rare in males and most of these cases usually end up as mammary duct ectasia. This is a case of a 60 year old male patient who presented with a tender breast and a tiny subareolar swelling in the right breast. There was also nipple discharge. Cytosmears from the nipple discharge were taken and features of periductal mastitis were noticed. This case is being presented because of its extreme rarity in males and the importance of diagnosing it in cytological smears thus avoiding surgery.

Keywords: Periductal mastitis, Subareolar swelling, Nipple discharge..

INTRODUCTION

Breast is composed of lobules and ducts which are surrounded by fibrous and fatty tissue. Infection of the ducts beneath the nipple causes Periductalmastitis[1,2]. It is a distinct benign clinical entity which is common in young females and is a frequent cause of mastitis in non-lactating females [3]. It is exceedingly rare in males only about few cases being reported in the literature so far [3]. Periductal mastitis almost always is associated with dilatation of the ducts with stasis of secretions[4]. Clinically the breast is tender to touch, there may be a subareolar swelling and most of the cases are associated with nipple discharge which may be bloody or non-bloody. At times there may be nipple inversion[5]. Periductal mastitis may be complicated by an abscess formation or a fistula. The clinical finding of a lump, nipple discharge and nipple inversion may mimic carcinoma breast particularly in elderly people. Infection is most commonly caused by anaerobic bacteria[6]which responds to simple antibiotic treatment and drainage. The cytologic features of periductal mastitis have been described only recently in the cytopathology literature, and fine needle aspiration (FNA) cytologic findings are based mainly on a small number of case reports in the English literature. Therefore, awareness of this entity and recognition of its cytomorphologic features can aid in a more accurate diagnosis[7].

CASE REPORT

A 60 year old male patient presented to the surgical outpatient department with a complaint of swelling in the subareolar region of the right breast. He was advised fine needle aspiration of the swelling for

further evaluation. On clinical examination, the breast was tender to touch with local rise of temperature. There was a tiny subareolar lump measuring < 0.5 cm and a purulent discharge was oozing from the nipple. He also complained of burning sensation over the chest wall. The patient also had fever with chills and rigors for a couple of days. There was no other lump in both the breasts. Examination of both the axillae did not reveal any swelling. Being an elderly man, the primary suspicion was breast carcinoma. Cytosmears taken from the nipple discharge and stained with Hematoxylin and eosin were examined. Cytosmears revealed sheets of neutrophils, adipocytes, foamy macrophages, giant cells, few plasma cells along with sheets of anucleatesquames. Aspirate from the subareolar swelling also revealed similar findings. A cytological diagnosis of periductal mastitis was given taking into consideration the clinical and cytological findings.

DISCUSSION

The terms periductal mastitis is synonymously used with mammary duct ectasia which is dilatation of ducts along with stasis of secretions. The first description of both ductal dilatation and periductal inflammation was made by Bloodgood and the term duct ectasia was popularized by Haggenson in 1951[8]. As it is more common in females, pregnancy and lactation were incriminated as a cause of the disease, but the condition was reported in virgins and males. Cigarette smoking is a risk factor for the development of periductal mastitis and the risk appears to be directly proportional to the duration of smoking[9]. Cigarette smoking may damage the ductal epithelium by its direct toxic effect[10] or indirectly by influencing the blood

flow and hormonal action on the duct epithelium. In duct ectasia and periductal mastitis, there is growing evidence indicating that both aerobic and anaerobic bacteria play a significant role in this condition[11].

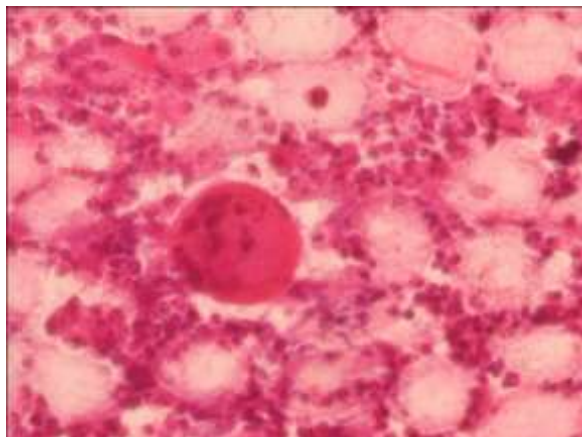


Fig: Microphotograph showing giant cells, neutrophils, squames and few plasma cells(H&E, 400x)

Whether the duct ectasia is the consequence of the periductal inflammation or it arises de novo is not established to date[12]. Ultimately most of the cases of periductal mastitis end up as mammary duct ectasia indicating that both the entities represent a continuous spectrum of the same pathological process. Tedeschi and McCarthy[13] reported the first case of duct ectasia/periductal mastitis in 1974, Jama Masad *et al.* [14] reported two cases of periductal mastitis, one of which case had associated Behcet's disease. The case we have reported had no other associated condition.

CONCLUSION

Periductal mastitis is exceedingly rare in males. Emphasis should be made on the diagnosis of this benign entity on fine needle aspiration to avoid inadvertent surgeries. This case is being presented on account of its rarity in males and the importance of its diagnosis on fine needle aspiration.

REFERENCES

1. Dixon JM;Periductal mastitis/duct ectasia. World J Surg., 1989; 13(6): 715-720.
2. Webb AJ; Mammary duct ectasia-periductal mastitis complex. Br J Surg., 1995; 82(10): 1300-1302.
3. Chan KW, Lau WY; Duct ectasia in male breast. Aust N Z J Surg., 1984; 54(2): 173-176.
4. Mansel RE, Morgan WP; Duct ectasia in the male. Br J Surg., 1979; 66(9): 660-662.
5. Rees BI, Gravelle IH, Huges LE; Nipple retraction in duct ectasia. Br J Surg., 1977; 64(8): 577-580.
6. Ashworth MT, Corcoran GD, Haggani MT;Periductal mastitis and duct ectasia in male. Postgrad Med J., 1985; 61(717):621-623.
7. Javadzadeh B, Finley J, Williams HJ; Fine needle aspiration cytology of mammary duct ectasia: report of a case with novel cytologic and immunocytochemical findings. Acta Cytol. 2001; 45(6):1027-1031.
8. Dixon JM, Anderson TJ, Lumsden AB, Elton RA, Roberts MM, Forrest AP; Mammary duct ectasia. Br J Surg., 1983; 70(10): 601-603.
9. Murad TM, Contessa G, Mouriesse H; Nipple discharge from the breast. Ann Surg., 1982; 195(3): 259-264.
10. Furlong AJ, Al-NakibL, Knox WF, Parry A, Bunderd NJ;Periductal inflammation and cigarette smoke. J Am CollSurg., 1994; 179(4): 417-420.
11. Henry PL, Leis JR; Management of nipple discharge. World J Surg., 1989; 13(6):736-742.
12. McClure J, Banerjee SS, Sandiland DGD; Female type cystic hyperplasia in a male breast. Postgrad Med J., 1985; 61(715): 441-443.
13. Tedescni LG, McCarthy PE;Involutional mammary duct ectasia and periductal mastitis in a male. Human Pathol., 1974; 5(2): 232-236.
14. Al-Masad JK;Mammary duct ectasia and periductalmastitis in males. Saudi Med J., 2001; 22(11): 1030-1033.