

Classical Galactosemia in a fifty day old male child, obscured by the concomitant presence of TORCH infection -A Case Report

Dr. Altaf Naseem¹, Dr. Naila Mazher^{2*}, Dr. Soumya Anumula³, Dr. Bismah Gul⁴, Dr. E Apoorva⁵, Dr. Wasim Akram⁶, Dr. Shafi Khan⁷.

¹Professor, ²⁻⁶Junior Resident, ⁷Assistant Professor, Department of Paediatrics, Deccan College of Medical Sciences, Owaisi Hospital and Research Centre, Hyderabad, Telangana, India, 500 058.

***Corresponding author**

Dr. Naila Mazher

Email: naila_mazher@yahoo.co.in

Abstract: Classical Galactosemia in a fifty day old male child, obscured by the concomitant presence of TORCH infection -A Case Report. Galactosemia is a rare metabolic disorder with autosomal recessive inheritance due to deficiency of one of the three enzymes needed for galactose metabolism. Classical galactosemia results from deficiency of enzyme galactose-1-phosphate uridylyl transferase (GALT). Its incidence varies greatly among different ethnic groups, manifesting in the newborn period with persistent jaundice, failure to thrive, diarrhoea, vomiting, septicemia, hepatosplenomegaly, and cataract, mortality is high if diagnosed late or left untreated. In a case report A fifty day old male baby born to 3rd consanguineous parents, was admitted with complaints of vomiting, jaundice, dull activity and abdominal distention on and off since 4th day of life. There was history of hospitalization twice in the neonatal period for jaundice during which he was diagnosed as congenital rubella syndrome based on positive TORCH profile and presence of bilateral cataract. On admission in our hospital the child appeared malnourished with pallor, icterus, pedal oedema and bilateral nuclear cataract. His urine for GCMS demonstrated high level of galactose. The levels of galactose-1-phosphate in erythrocytes was elevated (36mg/dl), with decreased quantitative GALT enzyme assay (1.0 U/g Hb) thus confirming the diagnosis of galactosemia. The child was further investigated for mutation analysis which showed Q118R gene mutation. He was given symptomatic treatment along with substitution of breast milk with soya based milk formula. In conclusion We report a case of classical galactosemia in a fifty day old male baby, misdiagnosed as congenital TORCH infection. Thereby emphasizing the need for newborn screening, and considering galactosemia as a differential diagnosis for all such cases.

Keywords: Galactosemia, lactose intolerance, inborn errors of metabolism, galactose-1-phosphate uridylyl transferase (GALT), contraindication for breastfeeding.

INTRODUCTION:

Galactosemia is a rare metabolic disorder with autosomal recessive inheritance due to deficiency of one of the three enzymes needed for galactose metabolism. First described by Friedrich Goppert, a German physician, in 1917 [1]. The estimated incidence ranges between 1 in 40,000 and 1 in 60,000 births [2].

CASE REPORT:

A fifty day old male baby was admitted in our hospital with complaints of jaundice, fever, dull activity and abdominal distention on and off since 4th day of life, he was born to a third gravida at 37 weeks of gestation by elective caesarean section, with a normal antenatal and perinatal history. His birth weight was 2.0 kgs, and was exclusively breastfed since birth. He was born to third degree consanguineous parents of Indian origin, with no history of similar complaint in the family. The child was admitted twice in the postnatal period for similar complaints on 4th and 10th day of life

during which he was investigated and diagnosed as congenital rubella syndrome based on the presence of bilateral cataract, hepatomegaly on USG abdomen and a positive TORCH profile. At admission in our hospital at fifty days of life, the child looked malnourished with gross abdominal distention, he was febrile with temperature 100^o F, faint icterus was noted, along with pallor and pitting oedema. Eye examination revealed bilateral nuclear cataract (**Figure 2**). There was no facial dysmorphism, his anthropometric measurements were suggestive of severe failure to thrive (<5th percentile). Respiratory, cardiovascular examination were essentially normal except for mild hypotonia. GI examination revealed hepatomegaly, with liver being palpable upto 4-5 cms below the right sub costal margin, having a span of 10 cms (**Figure 1B**) along with splenomegaly of 2 cm and ascites (**Figure 1A**). Inborn errors of metabolism were kept in mind, and accordingly the child was investigated, his CBP showed anaemia with leucocytosis and mild thrombocytopenia (Hb-9 %,

TLC-22cells/cumm, PLT-1.0 Lakhs/cumm) Sepsis screen was positive, however his blood culture was negative, LFT was suggestive of elevated liver enzymes along with serum alkaline phosphatase and total serum bilirubin (9mg/dl, conjugated-3.6mg/dl), with low serum Albumin (2.5 gms/dl) and impaired coagulation profile. CT brain plain revealed generalised cerebral oedema (**Figure 3**). Urine for Gas chromatography-mass spectrometry was positive for galactose. The levels of galactose-1-phosphate in erythrocytes was elevated (36mg/dl) hence quantitative GALT enzyme assay was

done which revealed significantly decreased levels of the enzyme (1.0 U/g Hb) confirming the diagnosis of galactosemia. The child was further investigated for mutation analysis which showed Q118R mutation. He was given symptomatic treatment along with substitution of breast milk with soya based milk formula. Ophthalmology referral was taken and he was posted for cataract surgery subsequently. Genetic counselling was given to the parents. The child showed clinical improvement and was thriving well in the follow up period.

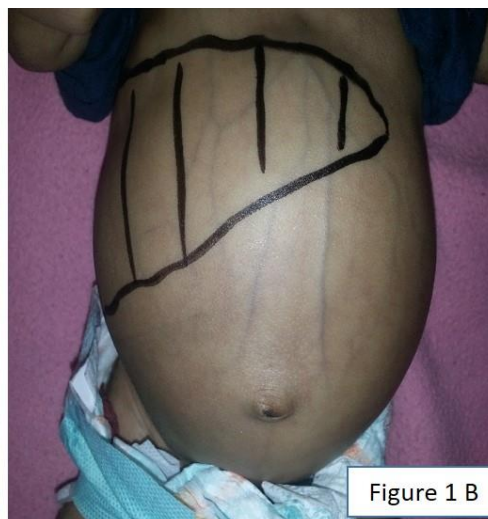
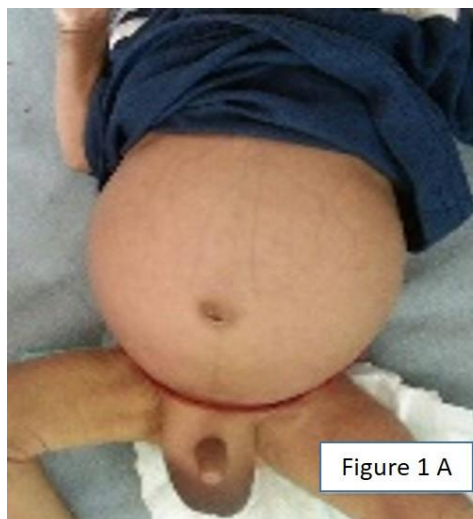
Fig-1A: Clinical photograph, showing gross abdominal distention with visible, dilated abdominal veins and everted umbilicus suggestive of ascites.

Fig-1B: Clinical photograph, depicting hepatomegaly

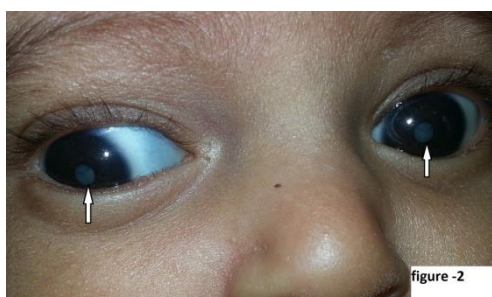

Fig-2: Clinical photograph showing bilateral nuclear cataract (as shown with arrows).

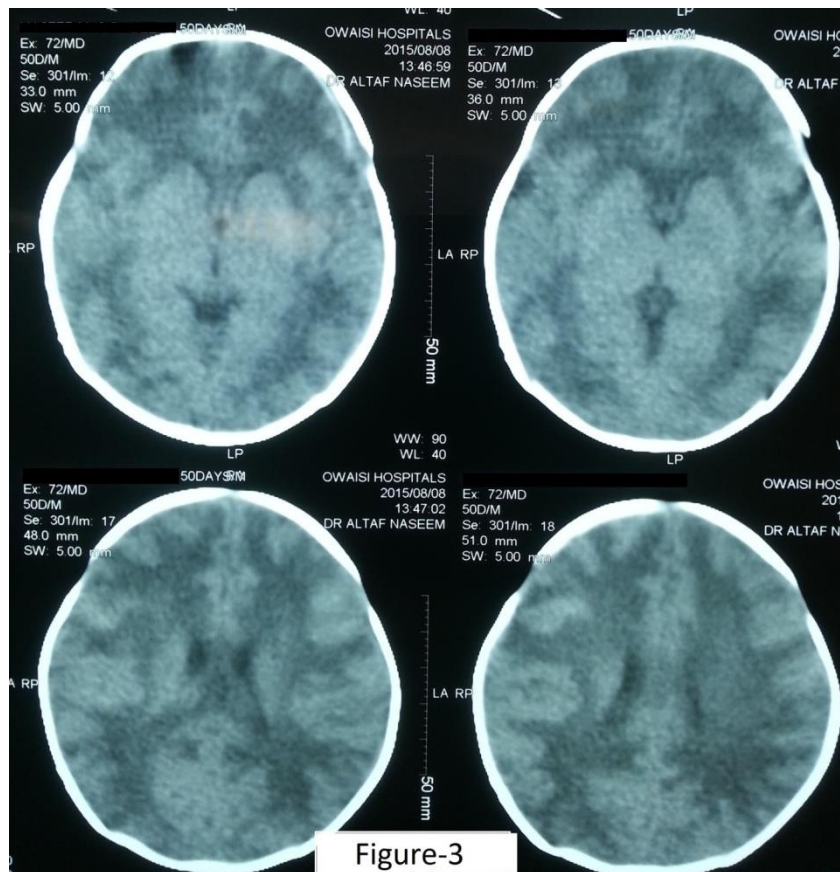


Figure-3
Fig-3: CT scan brain (plain) suggestive of generalised cerebral oedema.

DISCUSSION:

Galactosemia is a rare metabolic disorder with autosomal recessive inheritance due to deficiency of one of the three enzymes needed for galactose metabolism, classical galactosemia (type I) being the most common of the three [1], is due to galactose-1-phosphate uridyl transferase (GALT) deficiency, which converts galactose-1-phosphate and UDP glucose to UDP galactose and glucose-1-phosphate. Mutations occur at the GALT gene located on chromosome 9p13 [3]. It usually manifests in the newborn period within few days of initiation of feeding with persistent jaundice, failure to thrive, diarrhoea, vomiting, abdominal distention, hepatosplenomegaly and septicaemia (with E.coli), seizures and cerebral oedema, the incidence of cataract is 14% [4]. Histological changes in liver include fatty infiltration and inflammatory changes, portal hypertension, pseudo acinar formation and cirrhosis, it has no gender or race predilection however variants are most noted among the African population. Among the many variant's identified Duarte variant and the Los Angeles variant are common with Duarte being milder form having no long term complication [5]. Some of the known complications associated with galactosemia include Vitreous hemorrhage [6], learning problems, and language and speech deficits. Long term complications

in adults include, hypergonadotropic hypogonadism or primary ovarian insufficiency in women [7], with growth retardation and neurologic abnormalities like tremor, ataxia and dystonia. As the clinical manifestations are nonspecific it needs to be differentiated from other disorders like fructose 1-Phosphate Aldolase Deficiency (Fructose Intolerance), galactokinase (GALK) deficiency, Galactose-6-phosphate epimerase (GALE) deficiency, neonatal hemochromatosis, lactose intolerance, congenital TORCH infections. Diagnosis is usually based on newborn screening tests, in babies who do not undergo newborn screening and are suspected to have galactosemia, diagnosis is established by presence of galactose in urine gas chromatography-mass spectrometry, along with elevated levels of galactose-1-phosphate in erythrocytes and quantitative GALT enzyme assay which revealed significantly decreased levels of the enzyme, definitive diagnosis is made by gene mutation analysis. Prenatal diagnosis with amniocentesis or from the chorionic sampling can be done in high risk cases [8]. Treatment consists of elimination of galactose from the diet. Long term prognosis, mortality and morbidity depend on early diagnosis and careful management.

CONCLUSION:

We report a rare case of classical galactosemia in a fifty day old male baby, which was obscured by the concomitant presence of TORCH infection. We would like to emphasize the importance of new born screening, along with judicious workup and consideration of galactosemia as a differential diagnosis for all such cases in order to prevent its long term complications.

ACKNOWLEDGEMENTS:

Thanks to the nursing staff for helping with management of this case and the parents of this patient for their consent and cooperation.

REFERENCES:

1. Goppert F; Galaktosuriemach Milchzuckergabebeiangeborenem, familiaeremchronischem Leberleiden". *Klin Wschr*, 2000; 54: 473-7.
2. Fridovich-Keil J, Walter. Galactosemia. Scriver CR, Beaudet AL, Sly WS, Valle D; *The Metabolic and Molecular Bases of Inherited Disease*. 8th Ed. New York, NY: McGraw-Hill Medical Publishing Division; 2008; 72.
3. Elsas II, LJ, Langley S, Paulk EM, Hjelm LN, Dembure PP; A molecular approach to galactosemia. *Eur J Pediatr*. 1995; 154(7 Suppl 2):S21-7.
4. Widger J, O'Toole J, Geoghegan O, O'Keefe M, Manning R; Diet and visually significant cataracts in galactosaemia: is regular follow up necessary *J Inher Metab Dis* 2010; 33:129-132.
5. Duarte galactosemia (DG or D/G galactosemia), Minnesota Department of Health
6. Levy HL, Brown AE, Williams SE, de Juan E, Jr; Vitreous haemorrhage as an ophthalmic complication of galactosemia. *JPediatr*. 1996; 129:922-925.
7. Forges T, Monnier-Barbarino P; Premature ovarian failure in galactosaemia: pathophysiology and clinical management]. *PatholBiol (Paris)*. 2003; 51(1):47-56.
8. Fensom AH, Benson PF, Blunt S; Prenatal diagnosis of galactosaemia. *Br Med J*, 1974; 4 (5941): 386-7.