

## Ocular Features of Morning glory Syndrome in a 9-year-old Child

Théra JP<sup>1</sup>, Hughes D<sup>2</sup>, Tinley C<sup>2</sup>, Bamani S<sup>3</sup>, Traoré L<sup>3</sup>, Traoré J<sup>3</sup>

<sup>1</sup>Pediatric Ophthalmologist and Forensic Medicine Doctor, Faculty of Medicine / Institute of African Tropical Ophthalmology, Bamako (Mali)

<sup>2</sup>Pediatric Ophthalmologist, CCBRT Hospital, Dar Es Salam (Tanzania)

<sup>3</sup>Professor, Department of Ophthalmology, Faculty of Medicine / Institute of African Tropical Ophthalmology, Bamako (Mali)

### \*Corresponding author

Dr Japhet Pobanou THERA

Email: [therajaphet@yahoo.fr](mailto:therajaphet@yahoo.fr)

---

**Abstract:** Morning glory syndrome is an uncommon congenital optic disc anomaly in which the disc is enlarged and excavated with white glial tissue in the center; it is generally unilateral. It is a sight threatening disease which needs to be diagnosed early in order to manage the amblyopia that may be a big issue in this disease.

**Keywords:** ocular manifestation, morning glory syndrome.

---

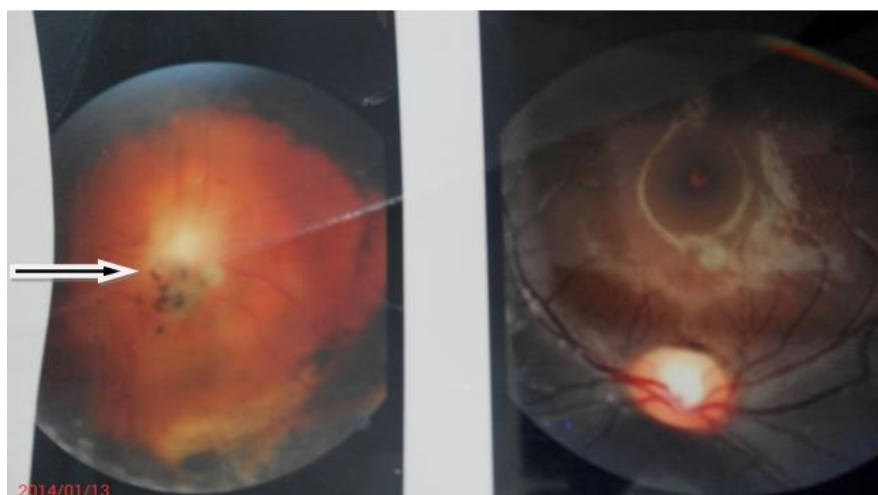
### INTRODUCTION

The term morning glory syndrome was given by Kindler because of its resemblance to the morning glory flower [1, 2]. The morning glory anomaly appears as a large, excavated, funnel-shaped disk with a prominent elevated rim or ring of peripapillary tissue sometimes associated with peripapillary pigmentary mottling [3,4]. The fundoscopic appearance of the morning glory syndrome includes 3 primary features: an enlarged, funnel-shaped excavation in the optic disc; an annulus of chorioretinal pigmentary changes that surrounds the optic disc excavation; and a central glial tuft overlying the optic disc [5].

### CASE REPORT

A 9-year-old school girl was brought to our office by her mother for unilateral blurred vision. No

pathologic personal and family history was found. Best corrected visual acuity was 6/6 in the right eye and light perception in the left eye. Anterior segment biomicroscopy was normal both eyes. The intra-ocular pressure was 12 mmHg for each eye. After dilation with mydriatic eye drop, the fundoscopic examination revealed the following features in the right eye: an enlarged pallid optic disc with a funnel-like excavation including a fibroglial tissue at the center. Many retinal vessels emerged radially from the periphery of the disc like bicycle wheel spokes. A peripapillary chorioretinal pigment was noted at the temporal side. There was no macular reflex. The child was referred to an internal medicine specialist to look for associated anomalies but nothing was found.



**Fig-1: Fundus photos showing morning glory disc in the right eye (arrow) and a normal disc in the left eye.**

---

## DISCUSSION

This case report illustrates the ocular and isolated features of morning glory syndrome, a rare congenital anomaly of the papilla. Although it is often an isolated ocular abnormality, it may be associated with systemic abnormalities [6]. Morning glory syndrome is a non-hereditary and usually unilateral optic nerve disease demonstrating increased excavation, radial retinal vessels with glial tissue and a funnel-shape arrangement [7, 2]. In the case presented here, the patient had a unilateral blindness. As found by many authors, morning glory syndrome involves oftentimes amblyopia [8]

## CONCLUSION

The morning glory syndrome is a relatively rare congenital optic disc abnormality generally isolated but sometime associated with systemic features. In some instance it may be accompanied with severe visual disturbances. It must be diagnosed very early in order to minimize the risk of amblyopia.

## REFERENCES

1. Giuseppe G; Morning glory syndrome. Clinical and electrofunctional study of three cases. *Br J Ophthalmol*, 1986; 70: 229-236.
2. Kindler P; Morning glory syndrome; Unusual congenital optic disk anomaly. *Am J Ophthalmol*, 1970; 69:376-384.
3. Martyn LJ, Di George A; Selected eye defects of special importance in pediatrics. *Pediatr Clin North Am*, 1987; 34:1517-42.
4. Benjamin C, Onwochei, MD, John WJ, Bronwyn B, Kimberly C, Couture, BS et al.; Ocular Colobomata. *Surv ophthalmol*, 2000; 45 (3):175-193.
5. Auber AE, O'Hara M; Morning glory syndrome. MR imaging. *Clin Imaging*, 1999; 23:152-158.
6. Anahid S, Esmail J, Afshin BH; Morning glory syndrome associated with multiple sclerosis. *Iran J Neurol*, 2014; 13(3): 169-172.
7. Ahmet A, Gulengul A, Sevda AK, Osman OO, Suat FA; Morning glory disc Anomaly in a case with Down syndrome. *BMC Ophthalmol*, 2014; 14:48.
8. Humberto C, Abraham OB, Alejandro ML, Jesus MH; Morning Glory Disc Anomaly, A Report of a Successfully Treated Case of Functional Amblyopia. *J Clin Dgn Res* 2015; 9(10):1-6.