

Congenital Rubella Syndrome in a Term Male Neonate with Patent Ductus Arteriosus and Bilateral Nuclear Cataracts: A Case Report

**Dr. S. Pratap Rao¹, Dr. Swathi Chacham^{2*}, Dr. U.Narayan Reddy³, Dr. J.Ravi kiran⁴,
Dr. Soumya anumula⁵, Dr. Faraaz Adil⁶, Dr. Burli Prithvi⁷, Dr. Naila Mazhar⁸**

¹MD Paediatrics, Professor, Department Of Paediatrics, Deccan College Of Medical Sciences, Princess Esra Hospital, Hyderabad 500 002, Andhra Pradesh, India.

²MD Paediatrics, DM Neonatology, Assistant Professor, Department Of Paediatrics, Deccan College Of Medical Sciences, Princess Esra Hospital, Hyderabad 500 002, Andhra Pradesh, India.

³MD Paediatrics, DCH, DNB paediatrics, Head Of The Department And Professor, Department Of Paediatrics, Deccan College Of Medical Sciences, Princess Esra Hospital, Hyderabad 500 002, Andhra Pradesh, India.

^{4,5,8}(MD Paediatrics) Junior Resident, Department Of Paediatrics, Deccan College Of Medical Sciences, Princess Esra Hospital, Hyderabad 500 002, Andhra Pradesh, India

^{6,7}Junior house officer, Department Of Paediatrics, Deccan College Of Medical Sciences, Princess Esra Hospital, Hyderabad 500 002, Andhra Pradesh, India.

***Corresponding author**

Dr. Swathi Chacham

Email: swathi.m.lahiri@gmail.com

Abstract: Transplacental transmission of rubella virus leads to Congenital Rubella Syndrome. It is comprised of congenital cardiac defects (most commonly patent ductus arteriosus), cataracts and sensorineural hearing loss. While prematurity and intra uterine growth retardation are frequent accompaniments of congenital rubella syndrome, at times birth weight can be normal. The possibility of fetal anomalies due to rubella virus is highest in the first 12 weeks of gestation, which decreases thereafter. PDA is highly prevalent in premature neonates, where as its presence in term neonates signifies either intra uterine infection or genetic disease. A 39weeks, 3200grams, appropriate for gestational age, male neonate was born by vaginal delivery with normal APGARs. The neonate presented with respiratory distress, precordial activity and cardiac murmur on 4th day of life. Hence, congenital heart disease was considered and echocardiography revealed patent ductus arteriosus. While PDA is common in premature neonates, it is a rare manifestation in term newborn babies. The neonate also had bilateral nuclear cataracts in the eyes, implying congenital rubella syndrome and was investigated for the same. Other systemic findings like bilateral cryptorchidism, hepatosplenomegaly and thrombocytopenia were also evident. In addition there was unconjugated hyperbilirubinemia and elevated transaminases. There were no intra cranial calcifications in neurosonogram. Congenital rubella syndrome was confirmed as rubella IgM levels in both mother and neonate were elevated. The neonate received decongestive therapy for patent ductus arteriosus. We report a term, male appropriate for gestational age neonate with PDA and bilateral nuclear cataracts along with elevated rubella IgM levels confirming congenital rubella syndrome.

Keywords: Congenital rubella syndrome, congenital cataract, congenital heart disease, neonate, Patent Ductus Arteriosus, TORCH infection.

INTRODUCTION

Congenital Rubella Syndrome (CRS) is a clinical entity, caused by primary infection with rubella virus in the first trimester of pregnancy. It has a varied spectrum of presentation which ranges from insignificant, unnoticed viremia to recurrent abortions, still births and severe congenital foetal anomalies.

CRS was first described as a benign contagious disease in 1866 by Veale, a Scottish physician [1]. Later, Sir Norman Gregg defined congenital cataracts, deafness and heart defects as the classic triad of CRS[2]. The nature and severity of

congenital defects is determined by the period of gestation at the time of infection [3]. Viremia occurring before 11 weeks of gestation results in both deafness and cardiac malformations, the prime manifestations of CRS. Isolated deafness occurs when the fetus is infected between 13-16 weeks of gestation. On the other hand, the developmental defects are infrequent when the maternal infection takes place after 16weeks of gestation. Captivatingly, majority of the intrauterine infections follow this method of transmission [3]. Despite the fact that the definite teratogenic mode of congenital rubella infection remains undisclosed, replication of the virus in the fetal cells during

organogenesis might be contributory [4]. The most commonly prevalent defects include central or sensory neural deafness (80%) cataracts and microphthalmia (60-70%) followed by patent ductus arteriosus (PDA) and hepatosplenomegaly (50-60%) [5,6,7,8]. Even though rare, CRS ranks second among the conditions causing non-traumatic cataracts and blindness in children, which is essentially preventable.

Although, PDA is a common cardiac defect in premature neonates, it is less prevalent in term newborns. In premature neonates of less than 28 weeks gestation, incidence of PDA is very high(65%). Contrarily, in term neonates, it is reported to occur with a frequency of 1 in 2,000 births, which contributes to 5%-10% of all congenital heart disease [9]. The Functional closure of PDA takes place by 12-18 hours and anatomical closure by 2-3 weeks [9]. Persistence of ductus in a premature neonate past 3months and in a term baby beyond one year is termed as persistent patency of ductus arteriosus, with limited possibility of spontaneous closure later on [9]. Genetic conditions (trisomy 21 & halt oram syndrome) and intra uterine infections are the prime causes of patent ductus arteriosus in a term neonate. Infrequently maternal use of valproic acid and birth at high altitude can result in PDA. In CRS, PDA occurs equally in both the genders

while it affects females more than males in sporadic cases (2:1).

CASE REPORT

A 39weeks, 3200grams male neonate was born to a second gravida by spontaneous vaginal delivery. There was history of maternal upper respiratory tract infection during the first trimester, though the rash was unobserved. There were no other antenatal complications. Likewise, history of drug intake (valproate) was not forthcoming. The neonate did not require any resuscitation after birth and the APGARs were normal. Maternal TORCH profile done in view of previous miscarriage, showed elevated rubella IgM levels.

On 4th day of life, the neonate was admitted with respiratory distress requiring supplemental oxygen. Subcostal and intercostal retractions were also evident. On examination pre-cardial activity, bounding peripheral pulses, tachycardia, pan systolic murmur and hepatosplenomegaly were noted, suggesting congenital heart defect, possibly PDA. Co-incidentally, the ophthalmological examination revealed bilateral nuclear cataracts (as shown in fig-1A and 1B) alongside cryptorchidism implying congenital rubella syndrome (CRS) for which the neonate was investigated.

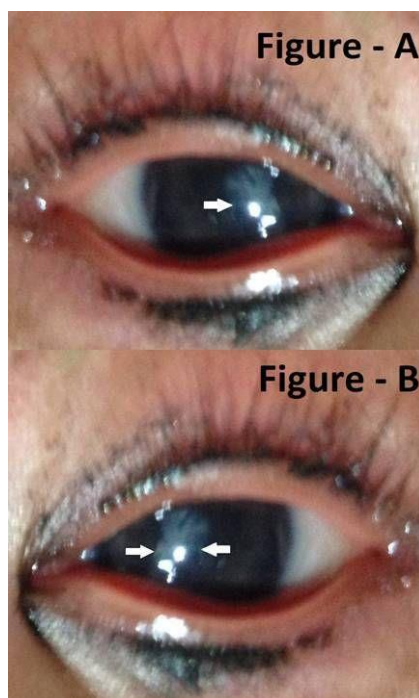

Fig-1A & 1B: Bilateral nuclear cataracts, as shown with arrows.

Investigations on fourth day of life disclosed thrombocytopenia, positive sepsis screen alongside unconjugated hyperbilirubinemia and raised transaminases. Chest radiograph unveiled cardiomegaly (as shown in figure-1C) and ECG revealed RSR Pattern with ST segment depression (as in figure-1D).

Echocardiography demonstrated levocardia with situs solitus, normal atrio ventricular and ventriculo arterial concordance. However, there was 3mm PDA showing left to right shunt on echocardiogram. Contrarily, intracranial calcifications were absent on skull radiograph and neurosonogram. Cochlear deafness in neonatal

period was ruled out as the oto-Acoustic emission (OAE) was normal in both ears. Nevertheless, periodic follow up for hearing assessment is advised as sensorineural deafness can uncover later. The neonate's rubella IgM levels were elevated, confirming CRS. The

infant received supportive and symptomatic treatment and was discharged on decongestive treatment for PDA. B scan of the eyes was normal and the infant is planned for cataract surgery at 3 months of age.

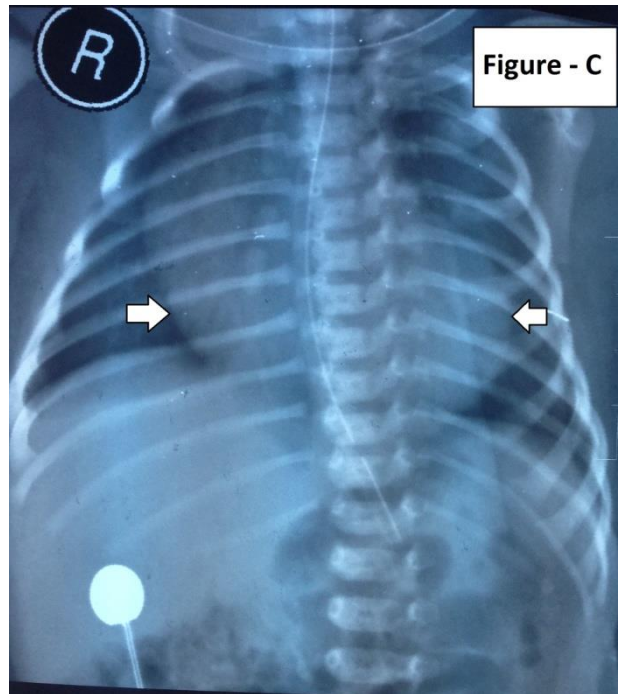


Fig--1C: Chest Radiograph depicting cardiomegaly, as shown with arrows.

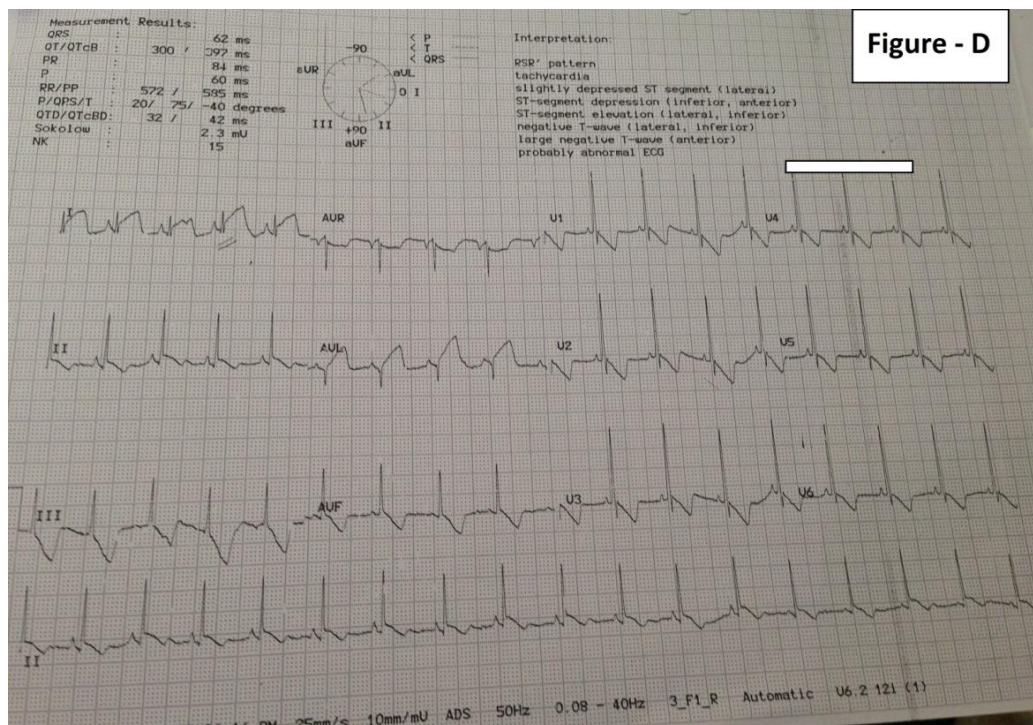


Fig--1D: Electrocardiogram showing RSR' pattern, ST depression.

DISCUSSION

CRS presents with diverse systemic manifestations as a result of persistent fetal infection

with rubella virus. Systemic involvement extends from neonatal acute multi organ dysfunction to sensorineural deafness coupled with progressive encephalopathy in

infancy and childhood [6]. The advent of rubella vaccine has led to significant reduction in the prevalence of fetal rubella infection, nevertheless CRS still exists. The severity of the anomalies depends on the teratogenicity of the virus and the gestational period at the time of exposure [6]. The fetal involvement with rubella virus has a bimodal distribution, explicitly one prior to 12 weeks and the other subsequently after 36 weeks of gestation. Infection in the early gestation leads to higher incidence of fetal anomalies (less than 12 weeks- more than 80%, 13-14 weeks-54%, and at the end of second trimester-25%) as compared to exposure in the later gestation. Placental resistance to viral invasion decreases during second trimester with the maturation of cytotrophoblast. However, cytotrophoblastic apoptosis during the third trimester facilitates viral re-transmission. Interestingly, the occurrence of ophthalmological and cardiovascular malformations decline, on the other hand prevalence of sensorineural hearing loss is augmented as the gestation progresses. Physiological immunocompromised status of the fetus enables viral transmission which interferes with the process of organogenesis resulting in major congenital defects [6].

Although CRS often results in intrauterine growth retardation and prematurity, infrequently the neonate may have normal intrauterine growth and birth weight as in the index case.

Among the various congenital defects, central hearing loss is most often reported [6]. Remarkably, severe hearing loss is more frequently encountered than milder forms. Hearing loss alone without other anomalies can point to CRS [6]. Nuclear cataract is pathognomonic ocular presentation of rubella, whereas congenital glaucoma is unusual [7, 10, 11]. The index case exhibited bilateral nuclear cataracts correspondingly (as shown in figure A and B). Viral replication in the developing fetal lens leads to such nuclear cataract. Lack of mesodermal absorption at the angle of anterior chamber or absence of differentiation of Schlemm's canal might be contributory to congenital glaucoma. This in turn results in raised intraocular pressure and corneal clouding which is frequently noted in infancy and childhood as compared to neonatal period. Microphthalmia and salt pepper retinopathy are amongst the additional ophthalmological abnormalities noticed in CRS. Patent ductus arteriosus (PDA), peripheral pulmonary stenosis and ventricular septal defect (VSD) are the distinct cardiovascular defects observed in CRS. Ophthalmological anomalies and congenital heart defects frequently co-exist [6,10,11]. Correspondingly, this index neonate presented with PDA alongside nuclear cataracts.

Systemic findings in CRS include hematological (thrombocytopenia and anemia), dermatological (rubelliform rash and blue-berry

muffins), intra cranial/basal ganglia calcifications, hepatosplenomegaly and metaphyseal lucencies in long bones[8]. Occasionally, neurological impairment can occur in the form of meningo-encephalitis, microcephaly and mental retardation. Rarely, thymic hypoplasia, endocrinal lesions (cryptorchidism, diabetes mellitus and thyroid abnormalities), hypogammaglobulinemia and polycystic kidney disease are also reported in CRS [8]. The present case had chryptorchidism, although the other endocrinal abnormalities were not evident then. Chronology of these defects can vary from a few months to years. Transplacental viremia near term gestation coupled with inadequate maternal antibodies attributes to neonatal rubella.

Diagnostic modalities for CRS consists of identifying rubella virus (in neonatal oropharyngeal secretions and urine), retrieving rubella specific IgM antibodies either in the neonatal blood(or cord blood) and periodic monitoring of raised rubella IgG titers [13]. Index neonate revealed elevated IgM levels, thus confirming CRS.

The mainstay of management of CRS includes supportive care alongside corrective measures for different congenital abnormalities, to the extent possible. The index neonate received supportive care as well as decongestive therapy for PDA and the cataract excision was planned in follow up.

Immunization of all susceptible adults with rubella vaccine is vital in preventing CRS, hence forth reducing its sequelae. To avert fetal infection, post rubella vaccination, pregnancy must be deferred for three months.

CONCLUSION

A term male neonate with patent ductus arteriosus and bilateral nuclear cataracts implying congenital rubella syndrome. Presence of patent ductus arteriosus in a term neonate alongside other infrequent systemic findings and positive rubella serology makes this case distinct.

ACKNOWLEDGMENTS

Thanks to Dr. Dina Fatima Yazdani for formatting and thanks to the nursing staff for their help in managing this rare case.

REFERENCES

1. Veale H; history of an epidemic of Rothelin with observations on its pathology. *Edin Med J*, 1866; 12: 404-414.
2. Gregg NM; Congenital cataract following German measles in the mother. *Trans Ophthalmol Soc Aust*, 1941; 3: 35-46.
3. enkins KJ, Correa A, Feinstein JA, Botto L, Britt AE, Daniels SR, Webb CL; Noninherited risk

-
- factors and congenital cardiovascular defects: Current knowledge: a scientific statement from the American Heart Association Council on Cardiovascular Disease in the Young; endorsed by the American Academy of Pediatrics. *Circulation*, 2007; 115(23): 2995–3014.
4. Oliveira SAD, Camacho LAB, Pereira ACDM, Bulhões MM, Aguas AF, Siqueira MM; Performance of rubella suspect case definition: implications for surveillance. *Rev Saude Publica*, 2006; 40(3): 450–456.
 5. Robinson JL, Lee BE, Preiksaitis JK, Plitt S, Tipples GA; Prevention of congenital rubella syndrome—what makes sense in 200? *Epidemiol Rev*, 2006; 28(1): 81–87.
 6. Givens KT, Lee DA, Jones T, Ilstrup DM; Congenital rubella syndrome: Ophthalmic manifestations and associated systemic disorders. *Br J Ophthalmology*, 1993; 77(6): 358–363.
 7. Boger WPIII; Late ocular complications in congenital rubella syndrome. *Ophthalmology*, 1980; 87(12): 1244–1252.
 8. Numazaki K(1), Fujikawa T; Intracranial calcification with congenital rubella syndrome in a mother with serologic immunity. *J Child Neurol*, 2003; 18(4): 296–297.
 9. Schneider DJ, Moore JW; Patent ductus arteriosus. *Circulation*, 2006; 114(17): 1873–1882.
 10. Reddy UN, Chacham S, Rao JN, Priya AV, Mahmood A, Nagasravani J, Khan A; A rare case of buphthalmos and bilateral nuclear cataracts in a neonate with congenital rubella syndrome. *Journal of Evolution of Medical and Dental Sciences*, 2014; 3(25): 6965–6966.
 11. Vijayalakshmi P, Rajasundari TA, Prasad NM, Prakash SK, Narendran K, Ravindran M, Brown DW; Prevalence of eye signs in congenital rubella syndrome in South India: A role for population screening. *Br J Ophthalmol*, 2007; 91(11): 1467–1470.
 12. Wong LM, Medrano J; Real-Time PCR for mRNA quantification. *Bio- Techniques* .2005; 39(1): 75–85.
 13. Surveillance Guidelines for Measles, Rubella and Congenital Rubella Syndrome in the WHO European Region, World Health Organization, 2009; 1–48.