

Giant Cystic Leiomyoma Masquerading As Ovarian Tumour- Case Report

Dr Reshmy J R¹, Professor BhartiMisra², Dr Rahul Rai³
^{1,2,3}MKCG Medical College, Berhampur, Orissa, 760004, India

***Corresponding author**

Dr Reshmy J R

Email: dreshmyjr@gmail.com

Abstract: Cystic degeneration of uterine leiomyoma is a rare complication of leiomyoma that may present with clinical and imaging findings resembling ovarian mass and the final diagnosis is based on the operative and histological confirmation. Here we report a rare case of giant pedunculated leiomyoma which presented as ovarian neoplasm on clinical examination, sonography and computed tomography (CT). A 50yr old postmenopausal woman presented with complaints of lower abdominal distension and pain. On examination, a predominantly cystic mass with solid areas in between corresponding to 32 weeks gravid uterus was palpable more towards the right side. USG and CT scan revealed a predominantly cystic mass with solid components adherent to fundus and posterior surface of uterus probably arising from the right adnexa. A preoperative diagnosis of ovarian tumour was suspected. Proceeded with staging laparotomy as per protocol. Laparotomy revealed multiple leiomyomas, the largest one was of size of 30 X 28 cm size which had undergone cystic degeneration. Proceeded with Total abdominal hysterectomy and bilateral salpingo-oophorectomy. Histology revealed leiomyoma with cystic degeneration. Postoperative period was uneventful. A pedunculatedsubserosal uterine leiomyoma with cystic degeneration can often be mistaken for an ovarian neoplasm especially in a postmenopausal woman hence should always be considered in the differential diagnosis while evaluating an adnexal mass.

Keywords: Leiomyoma, Cystic degeneration, Ovarian neoplasm, Staging Laparotomy.

INTRODUCTION

Uterine leiomyomas are the most common benign smooth muscle tumours of the uterus predominantly developing in 20% to 40% of women during reproductive age and more than 50% of women above 40 years of age [1,2]. The prevalence of these estrogen dependant tumours increase during reproductive period and decreases after menopause and before puberty [3]. More than 50% of leiomyomas are asymptomatic and when symptoms arise it may be in the form of menstrual disturbances, infertility, pressure symptoms, pain or recurrent pregnancy loss. The size of leiomyomas varies from microscopic to giant size which is rare[4]. Typical appearances of leiomyomas are easily recognised on imaging. However, the atypical presentations that follow degenerative changes can lead to diagnostic dilemma [5]. Here we report such a rare case which mimicked ovarian tumour clinically and radiologically but was diagnosed as giant leiomyoma with cystic degeneration following laparotomy.

CASE REPORT

A 50 year old postmenopausal woman presented with history of abdominal distension and dull aching lower abdominal pain since 2 years. There was no significant past, family or personal history. On abdominal examination, there was a predominantly cystic mass with solid areas in between of size 30 x 20

cm corresponding to 32 weeks gravid uterus occupying the hypogastrium, umbilical region reaching upto the epigastrium. The mass was more towards the right side, had illdefined margins, irregular surface, restricted mobility on all sides and seemed to arise from the pelvis. On pervaginal examination, uterus was not separately palpable and the same mass was felt through all the fornices. There was no nodularity in pouch of Douglas. It was difficult to ascertain the origin of the tumour clinically. On ultrasonogram(Fig 1), there was a predominantly cystic mass 28 X 22 cm with multiple thin internal septationswith solid areas in between adherent to fundus of the uterus. Doppler study revealed no marked vascularity inside the mass. Ovaries could not be separately visualised. CT scan of the abdomen and pelvis revealed a large well circumscribed mass 30 X 20 X 18 cm with thin internal septations arising from the right adnexa. There was no ascites, regional or distant metastasis. The results of routine laboratory analysis including Complete blood count, serum electrolytes, liver and renal function tests and tumour markers were within normal limits. In the light of clinical examination, sonographic and laboratory analysis, a primary ovarian neoplasm was suspected and we proceeded with staging laparotomy.

Abdomen was opened with a midline vertical incision. There was a predominantly cystic mass of 30

X 20 X 15 cm seen arising from uterine fundus(Fig 2). There were multiple leiomyomas arising from uterus. Uterus enlarged to 14 weeks size. Ovaries and adnexa on both sides were visualized and found normal. There was minimal ascites and other intraabdominal organs were found normal. Proceeded with total abdominal hysterectomy with bilateral salpingo oophorectomy. Gross pathologic examination revealed a giant mass which was multiloculated predominantly cystic of size 28 X 20 X 10 cm (Fig 3) with cut section showing yellowish material showing evidence of degeneration and multiple smaller fibroids(Fig 4). Microscopic examination revealed leiomyoma with degenerative changes. There were interlacing fascicles of smooth muscle cells and fibrous tissue amidst marked edema. There was evidence of focal hyalinization and cystic degeneration. There was no nuclear atypia or increased mitotic count (Fig 5). The final diagnosis was giant leiomyoma uterus with marked cystic degeneration.

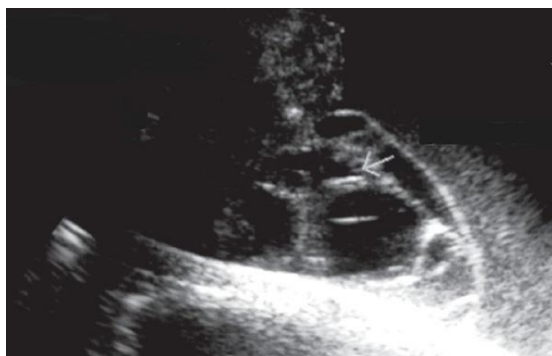


Fig-1: Ultrasonogram showing cystic mass with septations.

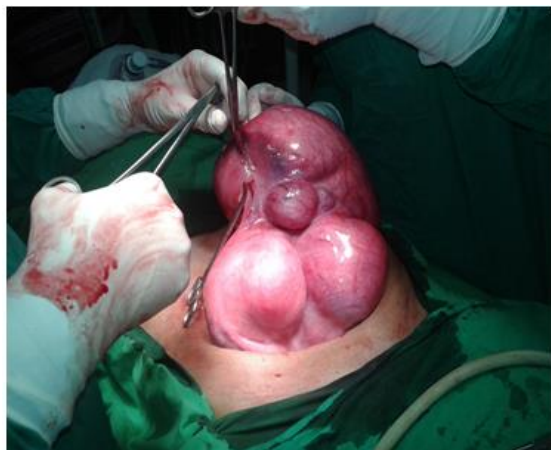

Fig: 2 Intraoperative finding of multiple leiomyoma uterus

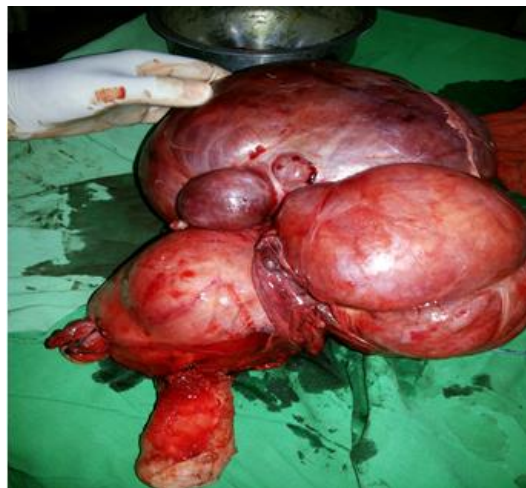

Fig-3: Gross specimen of TAH with multiple leiomyoma. The largest one being 30 X 28 cm.

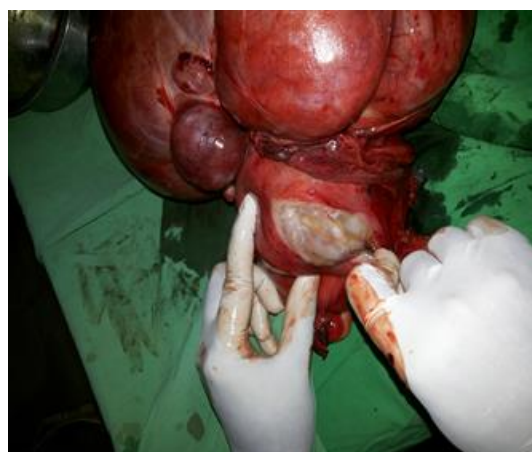


Fig-4: Cut section of the specimen revealing cystic degenerated material.

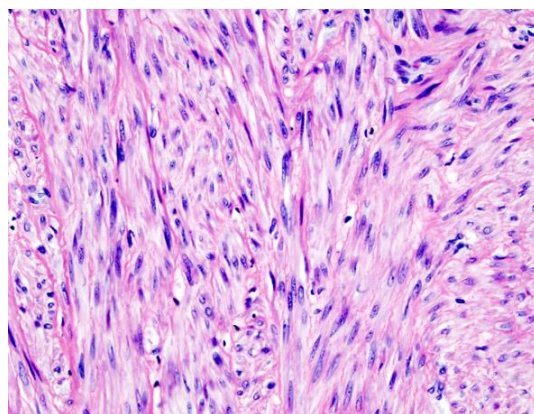


Fig-5: Histopathology slide revealing leiomyoma.

DISCUSSION

The terminology uterine fibroid is a misnomer, the correct term should be leiomyoma that is, a benign tumour arising from smooth muscles of uterus surrounded by a pseudocapsule[2,5]. Leiomyoma arises from a single progenitor myocyte. Leiomyomas are the most common benign tumours in the females, typically seen in the reproductive age group. More than 50% of

tumours are asymptomatic but when symptomatic they present with menstrual abnormalities, infertility, recurrent pregnancy loss, pressure symptoms and pain. Symptoms depend mainly on the location of fibroid rather than its location. Submucosal fibroids being more symptomatic than intramural or subserosal. These are estrogen dependent tumours which increase in size during pregnancy and regress during climacteric and puerperal periods[2]

Leiomyomas most commonly involve the uterine corpus, but may also occur in the cervix or broad ligament. According to their location, leiomyomas are classified as submucosal (projecting into the endometrial canal), intramural (within the myometrium) or subserosal (underneath the serosa)[6]. As leiomyomas grow in size, they outgrow the blood supply as the blood supply is mainly from the periphery, resulting in various types of degenerations. The various types of degenerations include hyaline, cystic, calcareous, fatty, carneous and sarcomatous variety. Hyalin degeneration is the most common type (60%) followed by cystic degeneration. Sarcomatous changes are very rare [7].

The preferred imaging modality for the initial evaluation of leiomyoma is ultrasonography because it is the least invasive and the most cost effective. The relative echogenicity of leiomyomas depends on the ratio of fibrous tissue to smooth muscle, the extent of degeneration and the presence of dystrophic calcification [8]. Leiomyomas usually appear as well circumscribed rounded hypoechoic solid lesions in the myometrium in USG. Presence of degenerative changes and calcification cause diagnostic confusion [9]. Pedunculated lesions may be mistaken for ovarian tumour. The differentiation can be done by the demonstration of vascular pedicle or recurrent shadowing sign of leiomyoma. CT is usually not the preferred primary modality for initial evaluation. It is usually used only when there is confusion in diagnosis. The findings suggestive are associated focal dense solid masses, uterine contour deformity and amorphous calcification inside the uterine mass, but these findings are seen only in 10% of patients [10]. MRI is better than CT in that it may show a vascular pedicle or its attachment to the uterus and show the characteristic hypointense T1 and T2 signals of non-degenerated leiomyomas [7].

Our case revealed the two pitfalls of sonography and CT. The first was the failure in demonstration of atrophic ovaries in a postmenopausal woman and the next was the failure to demonstrate a

vascular pedicle. Also the predominant cystic nature of the lesion led to the presumptive diagnosis of ovarian tumour. The final pathological diagnosis however revealed a large leiomyoma arising from the uterus and showing extensive evidence of cystic degeneration.

CONCLUSION

In conclusion, leiomyoma uterus can have a spectrum of presentations and the rare presentations can often cause clinically confusing scenarios. Although fibroids usually have a characteristic USG appearance, degenerating fibroids can have variable patterns and pose diagnostic challenges. However, clinical and USG correlation, together with a knowledge of the variable USG appearances of degenerating fibroid will lead on to the correct diagnosis. A pedunculated subserosal uterine leiomyoma with extensive cystic degeneration may mimic an ovarian tumour.

REFERENCES

1. Padubri VG, Daftary SN; Textbook of gynaecology, 16th edition, Elsevier publishers, New Delhi, 2015, 391-408.
2. Fogota ML, Jain KA; Degenerating cystic uterine fibroid mimics an ovarian cyst in a pregnant patient. *J Ultrasound Med*, 2006; 25(5): 671-674.
3. Courbiere B, Carcopino X; *GynecologicObstetrique. Vernazobres-Greco; Fibromesuterins*, 2006; 18: 359-365.
4. Jonas HS, Masterson B; Giant uterine tumours. *Obstet Gynecol*. 1977; 50(1): 2-4.
5. Murase E, Siegelman ES, Outwater EK, Perez-Jaffe LA, Tureck RW; Uterine Leiomyomas: Histopathologic Features, MR Imaging Findings, Differential Diagnosis, and Treatment 1. *Radiographics*, 1999; 19(5): 1179-1197.
6. Low SC, Chong CL; A case of cystic leiomyoma mimicking an ovarian malignancy. *Ann Acad Med Singapore*, 2004; 33: 371-374.
7. Mayer DP, Shipilov V; Ultrasonography and magnetic resonance imaging of uterine fibroids. *ObstetGynecolClin North Ann*, 1995; 22(4): 667-725.
8. Wladimiroff J; *Ultrasound in obstetrics and gynecology*. Elsevier, 2009; 303-306.
9. Baltarawich OH, Kurtz AB, Pennel RG, Needleman L, Vilaro MM, Goldberg BB; Pitfalls in the sonographic diagnosis of uterine fibroids. *AJR AM J Roentgenol*, 1988; 151(4): 725-728.
10. Bennet GL, Slywotzky CM, Giovanniello G; Gynecologic causes of acute pelvic pain: Spectrum of CT findings. *Radiographics*, 2002; 22(4): 785-801.