

**Primary non hodgkins lymphoma of mandible: a rare entity.****Dr Channabasappa kori<sup>\*1</sup>, Dr Jeevan Vishnoi<sup>2</sup>, Dr D Prashant Kumar<sup>3</sup>, Dr Shashi singh Thakur<sup>4</sup>, Dr Sameer Gupta<sup>5</sup>, Dr. Vijay Kumar<sup>6</sup>, Dr Saumya Shukla<sup>7</sup>**<sup>1,2,3,4</sup> Senior resident, Dept of surgical oncology, King George's Medical University, Lucknow<sup>5</sup> Assistant professor, Dept of surgical oncology, King George's Medical University, Lucknow.<sup>6</sup> Associate Professor, Dept of Surgical Oncology, King George's Medical University,<sup>7</sup> Assistant professor, Dept of pathology, RMLIMS, Lucknow.**\*Corresponding author**

Dr Channabasappa kori

Email: [channabasappakori@gmail.com](mailto:channabasappakori@gmail.com)

---

**Abstract:** Non Hodgkin lymphoma is a rare primary malignancy in the head and neck region. Head and neck is the second most common site for the extra-nodal lymphoma, next to gastrointestinal tract. Nasopharynx, tonsil, nose, paranasal sinuses, orbit and salivary glands are the other sites affected in head and neck region. Involvement of the oral cavity is uncommon. Among the jaw bones, maxilla is affected more commonly than the mandible. Primary NHL arising from mandible is extremely uncommon. To the best of our knowledge, very few cases of primary NHL arising from are reported in the literature.**Keywords:** Non Hodgkin lymphoma, mandible, head and neck.

---

**INTRODUCTION**

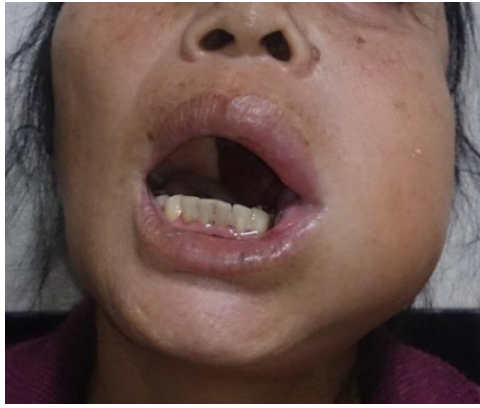Non Hodgkin lymphomas [NHL] are a group of diverse malignancies and have great tendency to affect various organs. Extra nodal lymphoma [ENL] accounts for 20 -30% cases. Primary non-Hodgkin's lymphoma (NHL) of the bone is rare, accounting for <5%. In 1963, the term primary lymphoma of bone was introduced by Ivins and Dahlin. The etiology is unknown even though virus and immuno-suppression are associated. Extra nodal primary non Hodgkin's lymphoma of the oral cavity is a rare entity. Clinical features of lymphoma of the oral cavity are non specific. Prognosis of NHL is excellent in localized disease, whereas unfavorable in disseminated disease. Lymphomas arising in bone may be effectively managed by chemotherapy alone. Case details:

A 40-year-old female patient presented with history of swelling in the left lower jaw at the site of extraction of tooth since 2 months. Following extraction she noticed a small growth which was insidious in onset and gradually increased to the present size at the site of extraction.

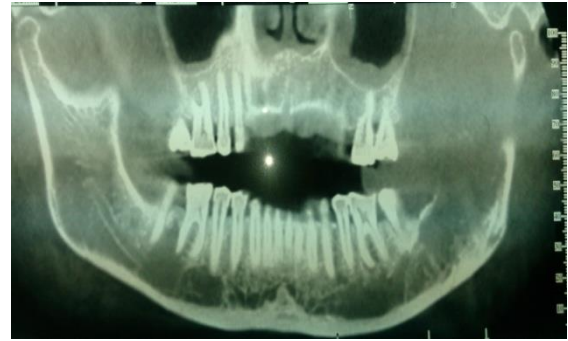
Intraoral examination showed lobulated, erythematous lesion was found to be present in left alveolar region, which extended beyond the occlusal surfaces of teeth both buccally and palatally, measuring 5 cm ×4 cm in size [fig 1A]. External examination revealed presence of swelling in the left mandibular region measuring 8x8cm [fig 1B]. No obvious cervical adenopathy. Orthopantomogram (OPG) revealed with

areas of radiolucency and lytic lesion in the region of body and ramus of left mandible [fig 2]. Contrast enhanced computed tomography scan showed an ill-defined heterogeneous lesion involving body and ramus of mandible [fig 3]. Incision biopsy of the swelling revealed sheets of abnormally large lymphoid cells with high nucleus: cytoplasmic ratio, coarse chromatin, and inconspicuous nucleoli with abnormal mitotic [fig 4a]. The features were suggestive of large cell lymphoma of B-cell type. Immuno-histochemistry revealed positive CD20 [fig 4b], LCA, and CD3, CK were negative, which confirmed the diagnosis of diffuse large B-cell variant of non Hodgkins lymphoma. Metastatic workup was negative.

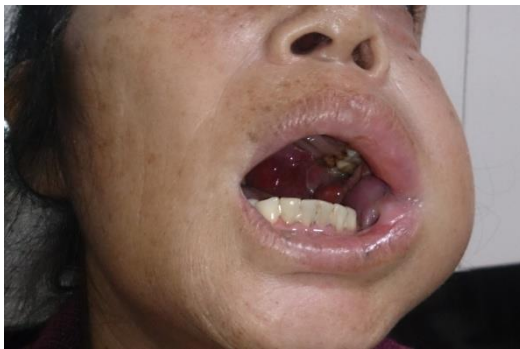Patient was started on chemotherapy consisted of classical CHOP regimen which comprised of using cyclophosphamide, doxorubicin (hydrodoxorubicin), vincristine (oncovin), and prednisolone. At the end of two cycles, the swelling started regressing in size and completely disappeared after six cycles (complete response) (fig 5a & 5b). Patient is disease free on 8 months of follow up.



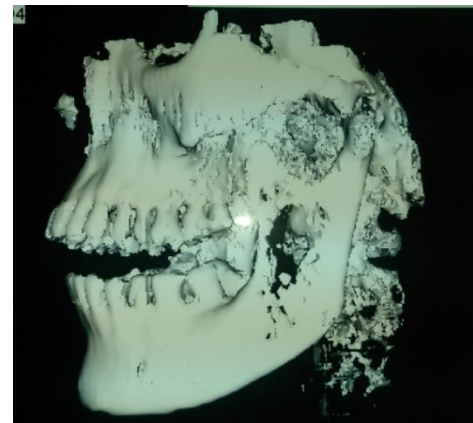
**Fig-1a:** Intra oral examination lobulated, erythematous lesion was found to be present in left alveolar region



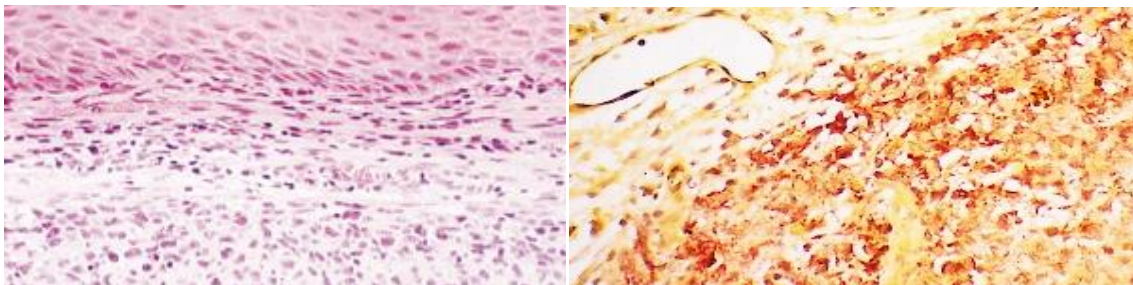
**Fig 2a:** OPG revealed with areas of radiolucency and lytic lesion in the region of body and ramus of left mandible.



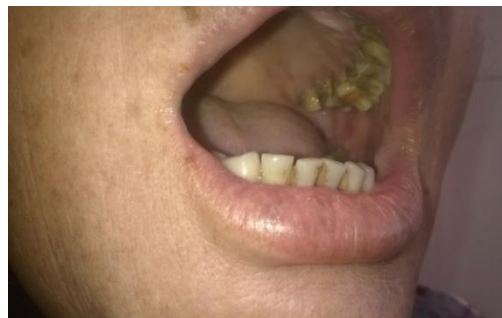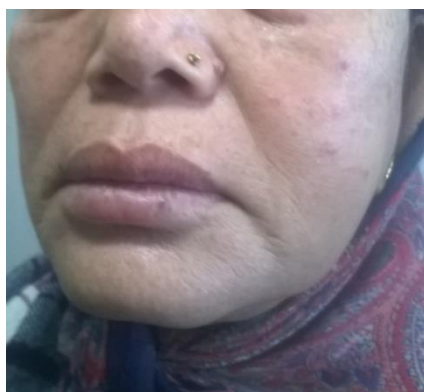**Fig-1b:** clinical photograph showing the presence of swelling in the left mandibular region measuring 8x8cm



**Fig-2b:** CT scan showed an ill-defined heterogeneous lesion involving body and ramus of mandible.



**Fig-3a;** Photomicrography revealed sheets of abnormally large lymphoid cells with coarse chromatin, and inconspicuous nucleoli suggestive large B cell lymphoma.



**Fig-4a & 4b:** Post chemotherapy [6 cycles of CHOP regimen] showed complete response to chemotherapy

## DISCUSSION

Non hodgkin's lymphoma comprises of a heterogeneous group of neoplasm arising from lymphoid tissue with a spectrum of behavior ranging from relatively indolent to highly aggressive disorder. Most of NHL in head and neck is B-cell lineage. NHL arises primarily within lymph nodes but approximately 24% of all cases affect extra nodal locations [1, 2].

Typical locations for extranodal NHLs are the stomach, bowel, lung, orbital tissue, sinuses, thyroid, tonsil, salivary glands, breast, testis and kidney. Waldeyer's ring is second to the gastrointestinal tract in the incidence of extra nodal NHL, but primary lymphomas of the oral cavity are uncommon [3, 4]. In the oral cavity it includes palate, gingiva, tongue, cheek, floor of the mouth and lips as primary sites in approximately 2% of extra nodal lymphomas [5, 6, 7].

Malignant lymphomas of the oral cavity represent 5% of all lymphomas and are most common among male patients between 50 to 70 years of age. NHL of oral cavity is often misdiagnosed. It resembles to squamous cell carcinoma clinically and radiographically. Often the first symptoms of large B-cell lymphoma of the oral cavity are painless swelling of the neck, fever, sweats, and weight loss [8, 9]. Exact cause of NHL is still ill defined. Viruses have been suggested as a potential cause of the disease. An increased rate of lymphoma in patients who are congenitally immunosuppressed and in patients who receive immunosuppressive therapy has been reported [3].

Diagnosis of NHL is established by incisional biopsy of suspected lesion in oral cavity. Lymphoid tissue should be handled with care, since mechanic forces easily damage the cellular morphology, making the assessment of a reliable histopathological diagnosis difficult if not impossible [10]. Immunohistochemistry adds in diagnosis to further characterize and categorize the disease. Diffuse large B-cell lymphomas express various pan-B markers such as CD19, CD 20, CD22, and CD79a, but may lack one or more of these. Patients are staged according to Ann Arbor staging system before initiating treatment [11].

Treatment normally consists of multi agent chemotherapy and or radiotherapy depending on the stage of disease. The initial chemotherapy regimen usually includes Cyclophosphamide, Doxorubicin, Vincristine, Prednisone, and Rituximab. Outcome is mainly determined by histological type and extent of the disease[12].

Extra nodal NHL of oral cavity is a rare occurrence, however patients with lesions of NHL in oral cavity commonly present in clinic in the first instance. We stress upon to keep in mind the possibility of NHL apart from squamous cell carcinoma in oral

cavity lesions. Proper biopsy and further investigation to timely diagnose and treat the disease have important implications to the prognosis of the disease.

## ABBREVIATIONS

NHL- non Hodgkin lymphoma, ENL- extranodal lymphoma, OPG- Orthopantograph, CT scan: computed tomography, IHC- immunohistochemistry, CK- cytokeratin, LCA- leukocyte common antigen, CD- cluster of differentiation, CHOP- Cyclophosphamide, Doxorubicin, Vincristine, Prednisolone.

## ACKNOWLEDGEMENT

Our sincere thanks to Prof Dr Ravikant, Vice chancellor, King George medical college, for guiding and permitting us to publish this article.

## REFERENCES

1. Angiero F, Stefani M, Crippa R; Primary non-Hodgkin's lymphoma of the mandibular gingiva with maxillary gingival recurrence. *Oral Oncol Extra*, 2006; 42:123-128.
2. Clark RM, Fitzpatrick PJ, Gospodarowicz MK; Extranodal malignant lymphomas of the head and neck. *J Otolaryngol*, 1983; 12:239-45.
3. Kobler P, Borcic J, Zore FI, Nola M, Sertic D; Primary non Hodgkins lymphoma of the oral cavity. *Oral Oncol Extra*, 2005; 41:12-14.
4. Burke JS; Waldeyer's ring, sinonasal region, salivary gland, thyroid gland, Central nervous system, and other extranodal lymphomas and lymphoid hyperplasias. D.M. Knowles (Ed.), *Neoplastic hematopathology* (2nd ed.), Lippincott Williams & Wilkins, Philadelphia, 2001; 1351-1390.
5. Guevara-Canales JO, Morales-Vadillo R, de Faria PE, Sacaquispe-Contreras SJ, Leite FP, Chaves MG; Systemic review of lymphoma in oral cavity and maxilla-facial region *Acta Odontol Latinoam*, 2011; 24:245-50.
6. Eisenbud L, Sciubba J, Mir R, Sachs SA; Oral presentations in non-Hodgkin's lymphoma: a review of thirty-one cases. Part I. Data analysis. *Oral Surg Oral Med Oral Pathol Oral Radiol Endod*, 1983; 56:151-156.
7. Kalyankar SN; Oral cavity non-Hodgkin's lymphoma: Clinicopathological aspects. *Int J Med Sci Public Health*, 2015; 4:53-55.
8. Velez I, Hogge M; Primary maxillofacial large B-cell lymphoma in immunocompetent patients: report of 5 cases. *Case Rep Radiol*, 2011; 2013:108023.
9. Roche P, O'Neill P, Kavanagh E, Rowley H; Isolated diffuse type B-cell lymphoma of the palate: an unusual entity. *BMJ Case Reports*, 2013:bcr2013008703.
10. Van der Waal R, van der Waal I; Oral non-squamous malignant tumors; diagnosis and

- 
- treatment. *Med Oral Patol Oral Cir Bucal*, 2007; 12:486-91.
11. Yu CH, Kuo YS, Chiang CP; Treatment of an oral malignant lymphoma by combined surgery and chemotherapy- case report. *Chin Dent J*, 2005; 24:159-164.
  12. Parrington SJ, Punnia-Moorthy A; Primary non-Hodgkin's lymphoma of the mandible presenting following tooth extraction. *Br Dent J*, 1999; 187:468-470.