

Treatment of refractory shield ulcer and update on its management

Deshmukh D.B, Phillip S.K

Armed Forces Hospital, Muscat, Oman

*Corresponding author

Dr Devdatta Deshmukh

Email: predev28@gmail.com

Abstract: Vernal Shield ulcer is a rare sight threatening corneal manifestation of vernal keratoconjunctivitis. This study is designed to report management of a refractory shield ulcer that did not respond to variety of medications but healed in 1 week after surgical debridement of ulcer base. A 12-year old Omani boy with H/O vernal conjunctivitis since 5 years on ketotifen eye drops presented with a shield ulcer in right eye. Slit lamp examination revealed a shield ulcer covered with mucus plaque in superior part of cornea in right eye and giant papillae in tarsal conjunctiva in both eyes. A bandage contact lens was inserted and he was put on topical fluromethalone, cyclosporine 0.5% along with lomefloxacin eye drops. Patient improved well symptomatically but ulcer did not heal completely even after 2 weeks. Removal of mucus plaque and surgical debridement of ulcer base was performed. Ulcer healed dramatically in 1 week with underlying stromal scar. Vernal shield ulcers and plaques are rare but serious and sight threatening complications of vernal keratoconjunctivitis. Ulcers unresponsive to standard medical therapy should have surgical intervention. A simple scraping of ulcer base and removal of plaque is an effective procedure resulting in rapid healing of ulcer.

Keywords: shield ulcer, vernal keratoconjunctivitis, and cobblestone papillae.

INTRODUCTION

Vernal keratoconjunctivitis (VKC) is a bilateral, seasonal, external ocular inflammatory disease primarily affecting children, characterized by intense itching, tearing, photophobia, and mucous discharge, and usually demonstrate large cobblestone papillae on superior tarsal or limbal conjunctiva and has environmental and racial predilections. It commonly begins in the spring, hence the name “vernal.” Although usually self-limited, VKC can result in potentially blinding corneal complications.

CASE REPORT

A 12-year old Omani boy with H/O vernal conjunctivitis since 5 years on ketotifen eye drops presented with complaints of pain and photophobia in the right eye. Slit lamp examination revealed a 3 x 2 mm ulcer in superior part of cornea in right eye (Figure -1), diffuse punctate epitheliopathy and giant papillae in tarsal conjunctivae in both eyes. He was diagnosed to be suffering from bilateral vernal keratoconjunctivitis, with grade 2 shield ulcers in the right eye. A bandage contact lens was inserted and he was put on G Fluromethalone 0.1% QID, G Lomefloxacin 0.3% BD, G ketotifen BD. He improved symptomatically but ulcer size remained the same. G cyclosporine 0.05 % QID was added. Patient followed up daily for a week. Ulcer size reduced gradually to 2 x 1.5 mm over a week but a mucus plaque covering the ulcer base superiorly along with superficial peripheral vascularization noticed on day 7. BCL was replaced and shifted to G Prednisolone 1% QID. Over second week there was

reduction in fluorescein staining but mucus plaque remained persistent. On day 13, surgical debridement of ulcer was done.

After topical anaesthesia, the plaque was removed with the tip of 26 gauge needle and ulcer base was scrapped with the edge of the needle under the slit lamp. BCL was replaced and topical medications were continued as before. Five days after removal of plaque, the ulcer re-epithelialized almost completely. Two weeks after plaque removal, the ulcer healed completely, leaving behind a nebular grade corneal opacity (Figure -2). The corticosteroids were tapered gradually, and symptoms of vernal keratoconjunctivitis were controlled satisfactorily with ketotifen eye drops. The patient was followed up for two months, and the ulcer did not recur.

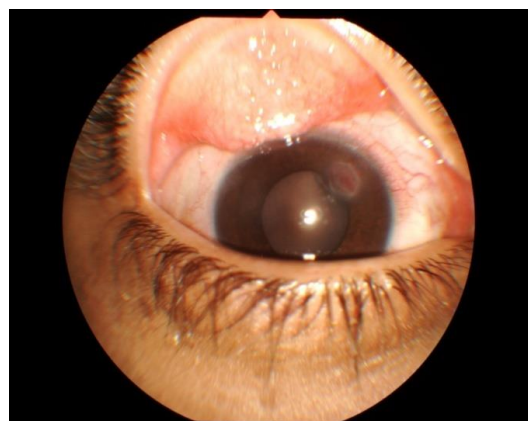


Fig-1: Shield ulcer with tarsal giant papillae

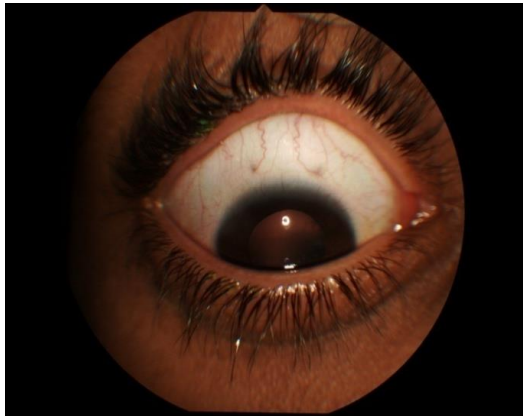

Fig-2: Healed shield ulcer

DISCUSSION

Corneal Complications

Although punctate epithelialopathy is the commonest, shield ulcer with or without plaque, keratoconus, hydrops, pseudogerontoxon, corneal opacification, amblyopia, strabismus, microbial keratitis are other corneal complications in VKC [1]. Coalescence of punctate erosions may lead to a large epithelial defect known as shield ulcer: shallow erosion with raised edges consisting of cellular debris and mucus. Named for their oval or shield-like shape, they tend to occur in the superior cornea. A single case of inferior vernal ulcer reported [2]. Shield ulcers have been reported to occur in 3% to 20% of VKC cases.

Grading- Cameron has proposed a classification system [3] for shield ulcers based on their clinical characteristics, response to treatment, and complications.

Grade 1 ulcer- has a clear base, responds favourably to medical treatment, and re-epithelializes with minimal scarring.

Grade 2 ulcers- has visible inflammatory debris in the base, responds poorly to medical therapy alone, and shows delayed re-epithelialisation with complications, such as bacterial keratitis.

Grade 2 ulcers show dramatic response to scraping the base of the ulcer.

Grade 3 ulcers- have elevated plaque formation and responds best to surgical therapy.

New clinical grading system of VKC (Table -1)

Dr. Marta Sacchetti (4) of the University of Rome and her colleagues collected data on age, gender, disease course, signs, symptoms, overall symptoms score, history of atopy, allergy markers, best-corrected visual acuity, and therapy at baseline and follow-up. The new grading system will allow clinicians to identify patients who have severe VKC and therefore have a higher risk of recurrence, corneal ulcer and a worse visual outcome.

Table-1: New clinical grading system of VKC

Grade	Clinical Findings	Treatment
0 Quiescent	Absence of symptoms	No treatments
1 Mild	Presence of symptoms with no corneal involvement	Anti-allergic eye drops occasionally
2 Moderate	Presence of symptoms associated with photophobia with no corneal involvement	Anti-allergic eye drops daily
3 Severe	Presence of symptoms associated with photophobia and mild to moderate SPK	Anti-allergic eye drops daily associated with pulsed low-dose topical steroid
4 Very severe	Presence of symptoms associated with photophobia and diffuse SPK or corneal ulcer	Pulsed high-dose topical steroid eventually associated with surgical removal of corneal plaque

Management of VKC

The treatment of VKC is frequently challenging and requires a multidisciplinary approach.

Nonspecific and medical therapy

Cool compresses, ice packs, and chilled eye drops may provide some relief, perhaps from a vasoconstricting effect. Artificial tears can dilute allergens and mediators in the tears and may also act as an eye wash. In the treatment of shield ulcer, topical antihistamines, dual action drugs, lubricants and corticosteroids are the first line of defence.

Management of shield ulcer Immunosuppressive agents –

Cyclosporine 1% to 2% ophthalmic emulsions in olive or castor oil have been shown to be effective in the treatment of VKC. Several groups have examined the effectiveness of cyclosporine at concentrations as low as 0.05%, but results at these levels have been equivocal. The 1% concentration seems to be the minimal effective concentration in such cases [5, 6]. Unlike corticosteroids, cyclosporine has not been associated with lens changes or increases in intraocular pressure and is used as steroid sparing agent.

Management of cobblestones

Supratarsal injection of corticosteroids –

Supratarsal injection of dexamethasone sodium phosphate 2 mg, triamcinolone acetonide 10.5 mg, hydrocortisone sodium succinate 50 mg were found to be very effective in temporary suppression of severe inflammation associated with VKC [7, 8].

Cryotherapy

It should be avoided as this result in scarring of the conjunctiva that can lead to lid and tear film abnormalities.

Excision

Excision of giant papillae with intraoperative use of Mitomycin C can be tried in severe and refractory cases of VKC with corneal lesions. Since VKC is a self-limited disease, extensive reconstructive surgery may not have an acceptable risk-benefit ratio.

Surgical debridement and superficial keratectomy-

Corneal shield ulcers may respond to bandage soft contact lenses [9, 10]. Patching, in addition to the medical therapy. Cases that do not respond to conservative measures or exhibit inflammatory deposits in the ulcer base may require surgical intervention. Several studies [11, 12] reported rapid successful re-epithelialisation of the cornea after surgical scraping of vernal plaques in patients who had been nonresponsive to maximal medical therapy.

Amniotic membrane grafting - Sridhar and colleagues [13] demonstrated additional benefits in combining amniotic membrane grafting with surgical debridement in a small group of VKC patients.

Limbal stem cell transplantation - Sangwan and colleagues [14] suggest that limbal stem cell transplantation may also have promise in severe cases of VKC.

Phototherapeutic keratectomy –

Also might be useful in removing superficial corneal scars. One study [15] demonstrated rapid re-epithelialization of three central corneal lesions from VKC that were treated with excimer laser phototherapeutic keratectomy. This was performed after active inflammation was controlled and the inflammatory plaque overlying the shield ulcer was removed.

CONCLUSION

Shield ulcer is an uncommon, incapacitating corneal manifestation that occurs in 3 to 20 % of patients of vernal keratoconjunctivitis. To prevent the vision threatening complications of shield ulcer, it should be treated aggressively and appropriately. Treatment of shield ulcer may vary from topical medication to surgical intervention, depending on the grade of ulcer. Removal of plaque and scraping of

base hastens the re-epithelialisation of drug resistant shield ulcer.

REFERENCES

1. Tabbara KF. Ocular complications of vernal keratoconjunctivitis. Canadian journal of ophthalmology. Journal canadien d'ophtalmologie. 1999 Apr; 34(2):88-92.
2. Srinivasan M, Srinivasan S: Vernal ulcer. Indian J Ophthalmol 1990; 38:33-4
3. Cameron JA. Shield ulcers and plaques of the cornea in vernal keratoconjunctivitis. Ophthalmology. 1995 Jun 30; 102(6):985-93.
4. Sacchetti M, Lambiase A, Mantelli F, Deligianni V, Leonardi A, Bonini S. Tailored approach to the treatment of vernal keratoconjunctivitis. Ophthalmology. 2010 Jul 31; 117(7):1294-9.
5. Akova YA, Dursun D, Pelit A. Topical cyclosporine in the management of shield ulcers. Cornea. 2004 Mar 1; 23(2):194-200.
6. Spadavecchia L, Fanelli P, Tesse R, Brunetti L, Cardinale F, Bellizzi M, Rizzo G, Procoli U, Bellizzi G, Armenio L. Efficacy of 1.25% and 1% topical cyclosporine in the treatment of severe vernal keratoconjunctivitis in childhood. Pediatric allergy and immunology. 2006 Nov 1; 17(7):527-32.
7. Singh S, Pal V, Dhull CS. Supratarsal injection of corticosteroids in the treatment of refractory vernal keratoconjunctivitis. Indian journal of ophthalmology. 2001 Dec 1; 49(4):241.
8. Holsclaw DS, Whitcher JP, Wong IG, Margolis TP. Supratarsal injection of corticosteroid in the treatment of refractory vernal keratoconjunctivitis. American journal of ophthalmology. 1996 Mar 31; 121(3):243-9.
9. Kumar S. Combined therapy for vernal shield ulcer. Clinical and Experimental Optometry. 2008 Jan 1; 91(1):111-4.
10. Quah SA, Hemmerdinger C, Nicholson S, Kaye SB. Treatment of refractory vernal ulcers with large-diameter bandage contact lenses. Eye & contact lens. 2006 Sep 1; 32(5):245-7.
11. Cameron JA. Shield ulcers and plaques of the cornea in vernal keratoconjunctivitis. Ophthalmology. 1995 Jun 30; 102(6):985-93.
12. Ozbek Z, Burakgazi AZ, Rapuano CJ. Rapid healing of vernal shield ulcer after surgical debridement: a case report. Cornea. 2006 May 1; 25(4):472-3.
13. Sridhar MS, Sangwan VS, Bansal AK, Rao GN. Amniotic membrane transplantation in the management of shield ulcers of vernal keratoconjunctivitis. Ophthalmology. 2001 Jul 31; 108(7):1218-22.
14. Sangwan VS, Murthy SI, Vemuganti GK, Bansal AK, Gangopadhyay N, Rao GN. Cultivated corneal epithelial transplantation for severe ocular surface disease in vernal keratoconjunctivitis. Cornea. 2005 May 1; 24(4):426-30.

15. Cameron JA, Antonios SR, Badr IA. Excimer laser phototherapeutic keratectomy for shield ulcers and corneal plaques in vernal keratoconjunctivitis. *Journal of Refractive Surgery*. 1995 Jan 1; 11(1):31-67.