

## Unusual Presentation of Follicular Carcinoma Thyroid- A Rare Case Report

Dr. Leena Verma<sup>1</sup>, Dr. Sunita Agrawal<sup>2</sup>, Dr. Dharmendra Singh Fatehpuriya<sup>3</sup>

<sup>1,2</sup>Assistant Professor, Department Of Pathology, Dr. S. N. Medical College, Jodhpur, Rajasthan, India

<sup>3</sup>Assistant Professor, Department Of Obstetrics and Gynaecology, Dr. S. N. Medical College, Jodhpur, Rajasthan, India

### \*Corresponding author

Dr. Leena Verma

Email: [leenadsf@gmail.com](mailto:leenadsf@gmail.com)

**Abstract:** Follicular thyroid carcinoma rarely manifests itself as a distant metastatic lesion. We report a known case of goiter in 76-year-old woman with follicular thyroid carcinoma who initially presented with pain in left shoulder. Fine needle aspiration cytology (FNAC) from area near scapular neck and from thyroid show same picture of follicular cells arranged in microfollicles along with elevated serum thyroglobulin level establish the diagnosis of metastatic follicular thyroid carcinoma. This case of follicular thyroid carcinoma is reported because of its uncommon presentation with osteolytic lesion of scapular neck.

**Keywords:** Follicular thyroid carcinoma, metastatic lesion, osteolytic lesion.

### INTRODUCTION

Follicular thyroid carcinoma (FTC) is the second thyroid malignancy after papillary carcinoma [1]. This usually occurs in older age groups, with a peak incidence in the fifth decade [2]. It is three times more common in females than in males. This neoplasm tends to metastasize to organs such as lung and bone, brain, skin and adrenal glands. The lung is the most common metastatic site for thyroid carcinoma followed by bone [3, 4]. The incidence of distant metastasis of follicular thyroid carcinoma has been reported as between 11 and 25% [5-7]. However, follicular thyroid cancer presenting with metastases as initial presentation is very rare. We report and discuss the unusual presentation of this case.

### CASE REPORT

A 76 years old female was a known case of goiter and presented with pain in left shoulder. The patient was clinically euthyroid with normal general physical, systemic, and neurological examination. Routine blood tests and thyroid function tests were normal. MRI showed an expansile lytic left scapular neck mass measuring 4.9 x 3.2 x 3.9 cm with cortical erosion and minor soft tissue component. There was involvement of bony glenoid and displacement of deep muscle around shoulder girdle. MRI imaging finding was in favour of malignancy. Patient came for FNAC from scapular neck. FNAC from area near scapular neck obtained was stained with Leishman stain. Smears showed many thyroid follicular cells having monotonous enlarged, hyperchromatic nuclei arranged in microfollicles containing colloid. (FIGURE-2,4). Patient had goiter from many years. But patient was not willing to go for FNAC from neck swelling because she thought that there was no problem with neck goiter.

After convincing she agreed for FNAC of thyroid swelling. Fine needle aspiration cytology (FNAC) from thyroid was reported as follicular neoplasm. (Figure-1,3). But she refused for biopsy. The serum TG level was found to be extremely high (3100 ng/ml), which clearly indicates that the neoplasm was of thyroidal origin.

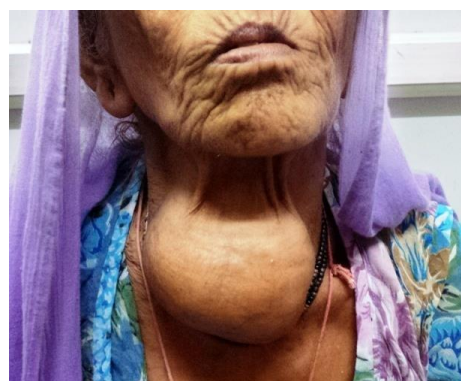
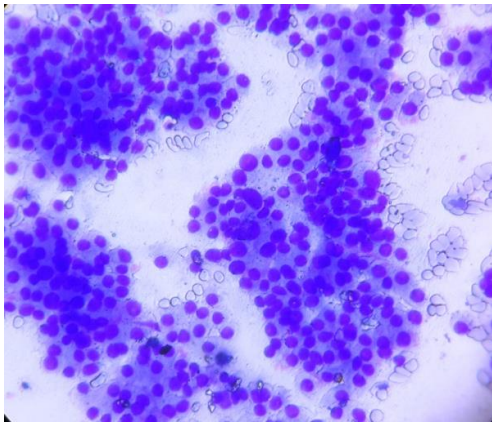


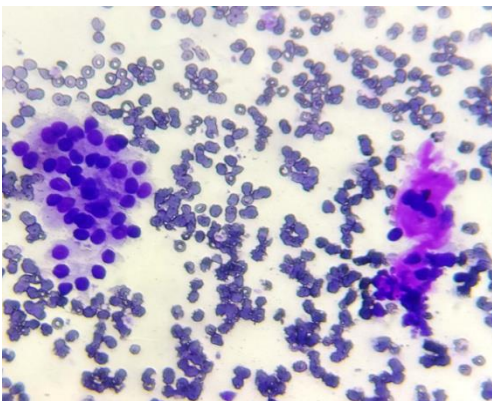
Fig-1: Show thyroid swelling

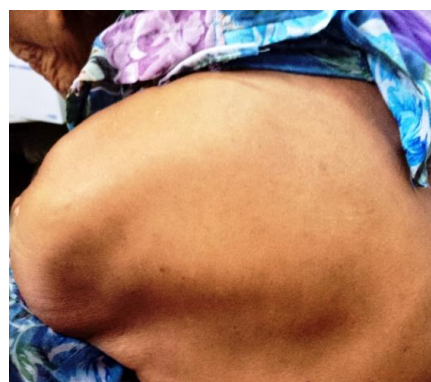

Fig-2: Show no gross lesion of left scapula



**Fig-3: Show syncytial and follicular arrangement of thyroid cells**



**Fig-4: Show metastatic thyroid cells in microfollicular arrangement and colloid**

## DISCUSSION

However, Follicular thyroid carcinoma (FTC) presenting with metastases as initial presentation is very rare. There have been a few case reports of follicular carcinoma causing unusual bony metastases, such as skull [8], mandible [9], maxilla [10], spine [11], and orbit [12]. Nevertheless, there are very few reports regarding the initial presentation of patients with distant metastasis leading to diagnosis of FTC. Emerick *et al* [13] reported two patients (3.6%) with distant metastasis at presentation. Shaha *et al.* [14] reported a higher incidence of distant metastases (11%) in a series of 1,038 patients with FTC in which 4% presented initially with distant metastatic disease. The study of Durante *et al.* found 44% of bone metastases in 444 metastatic differentiated thyroid carcinoma patients. They are more frequent in Follicular thyroid carcinoma (7–28%) compared with Papillary thyroid carcinoma (1.4–7%). The bones most often involved in metastasis of follicular carcinoma are the long bones, such as the femur and flat bones, particularly the pelvis and sternum [15].

## CONCLUSION

We have presented an unusual case of follicular thyroid carcinoma with metastasis in scapular neck which is a rare site for metastasis.

## REFERENCES

1. Kaplan EL. Principles of surgery. In: Schwartz SI, Shires GT, Spencer FC, editors. Thyroid and parathyroid. 5th ed. Singapore: McGraw-Hill Book Company. 1989;1613-1685.
2. Sobrinho Simoes M, Asa SL, Kroll TG, Nikiforov Y, DeLellis R, Farid P, Kitamura Y, Noguchi SU, Eng C, Harach HR. Follicular Carcinoma. In World Health Organization Classification of Tumors: Pathology and Genetics of Tumors of Endocrine Organs. Edited by DeLellis RA, Lloyd RV, Heitz PU, Eng C. Lyon: IARC Press; 2004;67-72.
3. Akdemir I, Erol FS, Akpolat N, Ozveren MF, Akfirat M, Yahsi S. Skull metastasis from thyroid follicular carcinoma with difficult diagnosis of the primary lesion-Case report. *Neurologia medico-chirurgica*. 2005;45(4):205-8.
4. Rahman GA, Abdulkadir AY, Olatoke SA, Yusuf IF, Braimoh KT. Unusual cutaneous metastatic follicular thyroid carcinoma. *Journal of surgical technique and case report*. 2010 Jan 1;2(1):35-8.
5. Girelli ME, Casara D, Rubello D, Piccolo M, Piotta A, Pelizzo MR. Metastatic thyroid carcinoma of the adrenal gland. *J Endocrinol Invest*. 1993;16:139-141.
6. Shaha AR, Shah JP, Loree TR. Differentiated thyroid cancer presenting initially with distant metastasis. *The American journal of surgery*. 1997 Nov 30;174(5):474-6.
7. Lin JD, Chao TC, Hsueh C. Follicular thyroid carcinomas with lung metastases: a 23-year retrospective study. *Endocrine journal*. 2004;51(2):219-25.
8. Özdemir N, Şenoğlu M, Acar ÜD, Canda MŞ. Skull metastasis of follicular thyroid carcinoma. *Acta neurochirurgica*. 2004 Oct 1;146(10):1155-8.
9. Anil S, Lal PM, Gill DS, Beena VT. Metastasis of thyroid carcinoma to the mandible: case report. *Australian dental journal*. 1999 Mar 1;44(1):56-7.
10. Hefer T, Manor R, Joachims HZ, Groisman GM, Peled M, Gov-Ari E, Laufer D. Metastatic follicular thyroid carcinoma to the maxilla. *The Journal of Laryngology & Otology*. 1998;112(01):69-72.
11. Scarrow AM, Colina JL, Levy EI, Welch WC. Thyroid carcinoma with isolated spinal metastasis: case history and review of the literature. *Clinical neurology and neurosurgery*. 1999 Dec 31;101(4):245-8.
12. Daumerie CH, De Potter P, Godfraind C, Rahier J, Jamar F, Squifflet JP. Orbital metastasis as primary manifestation of thyroid carcinoma. *Thyroid*. 2000 Feb;10(2):189-92.
13. Emerick GT, Duh QY, Siperstein AE, Burrow GN, Clark OH. Diagnosis, treatment, and outcome of follicular thyroid carcinoma. *Cancer*. 1993 Dec 1;72(11):3287-95.
14. Shaha AR, Shah JP, Loree TR. Differentiated thyroid cancer presenting initially with distant

metastasis. The American journal of surgery. 1997  
Nov 30;174(5):474-6.

15. Nagamine Y, Suzuki J, Katakura R, Yoshimoto T, Matoba N, Takaya K. Skull metastasis of thyroid carcinoma: study of 12 cases. Journal of neurosurgery. 1985 Oct;63(4):526-31.