

Solitary Osteochondroma of the C2/3 intravertebral disc as a Cause of Neurolopathy in a Child

Yangliang Huang¹, Yi Zhong², Shaoyu Liu¹

¹Department of Spine Surgery, the First Affiliated Hospital, Sun Yat-Sen University, Guangzhou, 510700, China

²Department of physiology, Guangzhou Medical University, Guangzhou, 510182, China

***Corresponding author**

Yangliang Huang

Email: lansedeahi@aliyun.com

Abstract: Osteochondroma is a common benign tumor but rarely affects the spine and causes neurological symptom. Neurolopathy caused by tumor compression in a child is unusual. We report a 7-year-old girl who complained of neck and shoulder pain that had been slowly progressing over 3 month. Phychical examniation revealed positive pathological signs at right extremities. Clinical history, plain radiographs, computed tomography and MRI pictures were collected. Complete resection of the tumor through anterior C2/3 discectomy and fusion resulted in solid fusion and resolve of patient's symptoms. No recurrence was discovered by 3 years' follow-up. This case is important in differential diagnosis of child radiculopathy and/or mylopathy.

Keywords: cervical spine, osteochondroma, radiculopathy, mylopathy, discectomy, fusion, child.

INTRODUCTION:

Osteochondroma is a very common tumor affecting bone. It takes up about 8.5% of all bone tumors and 36% of benign ones[1], however, only 1.3-4.1% of them originate in the spine[2]. Radiculopathy and myelopathy caused by upper cervical osteochondroma compression and our patient aged in her first decade are rarely seen and had never been reported before. We present this unique case to benefit differentiate diagnosis of children neurolopathy.

CASE REPORT

History

A 7-year-old girl complained of right-sided neck and shoulder pain combined with cervical movement limitation that had been slowly progressing over 3 month. Her symptom was worst in the morning and improved somewhat during the day. She denied trauma, fever, chills, and change in weight. She was misdiagnosed into atlantoaxial rotatory dislocation in local hospital. Cervical X-ray examination was normal. Previous treatment had included NSAIDs, with no relief achieved.

Examination

Physical examination revealed limitation of all neck movements, cervical range of motion 40° flexation, 30° extension, 5° left rotation, and 10° right rotation. There was tenderness on the right side of the neck. Neurologic examination revealed positive Hoffmann sign on the right hand and hypesthesia on the C2 never dermatome. The deep tendon reflex of right lower extremity was increased. Cord compression was speculated at upper cervical levels. Computed tomography was prescribed and a 1-cm bone density mass was discovered at the right neural foramen of the axis. It projected into the spinal canal and occupied the right neural foramen. It had a round shape appearance and asymmetric distribution of density. The density was not equal with vertebra bone. (Fig. 1a,b).Magnetic resonance imaging not only confirmed the presence of the tumor, but also revealed the origination to be the C2/3 intravertebral disc (Fig 1c). Both T1 and T2-weighted images showed a low signal of the exocytosis and demonstrated cord compression. But there was neither high signal nor swelling of the cord. X-rays did not demonstrate bony excrescences on the long tubular bones and there was no history of Hereditary multiple exostoses (HME) recorded.

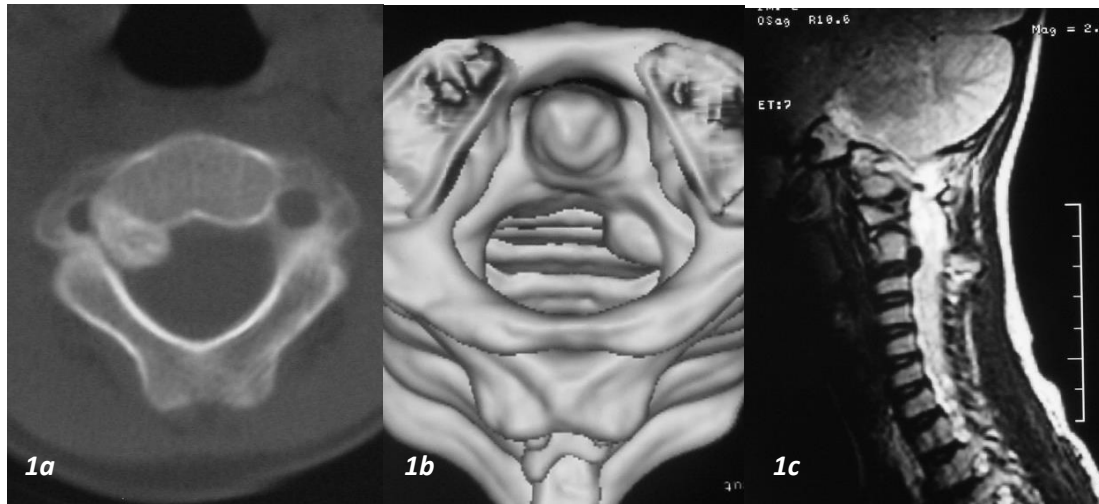


Fig 1: Pre-operative images

1a 1-cm bone density mass was located at the right nerve foramen of the axis. It projected posterolaterally into the spinal canal and occupied almost the total space of right neural foramen. The cortex and trabeculae of the exostosis did not have communications with vertebral bone;

1b-three-dimensional CT reconstruction of the upper cervical spine demonstrated the appearance of the osseous outgrowth;

1c-T2-weighted images showed a low signal of the exostosis and revealed cord compression, it also revealed the origination of the exostosis was the C2/3 disc;

Operation

Since Radiculopathy and myelopathy were presented, the decision of surgical excision was made. As the tumor originated from the C2/3 intravertebral disc, anterior discectomy and fusion was performed. The tumor was exposed by Robinson-spondylosis procedure, and resected completely. Autologous grafts were harvested and implanted into C2/3 disc space. As no anterior cervical plate was adequate for this patient, internal fixation was not employed. She was treated postoperatively with a rigid hard plastic collar that had to be worn constantly for 10-12 weeks.

Pathological findings and Postoperative course

Histopathological examination confirmed the lesion to be an osteochondroma without evidence of malignant (Fig 2). 1 week post-operation, neck and

shoulder pain disappeared. Solid fusion was achieved 3 months after operation (Fig 3a). After followed-up for 3 years, there was no recurrence of neck and shoulder pain, neurologic examination was normal. Cervical range of motion 45° flexion, 40° extension, 75° left rotation, and 75° right rotation. CT scan also demonstrated the disappearance of the cervical exostosis (Fig 3b).

The design and performance of this study conformed to ethical standards of Helsinki Declaration and our national legislation. It was approved by Medical Ethical Committee of our institution. Before enrolment, patient was enquired whether or not willing to take part in a scientific research and informed consent forms were signed by her parents.

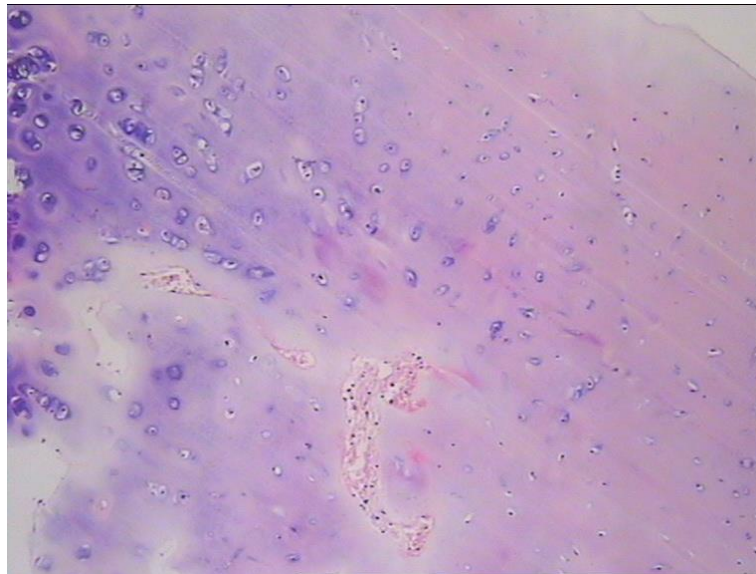


Fig 2: Histologic image- Micrograph of histologic section of the tumor demonstrated the cartilage cap. (HE stained, $\times 200$)

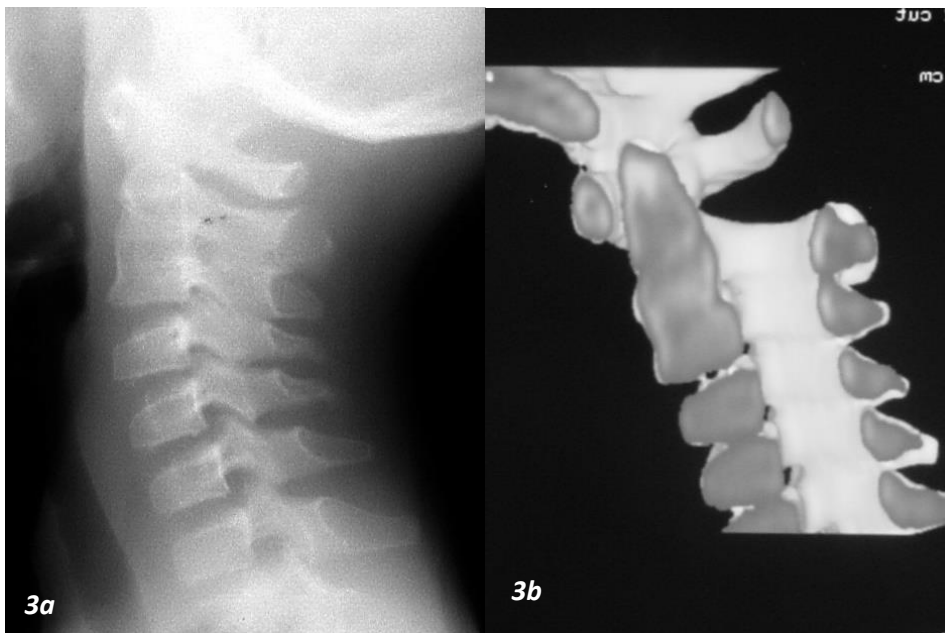


Fig 3: Post-operative images

3a- lateral cervical X-ray picture 3 month after operation, a solid fusion was achieved at the C2/3 intravertebral space;
3b-3D-CT 3 years post-operation confirmed no recurrence.

DISCUSSION

Osteochondroma, also known as exostosis, is a very common tumor affecting bone. It takes up about 8.5% of all bone tumors and 36% of benign ones [1]. If X-rays demonstrate multiple bony excrescences on the long tubular bones of family members, it is called Hereditary multiple exostoses (HME). Osteochondroma affects mostly the long bones, only 1.3-4.1% originates in the spine and no more than one third of them produce neurological symptom [2, 3]. Although HME patients has a much higher rate of spinal cord compression, our young patient did not exhibit any other exostosis in addition to the upper cervical lesion, which suggests

that it is an unusual case and has not been reported before.

Histologically, the exostosis is characteristic by two layers. The first one is the cartilage cap, and the second one is the enchondral ossification center. Bone materials originate from the first layer and develop into trabeculae at the second layer. Radiologically, the complex image formed by the spine makes spinal osteochondromas are difficult to detect on plain radiographs, thus CT scans serve as a better choose. It determines the tumour's extent and its relationship to the vertebral. Arasil[4] concluded 5 characters to be

typical of spinal osteochondromas: 1. Roundish, sharply outlined mass; 2. Bone-like density with scattered calcifications; 3. Paraspinal, dumbbell or eccentric intraspinal location; 4. Osteosclerotic changes in neighbouring bone; 5. Lack of contrast enhancement. However, CT scans are not sensitive enough to detect the cartilage cap structure and the tumor's relationship to the neural elements of the spine. They are best defined with an MRI scan.

As incomplete resection of osteochondroma would give a rise to recurrence, total remove surgical therapy is encouraged. Since the cartilaginous cap is the regenerate centre, pre-operative MRI examination is suggested to detect the real boundary of the tumor. Our MRI revealed that the tumor raised from the C2/3 intravertebral disc posteriorly, which grew upward and touched the axis vertebral body. This origination is different from other reports, in which tumor raised from the articular facet, lamina, spinous processes or the vertebral body [1, 5-9].

The main difficulty of surgical treatment lies in anterior exposure of axis. However, the jaw of teenagers is relatively small, the visualization obtained by Smith and Robison procedure was sufficient for anchoring pin insertion. The pin functioned as a retractor which separates muscles away and permitted a triangle working area around disc space. This traction force was localized and minimizes irritation to sounding structures. Although it had to be applied continually, the preparation of disc space would not cost more than half an hour. The second difficulty of surgery lies in the resection of bony structures, which require heavy instruments close to delicate structures [7]. In this case, after C2/3 intravertebral disc was removed and inferior axis body edge was resected, the tumor which mainly composed of cartilage was exposed and taken out. Both neck and shoulder pain disappeared 1 week post-operation. 3D-CT scan confirmed no recurrence after 3 years of follow-up.

It is not easy to discover spinal osteochondroma at the initial visit. However, the neurological deficits serve as a warning sign for us to take further examinations. Moreover, hypesthesia on the C2 dermatome is the evidence of nerve root compression. Neurologic symptoms, such as radiculopathy and myelopathy in our case, are not common.

CONCLUSION

Neurolopathy caused by osteochondroma compression and our patient aged in her first decade are rare. Both CT and MRI are useful tools in confirming the origin, size and extent of the tumor. The MRI examination revealed the total profile and relation with neuro elements. Complete surgical excision was possible and the patient had excellent functional recovery 1 week after operation. 3 years' follow-up

showed no recurrence. To our knowledge, this is the first case reported. Shoulder pain in child might be considered as a kind of radiculopathy which was produced by nerve root compression of upper cervical spine.

REFERENCES:

1. Kouwenhoven JW, Wuisman PI, Ploegmakers JF; Headache due to an osteochondroma of the axis. *Eur Spine J*, 2004; 13:746-749.
2. Tang WM, Luk KD, Leong JC; Costal osteochondroma: a Rare Cause of Spinal Cord Compression. *Spine*, 1998; 23: 1900-1903.
3. Khosla A, Martin DS, Awwad EE; The solitary intraspinal vertebral osteochondroma; an unusual cause of compressive myelopathy: features and literature review. *Spine*, 1999; 24:77-81.
4. Chang QZ, Sheng DJ, Lei SJ, Dai LY; Horner syndrome due to a solitary osteochondroma of C7. *Spine*, 2007; 32: 471-474.
5. Arasil E, Erdem A, Yuceer N; Osteochondroma of the upper cervical spine: A case report. *Spine*, 1996; 21:516-518.
6. Arvind GK, Atul G, Dattatraya M; Solitary osteochondroma arising from the thoracic facet joint. *Neurol Med Chir(Tokyo)*, 2004; 44: 255-257
7. Daisuke S, Joji M, Eiren T, Saglik Y; Spinal osteochondromas in middle-aged to elderly patients. *Spine*, 2002; 27:503-506.
8. Seiji O, Masatsune Y, Eiji H, Suzuki H, Takahashi K, Sameda H; Osteochondroma in the lumbar spinal canal causing sciatic pain report of two cases. *J Orthop Sci*, 2003; 8:112-115.
9. Stefanie BH, Marcos T, Madjid S; Osteochondroma of the cervical spine causing occipital nerve neuralgia-case report, *Neurol Res*, 2001; 23:777-779.