

## **Vulval Papillary Hidradenoma Clinically Mimicking a Sebaceous Cyst- A Case Report**

**Swagata Dowerah, Bandita Das**

Dept. of Pathology, Assam Medical College, Dibrugarh, Assam

### **\*Corresponding author**

Swagata Dowerah

Email: [swagatadowerah@gmail.com](mailto:swagatadowerah@gmail.com)

---

**Abstract:** Hidradenoma papilliferum is a rare benign adnexal tumor with apocrine differentiation seen in anogenital area of women. We present a 25 year old female presenting with an asymptomatic mass in the vulva. On examination, a single round nodule was seen in the vulva, firm and non-tender. A clinical diagnosis of Bartholin's cyst was made. On gross examination, a brownish mass measuring 1.5 X 1.5 X 1.5cms was seen which was greyish white on cut section. H &E stained sections showed papillary and complex glandular structures lined by columnar cells with eosinophilic cytoplasm. A diagnosis of papillary hidradenoma was made. This case is presented due to its rarity and to emphasise that while evaluating vulval nodules, hidradenoma needs to be considered, as these lesions lack distinctive clinical characteristics.

**Keywords:** hidradenoma, papilliferum, vulva, sebaceous cyst.

---

### **INTRODUCTION**

Hidradenoma papilliferum is a rare benign adnexal tumor having apocrine differentiation, which usually presents as an asymptomatic flesh-colored nodule in the anogenital area of women [1]. It is considered by some to be an analog of intraductal papilloma of the breast [2]. It probably derives from anogenital mammary-like glands, which often are found in or around the hidradenoma [2, 3]. Uncommonly, it can be seen over the head and neck, over modified apocrine gland areas such as breast, external ear canal, and eyelid, where it is referred to as ectopic hidradenoma papilliferum [4]. This tumor can be mistaken for a number of benign and malignant lesions. We present a case of hidradenoma papilliferum of vulva which was clinically mistaken for a Bartholin's cyst.

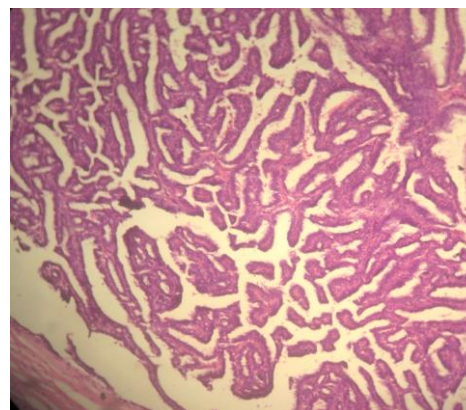
### **CASE HISTORY**

A 25 year old female presented with an asymptomatic mass in the vulval region which was noticed 2 months back. On examination, a single round nodule was seen in the vulva which was firm and non-tender. A clinical diagnosis of Bartholin's cyst was made. The mass was excised and sent for histopathological examination.

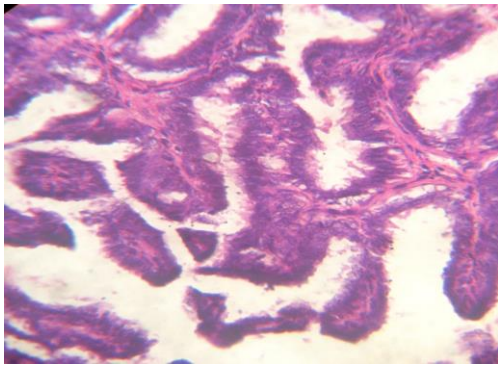
On gross examination, a brownish mass measuring 1.5 X 1.5 X 1.5cms was seen which was greyish white on cut section. H &E stained sections from the mass showed papillary and complex glandular structures. Papillary structures had fibrovascular core and were lined by columnar cells with eosinophilic cytoplasm. A diagnosis of papillary hidradenoma was made based on these histopathologic findings.



**Fig-1: Showing gross appearance of the tumor**



**Fig-2: Showing tumor cells arranged in papillary folds with fibrovascular core and tubules in cystically dilated space (H&E, 10X)**



**Fig-3: Showing papillae lined by columnar cells with decapitation secretion at places (H&E, 40X)**

## DISCUSSION

Hidradenoma papilliferum is a slow-growing tumor that primarily affects vulvar, perineal and perianal skin of middle-aged women with rare cases being reported in other skin localizations (ectopic hidradenoma papilliferum) [4, 5]. It usually presents as a slow-growing, solitary, asymptomatic skin colored or red nodule less than 1 cm in diameter [6]. Our case was slightly larger in size, measuring 1.5 X 1.5 X 1.5cms.

The lesion is usually asymptomatic, but may be revealed by itching, pain, bleeding or discharge, especially if it ulcerates. The tumor commonly presents as a solitary, firm, freely mobile well demarcated nodule covered by normal skin.

Histologically the tumor is characterized by a cystic space containing eosinophilic material and papillary folds projected from the cyst wall. The epithelium lining the papillae is composed by a basal layer of cuboidal cells and a luminal layer of larger columnar cells showing decapitation secretion [7]. Sometimes the tumor may show a histopathology similar to syringocystadenoma papilliferum since both are closely related tumors originating from apocrine glands [8]. The differential diagnosis also includes tubular apocrine adenoma. In our case however, the diagnosis was straightforward as classical histopathological features were seen.

Clinically, a wide range of differential diagnosis come into the picture, depending on the location of the tumor. These include viral warts, epidermoid carcinoma, even sebaceous cyst, lipoma and neurofibroma. In our case, the clinical suspicion was of a sebaceous cyst. The prognosis is good with local excision being the treatment of choice. Recurrence of the lesions is attributed to incomplete excision of the primary tumor and there is no report of recurrence for the ectopic form [4]. However, malignant transformation in anogenital hidradenoma papilliferum has been documented (intraductal carcinoma resembling apocrine carcinoma and invasive adenosquamous carcinoma) with HPV suspected to play a role in inducing malignancy [9].

## CONCLUSION

This case was presented due to its rarity and also to emphasise the point that while evaluating vulval nodules, hidradenoma needs to be kept in mind, as the lesion lacks distinctive clinical characteristics. Surgical excision is therefore important for definitive histopathological diagnosis and cure.

## REFERENCES

1. Daniel F, Mahmoudi A, de Parades V, Flejou JF, Atienza P; An uncommon perianal nodule: Hidradenoma papilliferum. *Gastroenterol Clin Biol.*, 2007; 31: 166–8.
2. van der Putte SCJ; Mammary-like glands of the vulva and their disorders. *International Journal of Gynecological Pathology*, 1994; 13(2): 150–160.
3. VdPS CJ; Anogenital "sweat" glands. *Histology and pathology of a gland that may mimic mammary glands.* *Am J Dermatopathol.*, 1991; 13: 557-567.
4. Vang R, Cohen PR; Ectopic hidradenoma papilliferum: A case report and review of literature. *J Am Acad Dermatol.*, 1999; 41: 115–8.
5. Santa Cruz DJ, Prioleau PG, Smith ME; Hidradenoma papilliferum of the eyelid. *Archives of Dermatology.* 1981; 117(1): 55–56.
6. Meeker JH, Neubecker RD, Helwig EB; Hidradenoma papilliferum. *American Journal of Clinical Pathology*, 1962; 37: 182–195.
7. Wilkinson EJ, Xie DL; Benign diseases of the vulva. In Kurman RJ, editor. *in Blaustein S Pathology of the Female Genital Tract.* 5th ed. New York, NY, USA: Springer, 2002; 37-98.
8. Nishie W, Sawamura D, Mayuzumi M, Takahashi S, Shimizu H; Hidradenoma papilliferum with mixed histopathologic features of syringocystadenoma papilliferum and anogenital mammary-like glands. *Journal of Cutaneous Pathology*, 2004; 31(8): 561-564.
9. Vazmitel M, Spagnolo DV, Nencova J, Michal M, Kazakov DV; Hidradenoma papilliferum with a ductal carcinoma in situ component: case report and review of the literature. *American Journal of Dermatopathology*, 2008; 30(4): 392–394.