

## Resolution of a Severe Complication after Lung Microwave Ablation with a Conventional Closed Drainage System

Qi-Feng Chen, Zhen-Yu Jia\*, Zheng-Qiang Yang

Department of Interventional Radiology, First Affiliated Hospital of Nanjing Medical University, Jiangsu, China

### \*Corresponding author

Zhen-Yu Jia

Email: [zhenyu.jia.tsyt@gmail.com](mailto:zhenyu.jia.tsyt@gmail.com)

---

**Abstract:** Lung microwave ablation (MWA) has been accepted as a treatment of lung cancer alternatively. Severe complications have been reported associated with this kind of thermal ablation. Herein, we present a case of severe complication after lung MWA for curative treatment of adenocarcinoma, comprising pulmonary cavitation evolving into bronchopleural fistula, severe mediastinal emphysema and subcutaneous emphysema, without pneumothorax, which was later successfully fixed with a conservative approach.

**Keywords:** microwave ablation; lung cancer; complication.

---

### INTRODUCTION

Lung microwave ablation (MWA) has been accepted as a safe and useful treatment for lung malignancies, which can be classified into curative, neoadjuvant and palliative [1]. Tumor smaller than 3.5 cm in diameter and completely surrounded by non-tumorous lung without extrapulmonary spread could be ablated completely [2]. The most common immediate complication of MWA in the lung is pneumothorax, with the incidence of 39% (22/66) and about one third of these severe enough to require chest tube placement [3].

### CASE REPORT

A 70-year-old woman presented with lung nodule without other chronic lung disease. The pathological diagnosis was adenocarcinoma determined by computed tomography (CT)-guided biopsy. The clinical stage was Ia (T1N0M0). Informed consent was obtained, and the patient underwent Microwave Ablation (MWA) for the treatment of left lung nodule, 2.1 cm in diameter. A cooled-shaft antenna (AI -11, Nanjing Yigao Microwave Electric Institute, Nanjing, China), which was connected to a microwave generator with a frequency of 2,450 MHz (ECO -100A; Nanjing Yigao Microwave Electric Institute, Nanjing, China), was centrally inserted into the tumor under CT (Figure 1 A). A power of 60 W was applied for 8 min. Immediate CT scan demonstrated no complication after procedure.

On day 5, the patient complained pain aggression of ablation area, and the second CT scan demonstrated a tunnel penetrating pleura without pneumothorax or subcutaneous emphysema. On day 6, the patient presented with persistent cough and haemoptysis. Physical examination found a smooth bulging of left

chest and back skin, which felt like Rice Krispies when touched the overlying skin. The third CT scan showed a significant cavitory lung lesion, mediastinal emphysema and subcutaneous emphysema with a tunnel connecting the lung cavity and subcutaneous area. Three small cuts were made in the skin of left chest to release the gas. Compression bandage was used to release the gas.

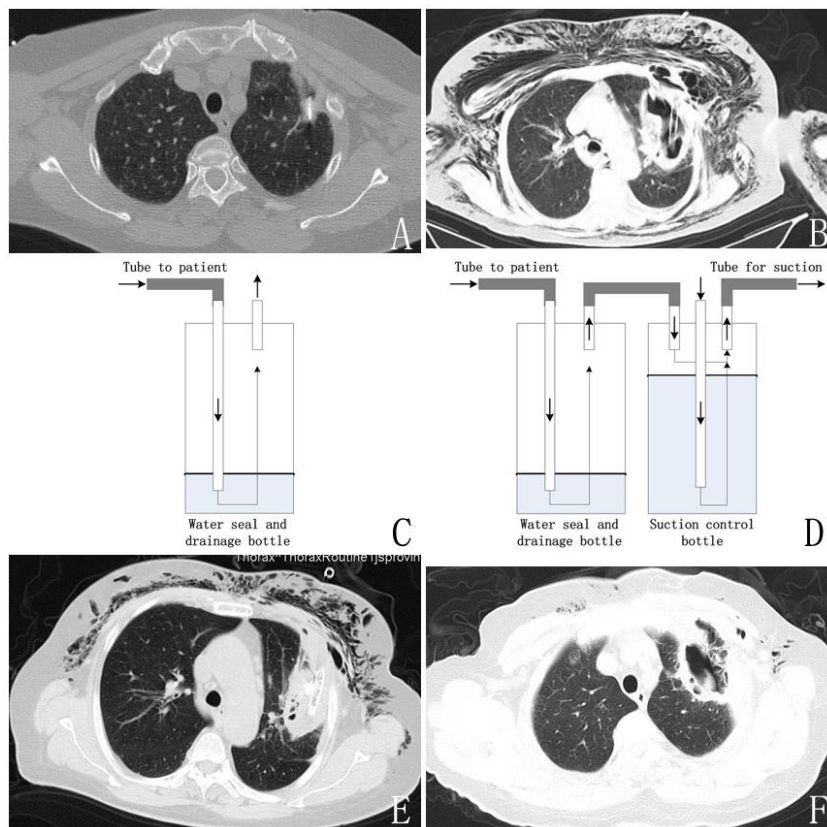
On day 7, the patient's eyelids swell so much that she could not see and the abdomen were gradually bulging. The fourth CT scan showed mediastinal emphysema and subcutaneous emphysema progressed significantly. A 10F pig tail catheter was placed into the lung cavity under CT guidance to eliminate the source of the air entering the subcutaneous space. A one bottle closed drainage system was connected to the pigtail catheter and occasional bubbling in the water-seal chamber was observed (Figure 1 C).

On day 10, symptoms caused by subcutaneous emphysema progressed, without tachypnea. The fifth CT scan demonstrated the pigtail catheter adhered to the cavity wall. Considering the affected lung tissue was in inflammatory swelling period and a lung lobe resection may cause uncontrolled bleeding or a persistent air leak, a lobectomy was refused. The pigtail catheter was removed and a chest tube was placed into lung cavity (Figure 1 B), connected with the one bottle closed drainage system (Figure 1 C). On day 12, the patient's clinical condition did not improve, so a two bottle closed drainage system with sustained negative pressure suction was used (Figure 1 D). Continuous bubbling in the water-seal chamber was observed.

On day 27, the patient's general condition got improvement after 15 days' sustained negative pressure

suction. The sixth CT scan showed the collapse of the lung cavity, the absorption of mediastinal emphysema and the significant reduction of subcutaneous emphysema (Figure 1 E). On day 29, the chest tube was removed, with a fifteen minutes compression of the incision point and another 3 hours compression with compression bandage. On day 34, patient's clinical

condition was stable, and a sequent CT scan showed a lung cavitory lesion with thick wall, without progression of subcutaneous emphysema (Figure 1 F). The good clinical condition of the patient allowed her discharge.



**Fig-1: Evolution of the lung lesion after the MWA. (A, day 1) The MWA antenna was placed at the center of the tumor. (B, day 10) A chest tube was placed into lung cavity, connected with a one bottle closed drainage system (C); (D, day 12) The patient's clinical condition did not improve, so a two bottle closed drainage system with sustained negative pressure suction was used. Continuous bubbling in the water-seal chamber was observed. (E, day 27) CT scans showed the collapse of the lung cavity, the absorption of mediastinal emphysema and the significant reduction of subcutaneous emphysema. (F, day 34) The chest tube was removed on day 29, and the last CT scans on day 34 showed a lung cavitory lesion with thick wall, without progression of subcutaneous emphysema.**

## DISCUSSION

Lung MWA is a safe and minimally invasive hyperthermal ablative technique for the treatment of lung tumor. Pneumothorax is the most common complication and may be life-threatening [4]. However, mediastinal emphysema and subcutaneous emphysema after MWA was seldom reported. The case we have described here developed a mortal complication after lung MWA involving severe mediastinal emphysema and subcutaneous emphysema secondary to pulmonary cavitation and bronchopleural fistula. Unintentional burns to bronchus and pleura in the vicinity of treated lesion were considered as the main cause [1].

In this case, continuous suction through the chest tube reduced the severe air leakage from the lung cavity

to subcutaneous space and immediately improved of the patient's clinical condition at last. The two-bottle closed drainage system could control the force of suction applied not too forceful. Small lumen catheter (10F pigtail catheter) or low suction negative pressure could not restore an adequate negative pressure in the pleural space/lung cavity. In previous reports, placing one-way endobronchial valves (EBVs; Zephyr™, Pulmonx, Redwood City, CA, USA) could be used to treat low and medium air leaks [4, 5]. While the procedure should be performed with bronchoscope, and the expense is relatively high. So, before placing EBVs into bronchus, continuous suction should be considered as the first choice.

## CONCLUSION

Pulmonary cavitation evolving into bronchopleural fistula, severe mediastinal emphysema and subcutaneous emphysema may occur after lung microwave ablation. Conventional closed drainage system could play a fundamental role in treating patients suffering from such severe complications.

## REFERENCES

1. Vogl TJ, Naguib NN, Lehnert T, Nour-Eldin NE; Radiofrequency, microwave and laser ablation of pulmonary neoplasms: clinical studies and technical considerations--review article. *European journal of radiology*, 2011; 77(2):346-357.
2. Belfiore G, Moggio G, Tedeschi E, Greco M, Cioffi R, Cincotti F, Rossi R; CT-guided radiofrequency ablation: a potential complementary therapy for patients with unresectable primary lung cancer—a preliminary report of 33 patients. *American Journal of Roentgenology*, 2004; 183(4):1003-11.
3. Wolf FJ, Grand DJ, Machan JT, Dipetrillo TA, Mayo-Smith WW, Dupuy DE; Microwave ablation of lung malignancies: effectiveness, CT findings, and safety in 50 patients. *Radiology*, 2008; 247(3):871-879.
4. Andreetti C, Maurizi G, Cassiano F, Rendina EA; Resolution of a life-threatening complication after lung radiofrequency ablation. *European journal of cardio-thoracic surgery: official journal of the European Association for Cardio-thoracic Surgery*, 2014; 46(4):e56-58.
5. Zhu JC, Yan TD, Glenn D, Morris DL; Radiofrequency ablation of lung tumors: feasibility and safety. *The Annals of thoracic surgery*, 2009; 87(4):1023-1028.