

Primary Tuberculous Mastitis

Dr. Natraj M¹, Dr. Irfan Ismail Ayub², Dr. Dhanasekar T³, Dr. Rajagopalan B⁴

Department of Chest & TB, Sri Ramachandra University, Chennai

***Corresponding author**

Dr. Natraj M

Article History

Received: 13.10.2017

Accepted: 18.10.2017

Published: 30.10.2017

DOI:

10.36347/sjmcr.2017.v05i10.015



Abstract: Breast tuberculosis is a rare form of extrapulmonary tuberculosis seen more commonly in patients from Indian sub-continent and Africa. It often mimics carcinoma and breast abscess. It commonly affects women of reproductive age or who are lactating. But rarely does it occur in male patients and in elderly women. Here we report an elderly woman diagnosed with primary breast tuberculosis.

Keywords: Tuberculosis, Breast, Primary breast tuberculosis

INTRODUCTION

Breast tuberculosis was first reported by Sir Astley Cooper in the year 1829 as “scrofulous swelling” in the bosom of young women. Tuberculosis primarily affects lungs. Breast tuberculosis is a rare condition. It can either be primary or secondary. Primary tuberculous mastitis is a very rare form of extra pulmonary tuberculosis [1]. Women in their reproductive age or who are lactating are at increased risk of developing tb mastitis. It commonly presents as a lump in the upper outer quadrant or central quadrant [2]. Major issue with tb mastitis is they can be misdiagnosed as carcinoma of the breast or pyogenic abscess of the breast [3].

CASE REPORT

62-year-old elderly woman came to our hospital with complaints of gradually growing swelling in the right breast for about three months. She also complained of loss of weight and loss of appetite. There was no history of cough, expectoration, hemoptysis, chest pain, wheeze or shortness of breath. There was no history of fever or any past history of tuberculous infection. She is neither a diabetic nor hypertensive. No significant past medical or surgical history. There was no significant family history or personal history. General examination was unremarkable with no lymph nodes. Physical examination confirmed a palpable lump in the right lower inner quadrat measuring 4 x 2 cms. There was no nipple retraction or discharge and ulceration.

Blood routines were all normal (CBC, LFT, RFT, SERUM ELECTROLYTES). Her ESR after one

hour was elevated. Urine routine examination was normal. Chest X ray was within normal limits. USG abdomen was normal while USG breast revealed a well-defined hetroechoic lesion of size 4.2 x 1.7 cms with internal echoes and eccentric solid component is noted in the right lower inner quadrant with minimal peripheral vascularity. Fine needle aspiration cytology of the lump showed granulomas consisting of epithelioid cells, lymphocytes and Langhan’s type of giant cells, with evidence of malignancy, which was conclusive for TB. About 0.5 ml of pus was also aspirated from the lump, which was sent for Gene X pert where MTB (Mycobacterium tuberculosis) was detected with no rifampicin resistance.

Based on these evidences patient was started on anti-tuberculosis therapy consisting of rifampicin, isoniazid, ethambutol and pyrazinamide.

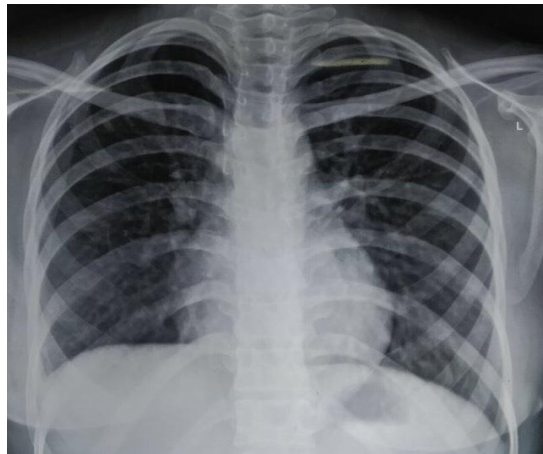


Fig-1: Normal Chest X Ray

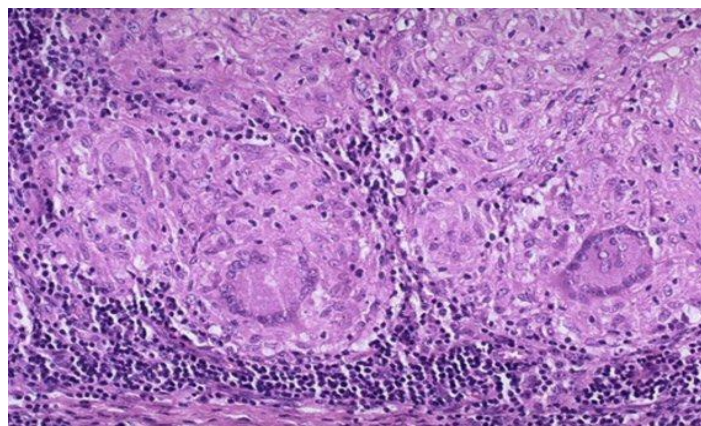


Fig-2: Histopathology shows Langhan's giant cell with granuloma

DISCUSSION

Mammary gland involvement in tuberculosis is very rare. It is often mistaken for malignant lesion. Incidence of TB mastitis in India ranges between 1 – 4% [4]. Mammary involvement is rare because like spleen and skeletal structures it offers resistance to the survival and multiplication of the organism. It can spread through three routes (a) hematogenous route, (b) lymphatic and (c) direct spread. TB mastitis can be either primary or secondary. Primary TB mastitis does not involve any other organ while in secondary mastitis infection can also be seen in lymph node, lung parenchyma or pleura [1]. TB mastitis can be commonly seen in young women who are in their reproductive age or who are lactating since the lactating breast is more vascular and are more prone to trauma. Bilateral involvement is very rarely seen (less than 3% of the cases). Duration of symptoms varies from few months to several years, but in most instances, it is less than a year [4]. The most common clinical presentation is breast lump, which is usually single, but rarely multiple lumps can also be seen. Classical presentations like ulcers, sinuses, matted nodes and breast mass are not that common. This makes the diagnosis difficult at times. Other symptoms include retraction of nipple and discharge from the nipple [4]. Diagnosis can be confirmed by histopathological examination of the tissue. FNAC can be useful in diagnosing more than

three quarters of the cases. Treatment of breast tuberculosis with standard anti tuberculosis therapy for 6 months yields very good results [4].

CONCLUSION

In our case there was a lesion measuring 4.2 x 1.7 cms with no evidence of any other organ involvement. Thus the diagnosis of primary tuberculous mastitis was made. TB mastitis is very rarely reported in elderly patients.

NOTE: Patient did not give us the consent to take pictures of her lesions.

REFERENCES

1. Singal r, bala j, gupta s, mahajan nc. Primary breast tuberculosis presenting as a lump: a rare modern disease. *Ann med health sci res.* 2013 jan-mar; 3(1): 110–112.
2. Marinopoulos S, Lourantou D, Gatzionis T, Dimitrakakis C, Pappaspyrou I, Antsaklis A. Breast tuberculosis: Diagnosis, management and treatment. *International journal of surgery case reports.* 2012 Dec 31;3(11):548-50.
3. Mirsaeidi SM, Masjedi MR, Mansouri SD, Velayati AA. Tuberculosis of the breast: report of 4 clinical cases and literature review.

4. Tauro LF, Martis JS, George C, Kamath A, Lobo G, Hegde BR. Tuberculous mastitis presenting as breast abscess. Oman medical journal. 2011 Jan;26(1):53.