

Usefulness of Gram Stain for Decision-Making Regarding Treatment for Disseminated Nocardiosis

Hiroki Nagasawa MD, Akihiko Kondo MD, Ikuto Takeuchi MD, Kei Jitsuiki MD, Hiromichi Ohsaka MD.PhD, Kouhei Ishikawa MD.PhD, Kazuhiko Omori MD.PhD, Youichi Yanagawa MD.PhD

Department of Acute Critical Care Medicine, Shizuoka Hospital, Juntendo University, Japan

*Corresponding author

Youichi Yanagawa

Article History

Received: 23.11.2017

Accepted: 27.11.2017

Published: 30.11.2017

DOI:

10.36347/sjmcr.2017.v05i11.029



Abstract: A 67-year-old man who had had difficulty moving due to a fever and right leg pain was admitted to our hospital, where his circulation became unstable. He had a history of pemphigoid, diabetes mellitus and renal failure treated by steroid and trimethoprim/sulfamethoxazole (TMP/SMX). Whole-body computed tomography revealed multiple small nodular lesions in the bilateral lung fields, which suggested abscess formation in the right leg. The patient was administered steroids, meropenem and TMP/SMX after drainage of the leg abscesses, as Gram stain revealed the presence of Gram-positive rod-shaped bacteria, suggesting *Nocardia* or *Actinomyces* species infection. After confirming that the infection had subsided with no recurrence, he was transferred to a rehabilitation facility on the 76th hospital day. Early decision-making regarding treatment based on the findings of Gram staining and broad-spectrum antibiotics were required to obtain a favorable outcome in this case of invasive *nocardiosis*.

Keywords: *nocardia*; diagnosis; treatment

INTRODUCTION

Nocardia species are a complex group of organisms considered to belong to the aerobic actinomycetes. Of the various described species, many have been implicated as the cause of serious human infections, especially in immunocompromised patients[1].

The most common clinical form is pulmonary nocardiosis with and without dissemination (60%), followed by skin and soft tissue infection (21%), bacteremia (11%) and peritonitis (5%). Resistance to trimethoprim/sulfamethoxazole (TMP/SMX) was detected in 15% of isolates, and 5% showed resistance to imipenem and 65% to ciprofloxacin[2]. The diagnosis can be challenging, as the signs and symptoms are not specific and a high index of clinical suspicion is necessary. Gram stain modified acid-fast stain and cultures remain the gold-standard diagnostic tools at present [3]. Of note, the disease has a marked tendency to recur and a high morbidity and mortality rate in immunosuppressed patients [2-4].

We herein report a case of disseminated *nocardiosis* in which a survival outcome was obtained thanks to a prompt Gram stain for early decision-making regarding the treatment.

CASE REPORT

A 67-year-old man who had had difficulty moving due to a fever and right leg pain was admitted to the Department of Orthopedics of our hospital. He developed unstable circulation, so he was transferred to the intensive-care unit. He had a history of pemphigoid,

diabetes mellitus and renal failure that had been treated by steroids and TMP/SMX. At arrival in the intensive-care unit, his vital signs were as follows: Glasgow Coma Scale, E3V4M6; blood pressure, 90/50 mmHg; pulse rate, 100 beats per minute; respiratory rate, 25 breaths per minute and body temperature, 38.1 °C. He had painful right leg swelling. Chest roentgen and electrocardiogram findings were negative. Whole-body computed tomography (CT) for detecting a septic focus revealed multiple small nodular lesions in the bilateral lung fields and suggested abscess formation in the right leg, which was confirmed by magnetic resonance imaging (Figures 1 and 2). The results of the biochemical analyses of the blood on arrival were as follows: white blood cells, 35,800/ μ l; hemoglobin, 11.2 g/dl; platelets, 12.0×10^4 / μ l; aspartate aminotransferase, 119 IU/L; alanine aminotransferase, 73 IU/L; blood urea nitrogen, 39.8 mg/dl; creatinine, 3.44 mg/dl; sodium, 143 mEq/L; potassium, 5.1 mEq/L; chloride, 111 mEq/L; creatine phosphokinase, 55 IU/L; prothrombin time 15.4 sec; activated partial thromboplastin time, 40.7 sec and D-dimer 33.1 μ g/ml.

The patient underwent tracheal intubation with mechanical ventilation and continuous infusion of vasopressors, steroids and antibiotics (meropenem and

TMP/SMX) after drainage of the leg abscesses, as Gram stain revealed Gram-positive rod-shaped bacteria forming partially acid-fast beaded branching filaments (Figure 3), suggesting *Nocardia* or *Actinomyces* species infection. On the 7th day, his circulation and respiration function stabilized, and he was extubated. He was moved to the general ward on the 10th hospital day. On

the 17th day, *Nocardia* infection and its drug sensitivity was determined based on the results of a culture analysis, so de-escalation of the antibiotics from meropenem to amoxicillin/clavulanate was performed. After confirming that the infection had subsided with no recurrence (Figure 1), he was transferred to a rehabilitation facility on the 76th hospital day.

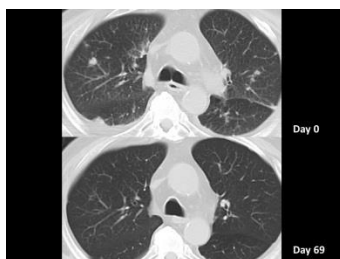

Fig-1: Whole-body computed tomography (CT) findings for the present case. CT to detect the septic focus revealed multiple small nodular lesions in the bilateral lung fields (upper: pre-treatment, lower: post-treatment)

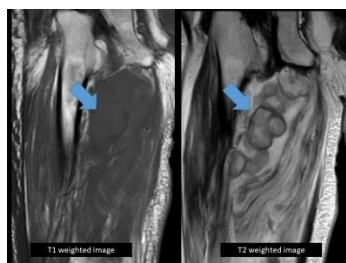


Fig-2: Magnetic resonance imaging (MRI) findings for the present case. MRI revealed low intensity on T1-weighted imaging and high intensity on T2-weighted imaging, suggesting abscess formation in the right leg (arrow)

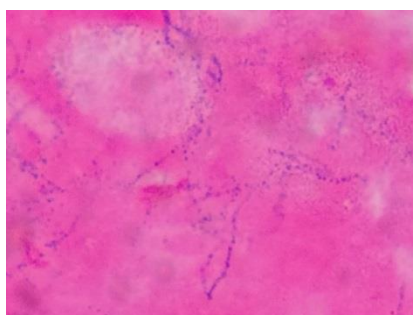


Fig-3: Specimen from abscess drainage with Gram stain. Gram stain revealed Gram-positive rod-shaped bacteria forming partially acid-fast beaded branching filaments

DISCUSSION

Prolonged therapy with systemic corticosteroids results in the selective suppression of the Th1-cellular immunity and has been reported as a major predisposing factor for pulmonary and disseminated *nocardiosis* [5]. Steroids are also frequently associated with other predisposing conditions. Ambrosioni *et al.* examined 28 patients with invasive *nocardiosis*. They found that 36% (10/28) of the patients were on steroid therapy, and 15% (4/28) had diabetes mellitus at the time of *nocardiosis* [3]. As the present patient had been receiving systemic corticosteroids due to his diabetes mellitus and pemphigoid, *Nocardia* invading via a skin lesion might have progressed to a leg abscess and disseminated *nocardiosis*.

The clinical and radiographic findings in pulmonary and disseminated *nocardiosis* are non-specific and may be mistaken for a variety of other bacterial infections, including actinomycosis and tuberculosis, as well as fungal infections and malignancies affecting the lungs, skin and brain [6]. The diagnosis of *Nocardia* requires the isolation and identification of the organisms from a clinical specimen. Since *nocardial* colonies can take up to two weeks to appear, it is important to notify the laboratory when *Nocardia* infection is suspected. Staining with modified acid-fast stain, especially Gram stain is particularly important for obtaining a rapid and important presumptive diagnosis while awaiting the

results of the culture, as was seen in the present case [7].

Given the rarity of *nocardiosis*, the most appropriate therapeutic agent, administration route and treatment duration have not been well-established in clinical trials [3]. SMX has been the agent of choice for the treatment of *nocardiosis* for more than 60 years. However, in patients with severe or disseminated disease, the mortality rate remains elevated with SMX monotherapy, and relapses are frequent [3]. In addition, different species have different antimicrobial resistance profiles, and some may be resistant to SMX. For these reasons, initial combination therapy with two or more active agents is recommended for patients with disseminated or severe *nocardiosis*[3]. Accordingly, the present case treated by meropenem and TMP/SMX resulted in a favorable outcome.

CONCLUSION

We herein described a rare case of disseminated *nocardiosis* in which a favorable outcome was obtained by multiple antibiotics therapy based on the results of Gram staining of an abscess drainage specimen.

REFERENCES

1. Conville PS, Brown-Elliott BA, Smith T, Zelazny AM. The Complexities of *Nocardia* Taxonomy and Identification. J Clin Microbiol. 2017 Nov 8. pii: JCM.01419-17.
2. Hardak E, Yigla M, Berger G, Sprecher H, Oren I. Clinical spectrum and outcome of *Nocardia* infection: experience of 15-year period from a single tertiary medical center. Am J Med Sci. 2012 Apr;343(4):286-90.
3. Ambrosioni J, Lew D, Garbino J. *Nocardiosis*: updated clinical review and experience at a tertiary center. Infection. 2010 Apr;38(2):89-97.
4. Budzik JM, Hosseini M, Mackinnon AC Jr, Taxy JB. Disseminated *Nocardia farcinica*: literature review and fatal outcome in an immunocompetent patient. Surg Infect (Larchmt). 2012 Jun;13(3):163-70.
5. Elenkov IJ. Glucocorticoids and the Th1/Th2 balance. Ann N Y Acad Sci 2004; 1024: 138–146.
6. Yildiz O, Doganay M. Actinomycoses and *Nocardia* pulmonary infections. Curr Opin Pulm Med 2006; 12: 228–234.
7. Martínez R, Reyes S, Menéndez R. Pulmonary nocardiosis: risk factors, clinical features, diagnosis and prognosis. Curr Opin Pulm Med 2008; 14: 219–227.