

Use of topical dorzolamide in a patient with X-linked juvenile retinoschisis

Shinji Makino¹

¹Department of Ophthalmology, Jichi Medical University, Shimotsuke, Tochigi 329-0498, Japan

*Corresponding author

Shinji Makino

Email: makichan@jichi.ac.jp

Abstract: We present a patient with X-linked juvenile retinoschisis before and after a topical use of dorzolamide. Ophthalmologic examinations showed a best corrected visual acuity (BCVA) of 0.3 in the right eye and 0.5 in the left eye. Fundoscopy demonstrated the typical stellate maculopathy of radiating cystoid spaces. Moreover, optical coherence tomography (OCT) results revealed a cleavage of the retina with thin-walled, vertical palisades separated by low reflective cystoid spaces. The patient was instructed to apply 2% dorzolamide three times daily in each eye. During a 3-month treatment period, OCT revealed a marked improvement in the foveal cystic lesions in the right eye, but not in the left eye. Moreover, BCVA was 0.6 in the right eye and 0.5 in the left eye after the 3-month treatment with dorzolamide. Our findings suggest that topical dorzolamide have some effect on improving foveal cystic lesions but it does not improve BCVA significantly.

Keywords: X-linked juvenile retinoschisis, optical coherence tomography, carbonic anhydrase inhibitors, dorzolamide.

INTRODUCTION

X-linked juvenile retinoschisis (XLRS) is characterized by vitreous degeneration and splitting of the retina between the nerve fiber and ganglion cell layers [1]. Typically, patients with XLRS present a cystic-like stellate maculopathy or a foveal schisis. The use of carbonic anhydrase inhibitors has been shown to be effective against cystoid macular edema in some patients with retinitis pigmentosa. Current research is focused on demonstrating the efficacy of topical dorzolamide in treating foveal cystic-appearing lesions in patients with XLRS [2-6]. We report a case of XLRS that was evaluated using optical coherence tomography

(OCT) before and after treatment with topical dorzolamide.

CASE REPORT

A 16-year-old boy was referred due to a gradual progressive bilateral visual loss associated with ocular fundus changes. The symptom had worsened in the past 5 years. The patient's family history was unremarkable. The ophthalmologic examination disclosed a best corrected visual acuity (BCVA) of 0.3 in the right eye and 0.5 in the left eye. Fundoscopy demonstrated the typical stellate maculopathy of radiating cystoid spaces, also known as spoke wheel-like maculopathy (Figure 1A and B).

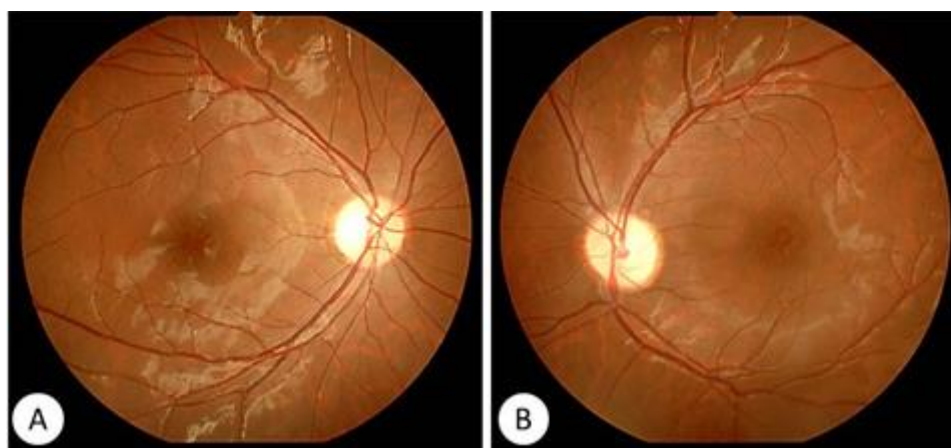


Fig-1: Fundus photographs of the right (A) and left (B) eye.
Note the stellate pattern and radial striae centered in the foveal area.

Furthermore, the OCT results revealed a cleavage of the retina with thin-walled, vertical

palisades, separated by low reflective cystoid spaces, which were confluent and most prominent in the foveal

region (Figure 2A and B and Figure 3A and B). The patient was instructed to apply 2% dorzolamide three times daily in each eye. During the 3-month treatment period, OCT revealed a marked improvement of his

foveal cystic-appearing lesions in the right eye, but not in the left eye (Figure 2C–F and Figure 3C–F). Moreover, the BCVA was 0.6 in the right eye and 0.5 in the left eye after a 3-month treatment with dorzolamide.

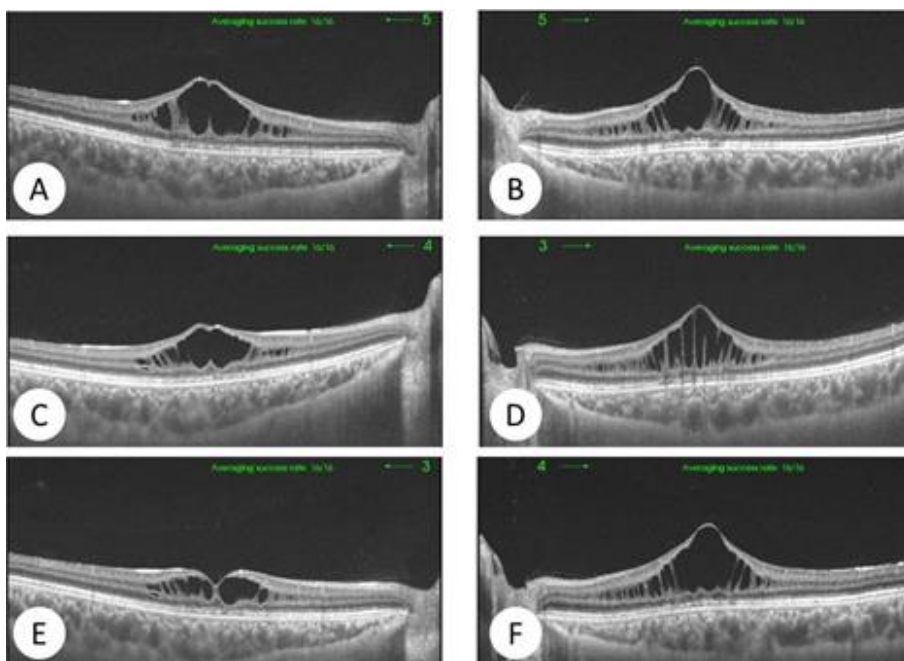


Fig-2: Optical coherence tomography images of the right (A, C, E) and left (B, D, F) fundi in the horizontal direction.

A, B: baseline; 1 month (C, D) and 3 months (E, F) after treatment with dorzolamide.

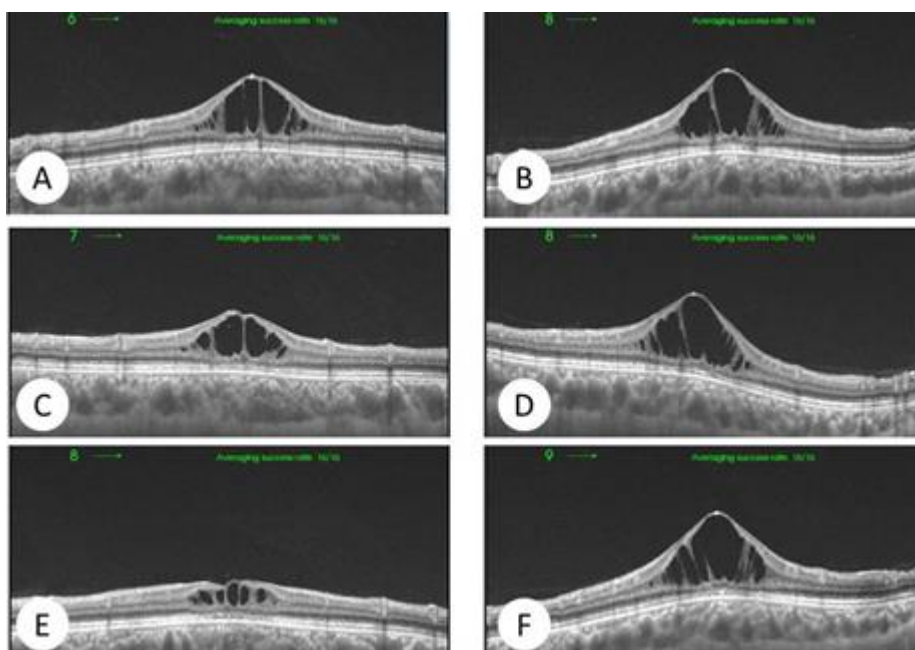


Fig-3: Optical coherence tomography images of the right (A, C, E) and left (B, D, F) fundi in the vertical direction.

A, B: baseline; 1 month (C, D) and 3 months (E, F) after treatment with dorzolamide.

DISCUSSION

There have been no therapeutic interventions effective for patients with XLRS so far. However, several studies have reported on the use of topical dorzolamide [2-6]. Apushkin and Fishman [2] have

treated eight patients with XLRS aged 21–47 years for up to 6 months with dorzolamide. They reported a noticeable reduction in the central macular thickness (CMT) in seven patients; five also showed an improvement in BCVA in at least one eye. Genead *et*

al. [5] treated 15 patients (29 eyes) with XLRS aged 18–53 years over a longer follow-up period (mean 16.5 months). They reported a reduction of CMT in 17 eyes, while 16 eyes showed an improvement of BCVA. They also noticed that five eyes experienced a ‘rebound’ phenomenon, where CMT levels returned to at least baseline levels during the treatment period.

Several possible mechanisms of action may explain the beneficial effects of topical dorzolamide in patients with XLRS [6]. Dorzolamide may decrease the levels of the subretinal fluid, either directly by active ion transport or indirectly by an increase in acidification, with secondary changes in ion and, therefore, fluid transport. Dorzolamide may also act by enhancing the adhesiveness of the retina to the retinal pigment epithelium (RPE), thus increasing the production of the otherwise deficient retinoschisin. Finally, dorzolamide may also act by stimulating the RPE removal of soluble retinoschisin within the cystic spaces.

Although our findings were based on a single case of XLRS, we suggest that topical dorzolamide may induce the reduction of foveal cystic lesions without any significant improvement in BCVA.

Disclosure

No conflicts of interest are declared in relation to this paper.

REFERENCES

1. Ozdemir H, Karacorlu S, Karacorlu M. Optical coherence tomography findings in familial foveal retinoschisis. *American journal of ophthalmology*. 2004 Jan 31; 137(1):179-81.
2. Apushkin MA, Fishman GA. Use of dorzolamide for patients with X-linked retinoschisis. *Retina*. 2006 Sep 1; 26(7):741-5.
3. Thobani A, Fishman GA. The use of carbonic anhydrase inhibitors in the retreatment of cystic macular lesions in retinitis pigmentosa and X-linked retinoschisis. *Retina (Philadelphia, Pa.)*. 2011 Feb; 31(2):312.
4. Walia S, Fishman GA, Molday RS, Dyka FM, Kumar NM, Ehlinger MA, Stone EM. Relation of response to treatment with dorzolamide in X-linked retinoschisis to the mechanism of functional loss in retinoschisin. *American journal of ophthalmology*. 2009 Jan 31; 147(1):111-5.
5. Genead MA, Fishman GA, Walia S. Efficacy of sustained topical dorzolamide therapy for cystic macular lesions in patients with X-linked retinoschisis. *Archives of Ophthalmology*. 2010 Feb 1; 128(2):190-7.
6. Khandhadia S, Trump D, Menon G, Lotery AJ. X-linked retinoschisis maculopathy treated with topical dorzolamide, and relationship to genotype. *Eye*. 2011 Jul 1; 25(7):922-8.