

Adrenal Extramedullary haematopoiesis in Thalassaemia major – A case report**Dr. Sanjay M. Khaladkar¹, Dr. Foram Doshi², Dr. Rohan Khujat³, Dr. Jayesh Ajwani⁴**¹Professor, Department of Radiodiagnosis, Dr.D.Y.Patil Medical College and research center, Dr.D.Y.Patil Vidyapeeth, Pimpri, Pune²Postgraduate resident, Department of Radiodiagnosis, Dr.D.Y.Patil Medical College and research center, Dr.D.Y.Patil Vidyapeeth, Pimpri, and Pune³Postgraduate resident, Department of Radiodiagnosis, Dr.D.Y.Patil Medical College and research center, Dr.D.Y.Patil Vidyapeeth, Pimpri, Pune⁴Postgraduate resident, Department of Radiodiagnosis, Dr.D.Y.Patil Medical College and research center, Dr.D.Y.Patil Vidyapeeth, Pimpri, Pune***Corresponding author**

Dr. Sanjay M. Khaladkar

Email: drsanjaymkhaladkar@gmail.com

Abstract: Extramedullary haematopoiesis (EMH) is seen in chronic hemolytic anemia's. EMH commonly occurs in the reticuloendothelial system like the liver and spleen which potentially produce fetal hemoglobin. It is rarely seen in organs like brain, lungs, pleura, breast, gastrointestinal tissue tract, kidney and the adrenal glands and in paraspinal region. EMH in adrenal gland is extremely rare. We report a case of 21 year old female, known case of thalassaemia major presenting with facial swelling and generalized weakness found to have hepatosplenomegaly, cellular marrow and extramedullary haematopoiesis in bilateral paraspinal region and in right adrenal gland.**Keywords:** Thalassaemia major, extramedullary haematopoiesis, Adrenal

INTRODUCTION:

Extramedullary haematopoiesis (EMH) is seen in chronic haemolytic anemia's like thalassaemia, sickle cell disease, hereditary spherocytosis and in hematological diseases like myelofibrosis and polycythemia vera. EMH is commonly seen in a transfused patient with thalassaemia intermedia and less frequently seen in inadequately transfused beta-thalassaemia major patients when erythropoiesis is not adequately suppressed by transfusions. The incidence of the EMH in thalassaemia major is less than 1 %, while in thalassaemia intermedia are upto 20 %. EMH commonly occurs in the reticuloendothelial system. It is rarely seen in organs like brain, lungs, pleura, breast, gastro intestinal tissue tract, kidney and adrenal glands and in paraspinal region [1].

CASE REPORT

21 years old female presented with facial swelling and generalized weakness. She was a known case of thalassaemia major. On per abdomen examination, there was hepatosplenomegaly. Her serum bilirubin was 2.9 mg %, direct bilirubin was 0.4 %, SGPT was 13 IU/ lit (normal 0-40 IU/ lit), SGOT was 46 IU / lit (normal 5-35 IU/ lit), Serum ALP was 77 IU / lit (normal 55 – 122 IU / lit), her RFT's were normal, serum protein were normal, her hemoglobin was 6.8 grams/ dl, PBS was suggestive of microcytic, hypochromic anemia and anisopoikilocytosis. USG

showed hepatosplenomegaly with normal echotexture. A well-defined solid hypoechoic mass measuring 4 x 2 cms was noted in right supra renal region (Figure 1).

MR abdomen showed hepatomegaly. Liver appeared markedly hypointense on T2WI suggestive of haemosiderosis (Figure 2A-C). No focal lesion was noted. No obstructive biliary dilatation noted. Splenomegaly was seen with cranio-caudal extent 20.8 cm with no focal lesion (Figure 2 A-C). Bilateral paraspinal soft tissue intensity lesion was noted in the lower dorsal spine, which appeared hypointense on both T1 and T2 WI (Figure 3 A-B). The right paraspinal mass measured approx. 29 x 20 mm and 36 x 15 mm; left paraspinal mass measured approx. 41 x 15 mm. A well-defined ovoid shaped solid mass measuring approx. 40 x 23 mm was noted in right adrenal region appearing hypointense of both T1 and T2WI (Figure 2C, 4 A-B). Dorsal and lumbar vertebrae appeared markedly hypointense of T2WI suggestive of cellular marrow (Figure 2B).

In view of thalassaemia, diagnosis of hepatosplenomegaly with haemosiderosis in liver, bilateral extramedullary haematopoiesis in paraspinal region, right adrenal extramedullary haematopoiesis with highly cellular marrow in dorso - lumbar spine was made.

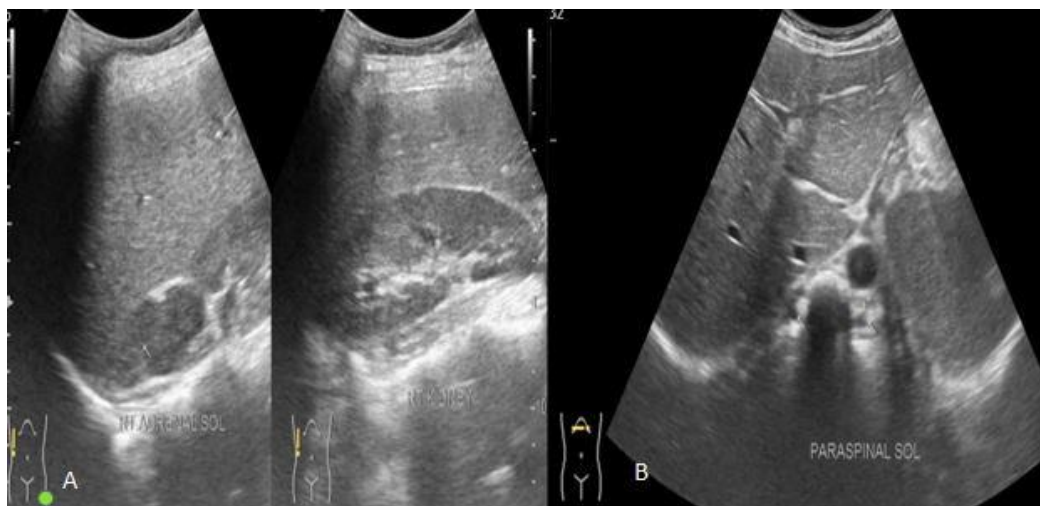


Fig 1: A- USG showing a well-defined hypoechoic solid mass in right suprarenal region. B- USG showing well defined hypoechoic solid lesion in bilateral lower dorsal paraspinal region.

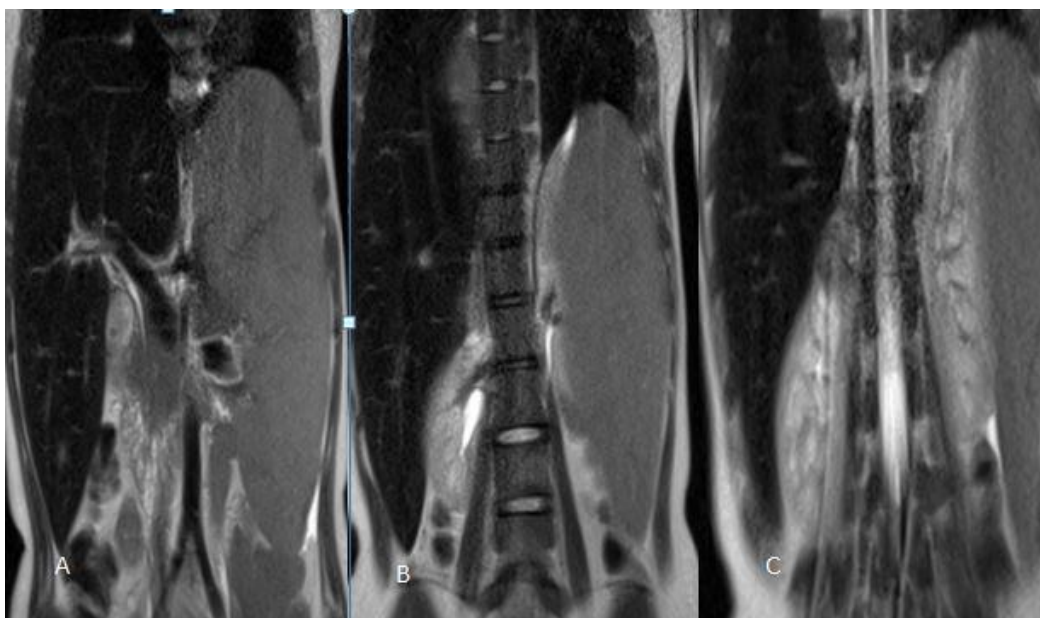


Fig 2: MRI Abdomen (Coronal T2)- A-showing hepato-splenomegaly with markedly hypointense liver, B- showing right paraspinal lesion, C- showing well defined right suprarenal mass.

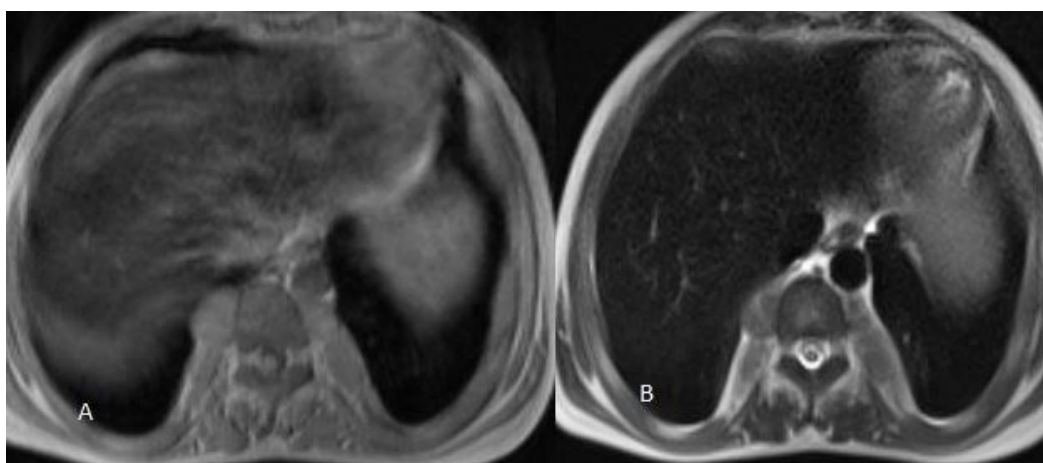


Fig 3: A- MRI Abdomen (Axial T1), B-(Axial T2)- showing bilateral paraspinal lesion in lower dorsal spine appearing hypointense in both T1 and T2WI.

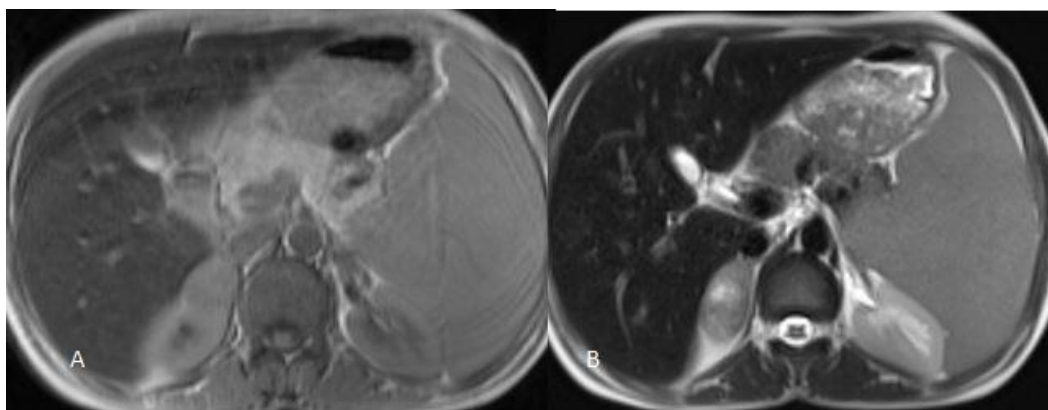


Fig 4: A- MRI Abdomen (Axial T1), B-(Axial T2)- showing well defined right suprarenal mass appearing hypointense in both T1 and T2WI.

DISCUSSION:

Extramedullary haematopoiesis is a physiological compensatory phenomenon due to inadequate bone marrow function with resultant altered haematopoiesis. Extramedullary sites of haematopoiesis are actively involved in haematopoiesis in fetal life which normally stops at birth. However, they retain this function due to ineffective red blood cell formation seen in hemolytic anemias, haemoglobinopathies, myeloproliferative disorder, leukemia and lymphomas. Histopathology examination revealed hematopoietic cells at various stages of maturation with predominance of the erythroid cell line [2].

The frequency of the EMH in thalassemia major is very low as ineffective erythropoiesis is suppressed by regular transfusion. Due to infrequent transfusion chronic hypoxia occurs with resultant EMH. EMH commonly occurs in the liver and spleen which potentially produce fetal hemoglobin. Non hepatosplenic EMH occurs in the brain, lungs, pleura, breast, gastrointestinal tissue tract, kidney, adrenal glands, urinary tract, prostate, peritoneum, paraspinal and paravertebral areas and skin [1, 3]. EMH occurs in organs that are evolved from pluripotential stem cells [4]. The incidence of the EMH in thalassemia who have received multiple transfusions is less than 1% [5].

EMH occurs in two forms – Para osseous and extraosseous. The normal medullary tissue of the bone marrow ruptures through the bone and presence as Para osseous mass. While extraosseous EMH occurs within soft tissue evolved from pluripotential stem cells [4]. Hepatosplenomegaly in thalassaemia is a sign of hepatosplenic EMH. In presents of hepatosplenomegaly, chances of non hepatosplenic EMH are low. Splenomegaly has an active role in prevention of non hepatosplenic EMH. It has a filtration role in spreading of hematopoietic stem cell. EMH in the paraspinal region in thoracic region is seen commonly. However, the reason for the increased frequency at this site is unknown.

EMH in the adrenal gland is extremely rare, few cases have been reported till now. The pathway of EMH involvement of the adrenal gland is unknown. The hypothesis include A) Adrenal gland has a hematopoietic capacity in fetal period and EMH may develop from primitive rests in the adrenal gland in diseased condition. B) Embolization of hematopoietic stem cells in adrenal gland. C) Extrusion of bone marrow from nearby bone in the presence of bony fracture or erosion D) Chronic hypoxia [1, 6].

On ultrasound it appears as a well-defined round homogeneous and hypoechoic mass. On CT scan, it appears as a non-homogeneous low density mass. On MRI, it appears hypointense to intermediate signal intensity mass on T2WI and hypo-hyperintense on T2WI. Amongst surgically removed adrenal incidentalomas, its prevalence is 3.6 % [7]. Adrenal EMH is usually asymptomatic and discovered incidentally. Larger lesions can become symptomatic due to compression on adjacent organs. An adrenal mass of ≥ 6 cm / functioning tumor should undergo adrenalectomy as the risk of adrenal cancer is 35-98 %, while nonfunctioning tumor of size ≤ 4 cms with benign imaging characteristic can be followed conservatively. Imaging characteristics, growth pattern and patient condition should be considered for lesion size 4-6 cms [2].

Treatment options in thalassemia patients in EMH depend on the symptoms and location and include a blood transfusion. Hydroxyurea stimulates the synthesis of hemoglobin F with resultant inactivation and shrinkage of EMH. Paraspinal and epidural lesions can be treated with low dose of radiotherapy [8]. Most cases of EMH occur in thalassaemia intermediate. The frequency of the EMH in thalassaemia major is very low, particularly when erythropoiesis is not suppressed adequately by transfusion. Our patient was a case of thalassaemia major with splenomegaly. Occurrence of the EMH in our patient is indicative of poor management of patient and shows an ineffective erythropoiesis [1].

CONCLUSION:

The frequency of the EMH in thalassemia major is very low. EMH in the adrenal gland is extremely rare. Presence of adrenal extramedullary haematopoiesis is suggestive of ineffective erythropoiesis due to inadequate blood transfusions.

REFERENCES:

1. Keikhaei B, Shirazi AS, Pour MM. Adrenal extramedullary hematopoiesis associated with β -thalassemia major. *Hematology reports*. 2012 Apr 13; 4(2):7.
2. Al-Thani H, Al-Sulaiti M, El-Mabrok G, Tabeb A, El-Menyar A. Adrenal extramedullary hematopoiesis associated with beta-thalassemia trait in an adult woman: a case report and review of literature. *International journal of surgery case reports*. 2016 Dec 31; 24:83-7.
3. Georgiades CS, Neyman EG, Francis IR, Sneider MB, Fishman EK. Typical and atypical presentations of extramedullary hemopoiesis. *American Journal of Roentgenology*. 2002 Nov; 179(5):1239-43.
4. Karami H, Kosaryan M, Taghipour M, Sharifian R, Aliasgharian A, Motalebi M. Extramedullary hematopoiesis presenting as a right adrenal mass in a patient with beta thalassemia. *Nephro-urology monthly*. 2014 Sep; 6(5).
5. Haidar R, Mhaidli H, Taher AT. Paraspinal extramedullary hematopoiesis in patients with thalassemia intermedia. *European Spine Journal*. 2010 Jun 1; 19(6):871-8.
6. Chourmouzi D, Pistevou-Gompaki K, Plataniotis G, Skaragas G, Papadopoulos L, Drevelegas A. MRI findings of extramedullary haemopoiesis. *European radiology*. 2001 Sep 1; 11(9):1803-6.
7. Zeighami S, Eslahi SA, Hosseini MM, Ariaifar A, Pakbaz S, Rastegari M, Khazraei H. Extramedullary Hematopoiesis in a Man With β -Thalassemia: An Uncommon Cause of an Adrenal Mass. *Annals of Colorectal Research*. 2015 Jun; 3(2).
8. Azarpira N, Esfahani MH, Paydar S. Extramedullary Hematopoiesis in Adrenal Gland. An Uncommon Cause of Adrenal Incidentaloma in Sickle Cell Disease. *Iranian journal of pediatrics*. 2014 Dec; 24(6):784.