

Fish-hook Injuries of the Eyelids: Different Approaches of ManagementKok-Leong Tan^{1,2}, Logandran Vijaya Kumar¹, Wan Hitam Wan-Hazabbah¹, Julieana Muhammed¹, Faridah Mat Amin², Ahmad Tajudin Liza-Sharmini¹¹Department of Ophthalmology, School of Medical Sciences, Health Campus, Universiti Sains Malaysia, Kubang Kerian, Kelantan, Malaysia²Department of Ophthalmology, Hospital Sultanah Nur Zahirah, Kuala Terengganu, Malaysia***Corresponding author**

Kok-Leong Tan

Article History

Received: 04.09.2017

Accepted: 09.09.2017

Published: 30.09.2017

DOI:

10.36347/sjmcr.2017.v05i09.026

**Abstract:** Fish-hook injury to the eyelid is not uncommon. The management of fish-hook injury is unique and involves various considerations due to the unique shape and design of fish-hook. Several removal techniques are possible. Here we present three cases of fish-hook injury to the eyelid and their different management in view various position and depth of the fish-hook. There is no single best technique of removal for all types of fish-hooks. Clinicians need to use their judgments to decide on the best method. Radioimaging like computed tomography (CT) scan is useful in assessing hook position and the extent of possible injury for deeply embedded fish-hook. Protective eyewear could be advocated as primary prevention.**Keywords:** fish-hook injury, removal, eyelid, trauma, management.**INTRODUCTION**

Fishing could be both a livelihood and a hobby. Fishing rod and hook are commonly used as they can be used to catch fish at riverbank, seashore or over a boat. Fish-hook injuries usually occur at the time of casting or pulling the hooks and weights. Although any parts of the body can be involved, eyelids involvement is not uncommon [1] and could be dangerous due to close proximity to the globe. We present three cases of fish-hook injury over the eyelid and review the literature on proper management of this type of injury.

CASE REPORTS**Case 1**

A 28-year-old man, presented with a fish-hook accidentally embedded into the middle of left upper eyelid while he was pulling the fishing rod around four hours ago. From history, he was using a barbed fish-hook. He complained of discomfort closing the eye. On examination, he had an unaided vision of 6/6 in both eyes. The right eye was normal. The fish-hook had pierced through the palpebral conjunctiva and embedded in the tarsal plate (Figure 1). Ocular motility was intact. Anterior segment and fundus examination were unremarkable. Booster dose of intramuscular tetanus toxoid (0.5ml) was administered.

The fish-hook was surgically removed using “Advance and Cut” method under local anaesthesia in operating-theatre (Figure 2 (a) – (d)). The fish-hook was advanced through the tarsal plate and overlying skin until its barb exited externally (Figure 2(a)). Then the barb was cut with a pair of pliers (Figure 2(b)) and the shank of the fish-hook was removed retrogradely. There was a small exit wound over the skin which was not sutured. He was discharged on the same day with topical moxifloxacin 0.5% for the eye and ointment chloramphenicol 1% over the lid wound. Patient was reviewed in a week and was discharged as the wound healed well.

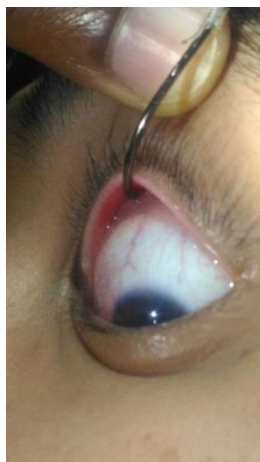

Figure 1: Fish-hook pierced the palpebral conjunctiva and embedded into the left upper tarsus

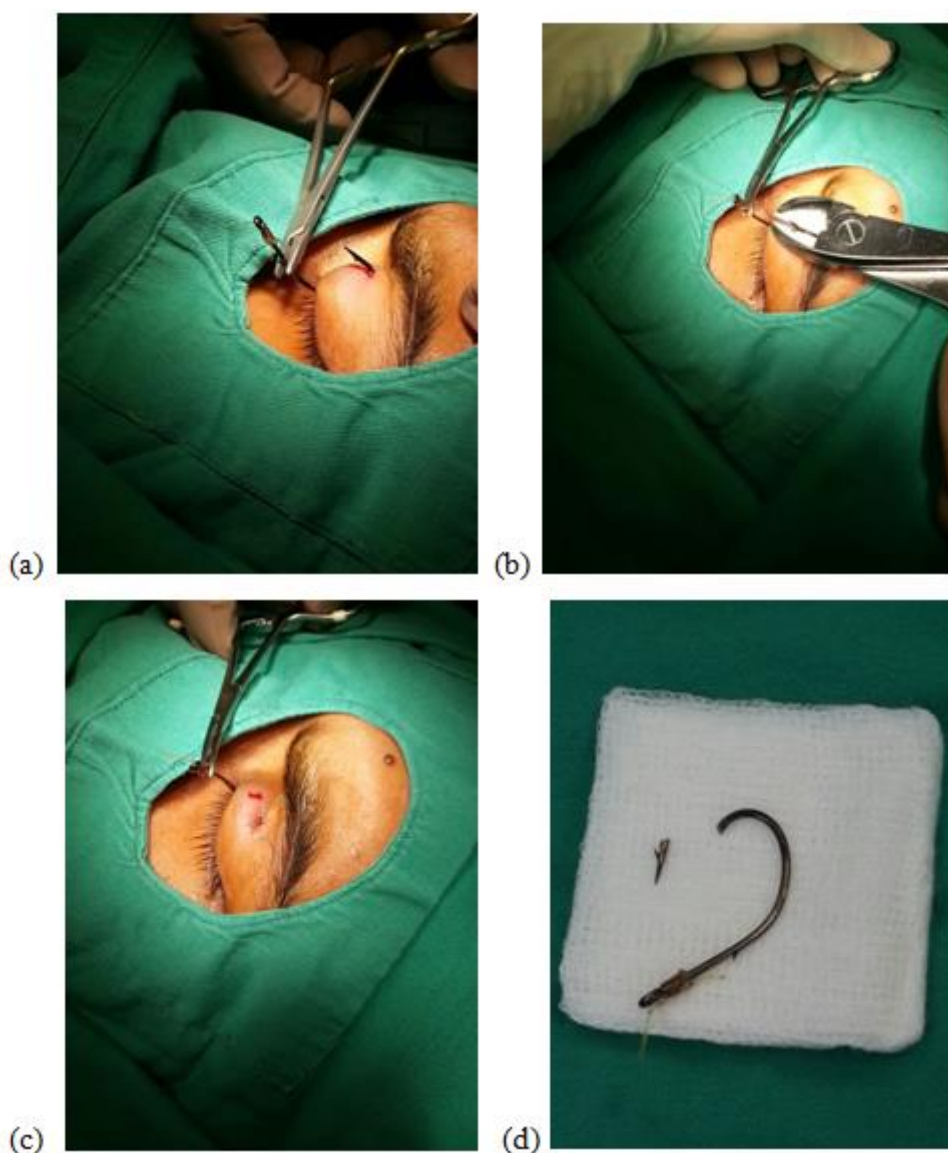


Fig-2: Fish-hook removed by “Advance and Cut” technique

CASE 2

A 9-year-old boy was presented at late evening with a barbed fish-hook anchored at the right upper eyelid around one and half hour ago. He complained of

right eye watery and redness, with pricking sensation on eye movement. On examination, his visions were 6/6 in both eyes. The left eye was normal. The fish-hook was quite mobile, embedded in the palpebral conjunctiva

with the tip pointing towards the eyeball (Figure 3). The right eye conjunctiva was injected; otherwise the anterior segment was unremarkable. Further eye examination was not performed and eye shield was applied. Booster dose of intramuscular tetanus toxoid, and intravenous amoxicillin-clavulanic acid were given. He just had meals before presentation. Examination and operation under general anaesthesia were done early next morning after he fasted adequately.

The fish-hook was removed using “Needle Cover” method. A large gauge needle (18G) was inserted along the entrance wound of the fish-hook until the needle opening covered the barb. The fish-hook and 18G-needle were then removed simultaneously, with the barb covered inside the lumen of 18G-needle preventing any tissue entanglement (Figure 4).

Intraoperatively it was noted that the fish-hook pierced the conjunctiva 2mm lateral to the upper punctum; with no canaliculi injury. The small conjunctival laceration post removal was not sutured. Other ocular examinations were unremarkable. Post operatively intravenous amoxicillin-clavulanic acid was continued and topical moxifloxacin 0.5% four hourly was added. On the next day, his right vision reduced to 6/18, with pin hole aided 6/9. There was an anterior chamber reaction (cells 1+). Topical prednisolone 1% four times per day was added. On day 3, the right vision improved to 6/9 with occasional anterior chamber cells. The patient was allowed home with oral amoxicillin-clavulanic acid. Topical medications were continued. The patient was reviewed in a week. The conjunctiva healed well and the anterior chamber inflammation resolved.

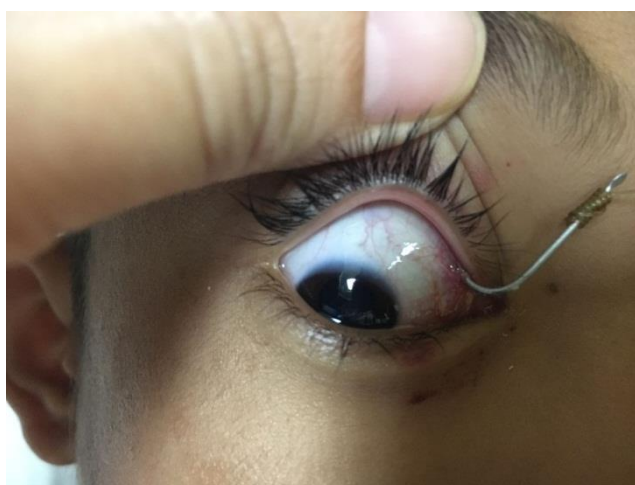

Fig-3: Fish-hook embedded in the palpebral conjunctiva just lateral to right upper punctum

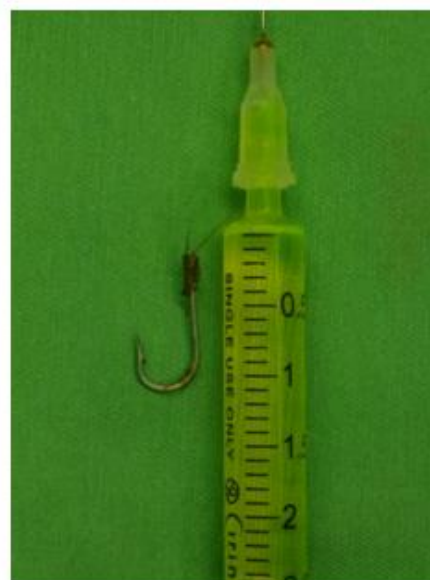
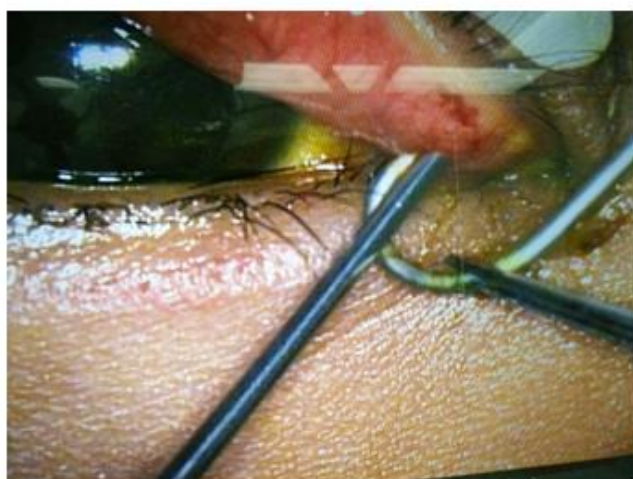
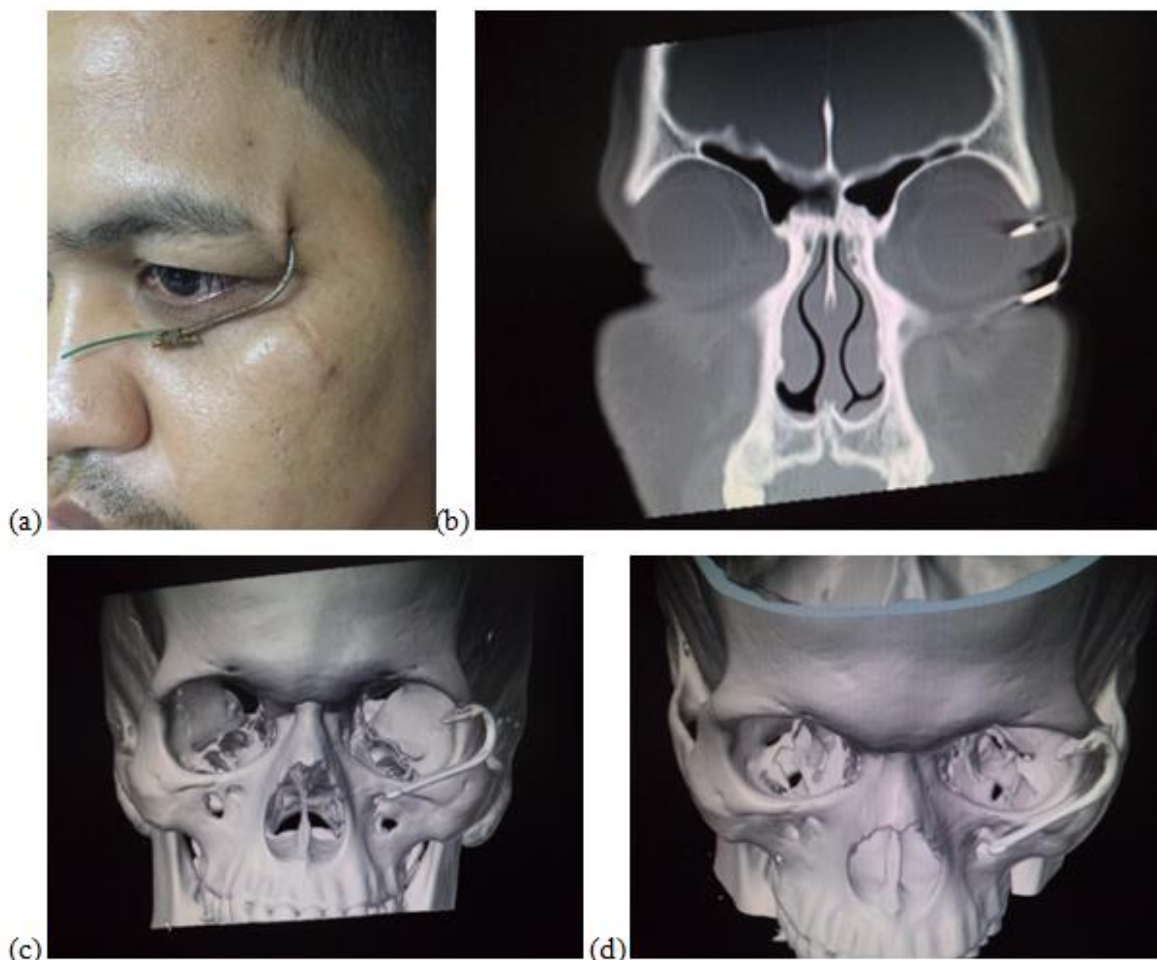
Fig-4: Fish-hook removed under “Needle Cover” method

CASE 3

A 26-year-old man, presented with a fish-hook accidentally hit his left eye region while fishing six hours ago. He complained of left lid swelling, pain, tearing, and left eye redness. On examination, he had an unaided vision of 6/6 in both eyes. The right eye was normal. The fish-hook was embedded deeply into the lateral portion of the left upper lid near the eyebrow (Figure 5 (a)). The left eye had limited lateral gaze and increased pain on eye movement. There was mechanical ptosis due to left upper lid swelling. The left conjunctiva was mildly injected and chemotic temporally with embedded foreign body. There were also multiple small particles embedded into deep corneal stroma paracentrally but did not enter the anterior chamber. Intraocular pressure and posterior segment were unremarkable. Intramuscular booster dose of tetanus toxoid (0.5ml) and intravenous ciprofloxacin (200mg twice daily) were given. Computed tomography (CT) of orbit showed the fish-hook was embedded in the left orbit with possible

penetration of the tendinous insertion of the lateral rectus (Figure 2 (b) – (c)).

Exploration was done under general anaesthesia and the fish-hook was removed using “Wound Enlargement and Exploration” method. A skin incision was made temporally near the fish-hook entry wound; deeper structures were dissected, identified, and secured. Intraoperatively, noted the fish-hook had passed beyond the orbital rim and was embedded in the subcutaneous tissue. Fortunately the lateral rectus and sclera were intact. The conjunctival and corneal foreign bodies were removed. The wound was sutured. The patient was started on topical ciprofloxacin 0.3% four hourly and topical dexamethasone 0.1% four times per day. After 3 days of intravenous ciprofloxacin, the patient was allowed home with oral ciprofloxacin. Topical medications were continued. The patient was reviewed in 1 week for removal of the skin sutures. The wound healed well.



**Fig-5: (a) Fishhook embedded in the upper lid near the eyebrow
(b) CT orbit showing tip of fishhook in close proximity with the globe
(c) & (d) 3D reconstruction of CT showing position of the fishhook relative to orbital rim**

DISCUSSION

Fish-hook injuries usually involve the lids or anterior segment of the eye. Important prognostic factors are the time elapsing between the injury and the surgical repair, the site and severity of the injury, the level of contamination at the wound site, and the type of fish-hook [1]. There are various methods of fish-hook removal [1-6] with their advantages and disadvantages

summarized in Table 1. Hook designs, location, depth of penetration, involved ocular structures, extent of available visualization, surgical instruments availability, and the comfort of the surgeon with various techniques are factors to be considered before choosing a method of hook extraction [4, 7]. The aim is to minimize additional tissue damage and scar formation.

Table-1: Comparison of fish-hook removal methods [1-6]

Method	Advantages	Disadvantages
Retrograde / Back-out	Mainly used for superficially located barbless hooks	High failure rate. If barbed hook is simply dragged backwards with the barb in situ, it can cause excessive tissue damage.
String-yank	Usually used as first line method in body parts other than eyes. No surgical tools needed.	Cannot be performed on mobile body parts (e.g., earlobe). Could be traumatic, not advisable for cases involving the eye.
Advance and Cut	Almost always successful. Surgically controlled second wound. No enlargement of the primary wound. Minimal traumatic manipulation. Most effective when the point of the fishhook is located near the surface. Could be used for relatively large fish-hooks.	May not be suitable for hooks with shank having more than one barb. Not advocated in cases where these hooks are embedded up to the shank. Requires additional manipulation of the hook in cases involving the anterior chamber, especially if the proximal end is short. Some further tissue damage inevitable.
Needle Cover	Useful for superficial embedded large single barbed hook. Could be used in posterior segment penetrating fishhook injuries.	Some further tissue damage inevitable. Not suitable for large hook where no needle of suitable gauge available.
Wound extension & exploration / Cut-it-out	For deeply embedded hook or hook with multiple barbs. For cases with limited visualization.	More tissue damage.
Cut-and-push-through	Can minimize damage in cases in which proximal end was too short for a safe advance-and-cut technique.	Some further tissue damage inevitable.

“Advance and Cut” method was used in Case 1 as advancing the fish-hook through the lid skin and cutting the barb resulting in more controlled tissue damage compared to other methods. “Needle Cover” method was not suitable as the fish-hook was embedded relatively deep into the tarsal plate. “Retrograde” method was unlikely to be successful as the barb prevented retrograde movement and forcing it would cause more tissue injury. Superficial embedded fish-hook in the conjunctiva enabled successful application of “Needle Cover” method in Case 2. Wound extension and exploration method had to be used in Case 3 as the fish-hook was embedded deeply into the orbit with high possibility of deep structures involvement.

It is advisable to postpone full examination of the globe if the patient is not co-operative or is a child (as in Case 2). Proper examination in such situation could be done under general anaesthesia during the removal of the fish-hook in operating-theatre. Eye shield and immobilization of the fish-hook also are important as these help to prevent further damage to the eyes before fish-hook removal [8]. Selection of types of anaesthesia for fish-hook removal is determined by the

patient’s ability to co-operate and the expected difficulty level in removing the fish-hook. Local anaesthesia was used in Case 1 as the patient was a co-operative young adult. Fish-hook was removed under general anaesthesia in Case 2 as the patient was a child, and in Case 3 as expecting more complicated removal process due to the involvement of deeper and more structures.

Infection control is essential for superior outcome in fish-hook related injuries [7]. As fish-hook will cause open wound, a booster for tetanus vaccination is recommended if it has been more than five years since the last booster [5] or in a patient with unknown past immunization status. Patients in all three cases were given tetanus toxoid. Broad spectrum antibiotics are prescribed in fish-hook injuries as fish-hooks are likely to be contaminated by various baits used and water pathogens [7, 9]. Only topical antibiotics were given in Case 1 as it was a relatively clean case with small puncture wound; and the patient was an adult capable of proper hygiene and compliance with topical medications. Systemic antibiotic was given in Case 2 as the patient was a child of doubtful

compliance with hygiene and medication instruction; and also longer wait for adequate fasting before operation under general anaesthesia. Patient in Case 3 also was prescribed systemic antibiotic in view longer time elapsed before surgery (i.e. six hours had passed at presentation and the need for adequate fasting time before general anaesthesia), and the involvement of multiple structures (lid, conjunctiva and cornea). The use of steroid in eye trauma with open wound is controversial and need to be tailored accordingly to minimize the risk of infection. Low dose of steroid was given in Case 2 when anterior chamber reaction developed post surgery; and in Case 3 to reduce inflammation in view of multiple structures involvement. A balance needs to be achieved between inflammation and infection control. If residual scarring can be minimized (especially when cornea is involved) without increasing the risk of infection, then visual prognosis may be further improved [7].

Radioimaging like CT scan is useful in cases suspecting intraocular or intraorbital foreign bodies [10]. CT scan and three-dimensional reconstruction could accurately demonstrate the location of deeply embedded foreign body like fish-hook in relation to other structures. This will assist in the evaluation of suitable surgical approaches, difficulty level of extraction, and related tissue destructions. In Case 3, CT scan was done to help assess the extent of possible injury caused by the deeply embedded fish-hook; and allow for better extraction planning. Magnetic resonance imaging could not be used to better delineate soft tissue involvement as fish-hook is a metallic foreign body.

Many people are unaware that wearing protective eyewear made of polycarbonate during fishing is actually recommended [1, 11]. Sunglasses or prescription spectacles are not an adequate substitute for protective eyewear [12]. Spectacles pose a risk for injury to the wearer when the lens shattered due to impact of high speed fish-hooks and weights. If both anglers and onlookers would wear protective eyewear during fishing trips, many blinding injuries could be prevented [4, 13]. Public education is important in increasing the awareness of the dangers posed by fishing. Promotion of importance and distribution of safety information regarding protective eyewear during fishing could be carried out through fishing equipment stores and government bodies regulating the fishing license and boater registration [13]. On the other hand, clinicians involved in the removal of fish-hook from eyes or other parts of patients also should wear suitable protective eyewear to avoid accidental ocular injury to themselves [5, 8].

CONCLUSION

Related injuries, type and position of the fish-hook are factors to be considered in selecting the proper method for fish-hook removal. Eye shield,

immobilization of the fish-hook until removal, and infection control are important to avoid further insults to the eye. CT scan can assist in the assessment of hook position and related injuries in cases involving deeply embedded fish-hook; and allow for better surgical approach planning. Prevention of eye injury with protective eyewear during fishing should be advocated.

DISCLAIMER

Care has been taken to confirm the accuracy of the information presented. However, the authors, editors, and publisher assume no responsibility or liability for any errors or omissions in this manuscript, or for the consequences of any action taken on the basis of the information provided herein. Any views and opinions presented in this manuscript are solely those of the authors and do not necessarily represent those of affiliated institutions.

REFERENCES

1. Yildirim N, Kabadere E, Ermis Z. Perforating corneal injury with a fish hook. *Ophthalmic Surgery, Lasers & Imaging*. 2008;39(2):137-9.
2. Ahmad SS, Seng CW, Ghani SA, Lee JF. Cut-it-out technique for ocular fish-hook injury. *Journal of Emergencies, Trauma & Shock*. 2013;6:293-5.
3. Bartholomew R, Macdonald M. Fish hook injuries of the eye. *British Journal of Ophthalmology*. 1980;64(7):531-3.
4. Chao DL, Erickson BP, Rachitskaya AV. Penetrating Ocular Fishhook Injury. *JAMA ophthalmology*. 2015;133(3):347-8.
5. Gammons M, Jackson E. Fishhook removal. *American family physician*. 2001;63(11):2231-8.
6. Knox FA, Chan WC, McAvoy CE, Johnston SE, Bryars JH. Penetrating Ocular Injuries from Fish-hooks. *International Ophthalmology*. 2004; 25(5):291-4.
7. Aiello LP, Iwamoto M, Guyer DR. Fish-hook Injuries. *Ophthalmology*. 1993;100(1):3-4.
8. Hoskin AK, Yardley A-ME, Mackey DA. Recreational fishing eye injuries and eye protection. *Acta Ophthalmologica*. 2015; 93(8):e678.
9. John ES, Krishnan A, George T. Fish Hook Injury. *Kerala Journal Of Ophthalmology*. 2007;19(4):446-7.
10. Fulcher TP, McNab AA, Sullivan TJ. Clinical features and management of intraorbital foreign bodies. *Ophthalmology*. 2002;109(3):494-500.
11. Raynor LA. Eye protection for anglers. *The New England journal of medicine*. 1982;307(15):954.
12. Sinclair SA, Smith GA, Xiang H. Eyeglasses-related injuries treated in US emergency departments in 2002–2003. *Ophthalmic epidemiology*. 2006; 13(1):23-30.
13. Alfaro DV, Jablon EP, Rodriguez Fontal M, Villalba SJ, Morris RE, Grossman M, et al. Fishing-related ocular trauma. *American Journal of Ophthalmology*. 2005;139(3):488-92.