

## Unilateral Macular Coloboma

Masatoshi Onda, Shinji Makino\*

Department of Ophthalmology, Jichi Medical University, Shimotsuke, Tochigi 329-0498, Japan

**\*Corresponding author**

*Shinji Makino*

**Article History**

Received: 23.08.2018

Accepted: 04.09.2018

Published: 30.10.2018

**DOI:**

10.36347/sjmcr.2018.v06i10.011



**Abstract:** A 6-year-old girl was referred for the evaluation of a macular lesion in the right eye. Fundus examination of the right eye showed a sharply-demarcated, round-shaped, excavated macular lesion. Optical coherence tomography (OCT) showed a crater-like depression accompanying atrophic retina, and an absence of retinal pigment epithelium and choroid in the lesion. The patient was diagnosed as having macular coloboma. The diagnosis of macular coloboma can potentially be made solely on clinical grounds; however, OCT is beneficial to confirm the diagnosis.

**Keywords:** Macular coloboma, Optical coherence tomography.

### INTRODUCTION

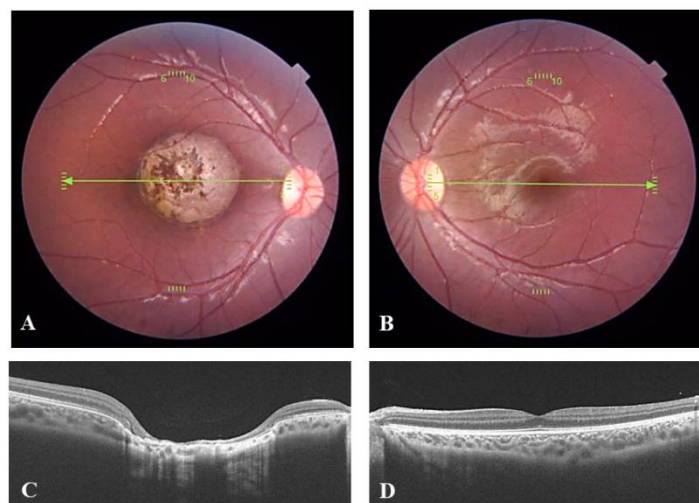
Ocular coloboma, defined as an absence of ocular tissue resulting from a failure of a part of the fetal fissure to close, is classified as atypical when it involves areas of the eye that do not originate from the embryonic cleft [1].

Congenital macular coloboma appears as atrophic lesions with well-circumscribed borders unilaterally or bilaterally, which result in a nonprogressive decrease in visual acuity [1-4]. Optical coherence tomography (OCT) is a beneficial tool to make a diagnosis of macular coloboma. We report on the OCT findings in a patient with unilateral macular coloboma.

### CASE REPORT

A 6-year-old girl was referred for the evaluation of a macular lesion in the right eye. Her visual acuities were 0.09 OD and 1.2 OS. Fundus examination of the right eye showed a sharply-demarcated, round-shaped, excavated macular lesion

(Figure 1A). OCT showed a crater-like depression accompanying atrophic retina, and an absence of retinal pigment epithelium (RPE) and choroid in the lesion (Figure 1C). Fundus examinations did not reveal any abnormalities in the left eye (Figure 1B, D). The patient was diagnosed as having macular coloboma.



**Fig-1: Fundus photographs (A, B) and optical coherence tomographic images (C, D) of the right (A, C) and left eye (B, D). A sharply-demarcated, round-shaped, excavated lesion involving the macula (A). A crater-like depression, and an absence of retinal pigment epithelium and choroid (C).**

#### DISCUSSION

This report presents a case of unilateral macular coloboma as examined by OCT. The OCT findings of this case showed absence of the retina and choroid. This structure conformed well to the findings of previous reports [2-4]. In macular coloboma, the typical changes on OCT are crater-like depression with atrophic neurosensory retina, lack of retinal pigment epithelium, choroid in the lesion, and absence of scleral ectasia. In our patient, the typical changes both clinically and on OCT confirmed the diagnosis of macular coloboma. Although macular coloboma has a characteristic appearance and location, it must be differentiated from post-inflammatory scarring resulting from ocular toxoplasmosis. In congenital toxoplasmosis, the characteristic OCT findings are retinal thinning, retinal pigment epithelium hyperreflectivity, and excavation of varying severity.

#### CONCLUSIONS

The diagnosis of macular coloboma can potentially be made solely on clinical grounds; however, OCT is beneficial to confirm the diagnosis.

**Disclosure:** The authors declare no conflict of interest.

#### REFERENCES

1. Onwochei BC, Simon JW, Bateman JB, Couture KC, Mir E. Ocular colobomata. *Surv Ophthalmol.* 2000; 45:175-194.
2. Abe K, Shirane J, Sakamoto M, Tanabe F, Kuniyoshi K, Matsumoto C, Shimomura Y. Optical coherence tomographic findings at the fixation point in a case of bilateral congenital macular coloboma. *Clinical ophthalmology (Auckland, NZ).* 2014;8:1017.
3. Oh JY, Yu YS, Hwang JM, Park KH: Optical coherence tomographic finding in a case of macular coloboma. *Korean J Ophthalmol.* 2007; 21: 175–177.
4. Hussain N, Mohan Ram LS: Optical coherence tomographic features of unilateral macular coloboma. *Indian J Ophthalmol.* 2007; 55: 321–322.