

Giant Retroperitoneal Tumor: An Unusual Localization of Malignant Peripheral Nerve Sheet Tumor

Taous H, Zahdi O*, Hormat-Allah M, Bakkali T, Sefiani Y, Lekehal B, El Mesnaoui A, Bensaid Y

Vascular surgery department; Ibn Sina University Hospital Centre, 10104 Souissi, Rabat, Morocco

***Corresponding author**

Zahdi O

Article History

Received: 16.10.2018

Accepted: 27.10.2018

Published: 30.10.2018

DOI:

10.36347/sjmcr.2018.v06i10.033



Abstract: Malignant peripheral nerve sheath tumors (MPNST) are considered a rare entity, especially in the retro peritoneum. We report the case of a 32 years old woman, with the history of Von Recklinghausen disease, who presented a MNPST of 14,5 cm of diameter at the retroperitoneal cavity. There was no specific clinical symptom besides an abdominal swelling. The MRI showed a heterogeneous retroperitoneal mass that represses without invading the adjacent structures. We've conducted a mass resection without any adjuvant radio or chemotherapy. No sign of local recurrence was detected after one year follow up.

Keywords: retroperitoneal mass; von Recklinghausen disease; peripheral nerve sheet tumor.

INTRODUCTION

Malignant peripheral nerve sheath tumors (MPNST) are rare tumors, mainly found during the evolution of Von Recklinghausen's disease or neurofibromatosis type 1 (NF1).

They usually develop in the head, neck and limbs. The peritoneal localization is rarer. We describe the case of a patient followed for NF1 who presents a retroperitoneally located MPNST

CASE REPORT

A 32 years old moroccan women, Coming from a non-consanguineous marriage, followed for NF1 since childhood. She had a presented an abdominal swelling on the left side with left lumbar pain that had been evolving for a year.

Clinical examination revealed a tumefaction of the left iliac fossa that was firm and painless. In addition, there are many « coffee spots » in the limbs and trunk, and ephelides in the axillary troughs. The patient had no sensorimotor deficit or neuralgia.

Ultrasound showed the presence of a left retroperitoneal mass of heterogeneous content. Abdominopelvic MRI revealed the presence of a heterogeneous, predominantly cystic left peritoneal mass, highly enhanced after injection of contrast medium. It measures 10x10cm on the axial plane for

14,5cm of height. Although limited, it represses without invading up the kidney, inside the aorta and the vena cava and forwards the peritoneal contents.

It comes into contact with the vertebral bodies and the left lumbar roots without detectable intraforaminal extension or abnormalities of the adjacent vertebral bodies. The psoas appears repressed forwards and inwards. The patient underwent mass resection by a left peritoneal approach after locating the ureter and respecting the crural nerve.

The histology was in favor of a malignant tumor of ducts and peripheral nerves (MPNST) with high grade malignancy on a neurofibroma. No adjuvant treatment was indicated. The postoperative course was uneventful and the patient was discharged a week later. The patient has no recurrence after 1 year of follow-up.

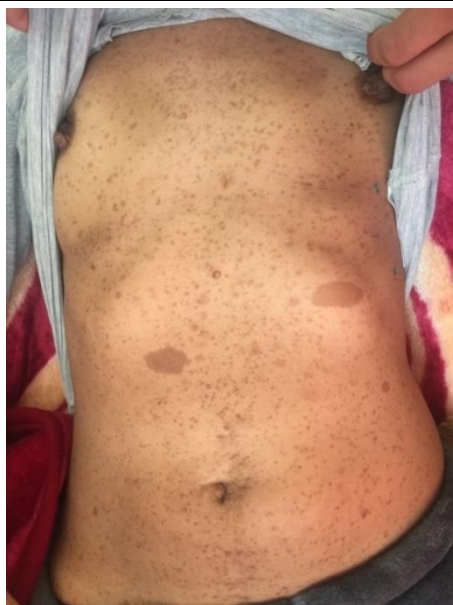

Fig-1: Dermatological lesion typical of Von Recklinghausen's disease “tâches café au lait”

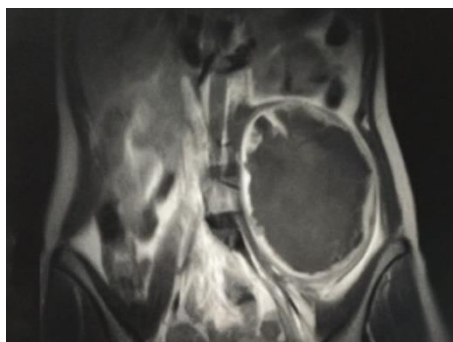


Fig-2: frontal view of the retroperitoneum showing the repression of the kidney and the left adrenal gland

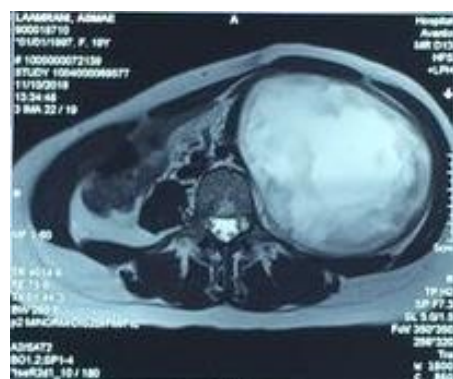


Fig-3: axial view of retroperitoneum showing the heterogeneous aspect of the tumor

DISCUSSION

Malignant tumors of the sheaths of peripheral nerves formerly called malignant schwannomas are rare tumors. They represent 5 to 10% of soft tissue tumors [1]. Their incidence is 0.001%, in the general population [2, 3, 11], and 4.6% in case of Von Recklinghausen disease [2]. There is also a high incidence in patients who have received prior radiotherapy [2, 4, 7]. MPNST occurs in the third and fourth decade for patients treated for NF1 and in the

sixth and seventh decade for sporadic cases [3, 9]. The sex ratio is a 1 [4].

They are located more frequently in the limbs, mainly affecting the sciatic nerve [2, 4, 5], then the trunk and then the head and neck [5]. Only 1% of MPNST is retro-peritoneal [6]. At this location, they develop from the lumbar or sacral plexus but the original nerve remains difficult to identify intraoperatively [3]. Nambisan *et al.* identified only

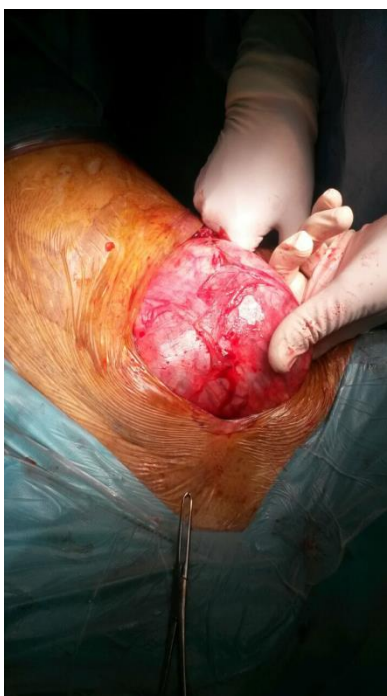

Fig-4: per-operative image of the extraction of the retroperitoneal mass

MPNSTs develop DE NOVO or from preexisting neurofibromas [7, 8]. The latter are the most common benign tumors in NF1 carriers, leading to the search for an MPNST on each neurofibroma that becomes symptomatic [9].

MPNST can manifest as pain, signs of compression of neighboring organs [1, 3, 5] or neurological signs affecting the territory of the affected nerve [2]. Asymptomatic forms are not uncommon. The diagnosis of these lesions can be delayed because of the lack of specific clinical and biological signs [6, 10, 11], especially with retro peritoneal localization, thus allowing the tumor to reach large volumes. The average size of discovery at this location is 8cm in diameter [1].

MRI is the gold standard for preoperative exploration of these tumors [7]. The positive diagnosis of MPNST is difficult and delicate [6; 7], requiring, alongside morphological, immunohistochemical and molecular criteria, the presence of one of the criteria identified by WHOM:

- Either the tumor is developed from a peripheral nerve
- Either the tumor is developed from a benign tumor of the nerve sheaths
- Either the tumor is developed in a patient with neurofibromatosis type1 (NF1) [5; 6]
- In their absence, the diagnosis of MPNST suffers from a lack of specificity [5]
- The standard treatment consists of surgical resection of the tumor with wide margins of safety to reduce the risk of local recurrence and distant

metastases [1; 3; 7]. radiotherapy and chemotherapy are not recommended. They do not improve long-term survival [1]; especially in patients followed for NF1 who may develop a radiation-induced sarcoma. However some authors use them in case of locally advanced tumor [5].

In our case, we limited to a surgical resection without any adjuvant treatment. Local recurrence of MPNST occurs on average at 30 months on average in sporadic cases and 9.4 months on average in NF1 cases, despite this high rate of recurrence, there is no well-defined protocol for postoperative follow-up. sick [1].

Remote metastases are haematogenous. The most frequently encountered are those of the lung, bone and pleura [5, 7, 9]. The ganglionic involvement is exceptional and must make reevaluate the histological diagnosis [5].

CONCLUSION

We have described a rare location of an MPNST in a patient followed for NF1. The prognosis of the disease corresponds to the quality of the surgical resection. But the low symptomatic nature of these tumors delays the diagnosis, resulting in the discovery of voluminous tumors of difficult surgery.

RÉFÉRENCES

1. Yan B, Meng X, Shi B, Shi J, Qin Z, Wei P. A retroperitoneal NF1-independent malignant peripheral nerve sheath tumor with elevated serum

- CA125: case report and discussion. *Journal of neuro-oncology*. 2012 Aug 1;109(1):205-11.
2. Ducatman BS, Scheithauer BW, Piegras DG, Reiman HM, Ilstrup DM. Malignant peripheral nerve sheath tumors. A clinicopathologic study of 120 cases. *Cancer*. 15 mai 1986;57(10):2006-21.
 3. Alraies MC, Tripathy P, Chaar A, Baibars M, Alraiyes AH. Retroperitoneal malignant nerve sheath tumor. *QJM*. 1 nov 2013;106(11):1051-3.
 4. Hruban RH, Shiu MH, Senie RT, Woodruff JM. Malignant peripheral nerve sheath tumors of the buttock and lower extremity. A study of 43 cases. *Cancer*. 15 sept 1990;66(6):1253-65.
 5. Le Guellec S. Les tumeurs des gaines des nerfs périphériques. *Annales de Pathologie*. janv 2015;35(1):54-70.
 6. Deger AN, Bayar MA, Caydere M, Deger H, Tayfur M. Retroperitoneal Malignant Peripheral Nerve Sheath Tumour: A Rare Case Report. *J Clin Diagn Res*. sept 2015;9(9):ED09-ED11.
 7. Alavi S, Arzanian MT, Nilipour Y. Retroperitoneal Malignant Peripheral Nerve Sheath Tumor Replacing an Absent Kidney in a Child. *Case Reports in Oncological Medicine*. 2013;2013:1-4.
 8. Coulon A, Milin S, Laban E, Debiais C, Jamet C, Goujon J-M. Aspects histopathologiques des principales tumeurs des nerfs périphériques. *Neurochirurgie*. oct 2009;55(4-5):454-8.
 9. Anderson JL, Gutmann DH. Neurofibromatosis type 1. *Handbook of Clinical Neurology*. 1 janv 2015;132:75-86.
 10. Xu H, Sha N, Li HW, Bai M, Chen X, Hu HL, Wu CL. A giant pelvic malignant schwannoma: a case report and literature review. *International journal of clinical and experimental pathology*. 2015;8(11):15363.
 11. Meng ZH, Yang YS, Cheng KL, Chen GQ, Wang LP, Li W. A huge malignant peripheral nerve sheath tumor with hepatic metastasis arising from retroperitoneal ganglioneuroma. *Oncology letters*. 2013 Jan 1;5(1):123-6.