

Tuberculous Sacroiliitis Revealed By a Pathological Fracture: A Case ReportT. Madani^{1*}, Driss. Jeddi¹, L. El'otmani, A. Bardouni¹, M.Ouadghiri¹, M. Kharmaz, MO. Lamrani¹, M. Mahfoud, MS. Berrada¹, Dr. Madani Tarik²¹Department of Orthopaedic surgery and Traumatology, Ibn Sina hospital, Rabat, Morocco²Mohamed V university of Rabat, CHU Ibn-sina, Morocco***Corresponding author**

T. Madani

Article History

Received: 03.07.2018

Accepted: 12.07.2018

Published:30.08.2018

DOI:

10.36347/sjmcr.2018.v06i08.012

**Abstract:** Tuberculous sacroiliitis is a rare infection; the beginning of symptoms is usually insidious. Tuberculous sacroiliitis is difficult to explore due to the depth of the sacroiliac joint however it has benefited recently from the progress of radiology's imaging which enhances the average diagnosis time. Medical treatment of tuberculous sacroiliitis is most often sufficient. We report a rare case of tuberculous sacroiliitis of a 70 years old patient revealed by a pathological fracture.**Keywords:** Tuberculosis, sacroiliitis, fracture.**INTRODUCTION**

Tuberculous sacroiliitis is a rare infection but can be responsible for a clinical symptoms often misleading. The diagnosis is frequently established late, sometimes because of confusion with hip involvement or of the lumbosacral hinge.

THE CASE REPORT

We report a case of a patient of 70 years old, without pathological antecedents unless a notion of tuberculous contagion in the family. Complains since about 1 year of lumbago associated with left gluteal pain in prolonged sitting position. With a partial functional impotence of the lower limb at the beginning then became total in a few weeks, we noticed also a recent weight loss, without fever.

RESULTS

Physical examination revealed pain at pressing of the iliac wings and the left sacroiliac joint. The mobility of the hips was normal. Faberge's tests (flexion, abduction and external rotation of the hip) and Gaenslen (hip extension) are positive. The biological analysis shows a speed of sedimentation at 50 mm in the first hour, and a C reactive protein at 82 g / l.

The X rays of the pelvis shows condensation of left sacroiliac joint margins with ascension of the left hemi pelvis and a pathological fracture of the iliac wing (Figure 1). The scanner confirms the bone remodeling with destruction and an articular enlargement (Figure 2) associated with a collection of gluteal soft parts and left

psoas muscle (Figure 3), complicated with pathological fracture of the left iliac wing .

The drainage of the collection brings a purulent fluid with, on direct examination and culture, mycobacteria (Mycobacterium tuberculosis). Surgical biopsy of the iliac wing (at pathological fracture) and sacroiliac joint was performed; histological examination shows a morphological aspect of case follicular tuberculosis.

Search for other localizations of tuberculosis was negative. The patient receives antibiotic therapy of a total duration of 6 months, with a good clinical and radiological evolution.

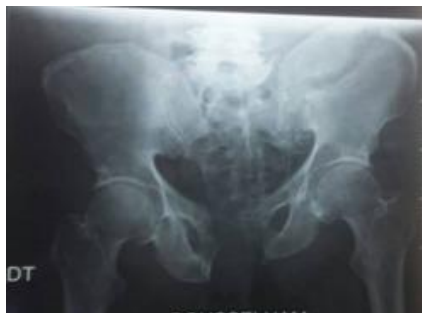

Fig-1: X rays of the pelvis shows condensation of left sacroiliac joint margins with ascension of the left hemipelvis and a pathological fracture of the iliac wing

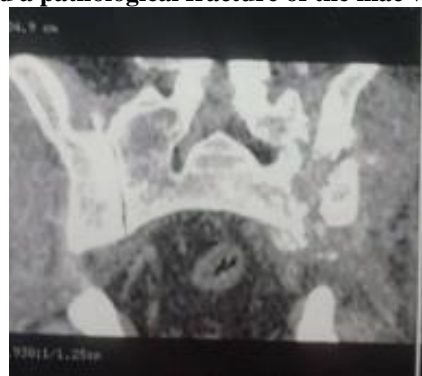


Fig-2: TDM: the bone remodeling with destruction and an articular enlargement

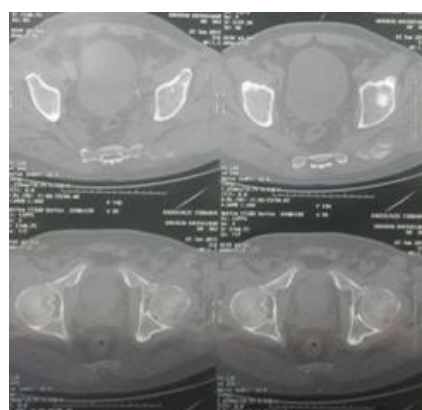


Fig-3: Abscess of gluteal soft parts and left psoas muscle

DISCUSSION

Tuberculous sacroiliitis represents 5 to 57% of infectious sacroiliitis. They correspond to 0.4 21% of osteoarticular tuberculosis. They mainly affect the young adult. Middle age at the time of diagnosis is 31 years old [1,3]

The beginning of symptoms is usually insidious it is marked by the appearance of an inflammatory pain [1, 2]. It can evolve insidiously and to be at the origin of discrete symptoms especially when isolated, without abscess [3, 5]. The average diagnosis time is 5.5 months in the literature [6]. Functional signs are walking difficulty, gluteal pain or even radiculalgia in lower limbs or lower back pain. General signs are dominated by fever, which is moderate and inconstant [1, 3, 5, 6].

Sacroiliac involvement is usually unilateral; however, bilateral localizations have been described. Tuberculous abscesses are most often found in the gluteal region and the psoas muscle [2,4], as in our case but can also found in the Scarpa's triangle or the iliac fossa.

Radiological signs appear after several months, because of the slow evolution and anatomical features of the sacroiliac joint. The evolution is then towards a synostosis [5, 7].

CT or MRI is the best means for the exploration of the sacroiliac joint. They allow visualizing possible abscesses intra pelvic infections or the presence of intraarticular sequestra particularly difficult to see on standard X rays.

MRI is more sensitive and allows early diagnosis [6, 7]. Various antibiotic treatment protocols have been proposed: long protocols (12-18 months) have been advocated but, currently, the short protocols have proven their effectiveness and are advised by WHO, particularly in endemic countries, in order to avoid the appearance of resistance [7,9]. Long-term protocols should be recommended for subjects with history of tuberculosis or bone massive destruction.

Surgical treatment may be performed to drain an abscess, or arthrodesis in case of major destruction. The prognosis of tuberculous sacroiliitis is good at the condition of early management, before the appearance of articular destruction [8,9].

CONCLUSION

The sacroiliac joint is deep and difficult to explore but has benefited recently from the progress of radiology's imaging. Medical treatment of tuberculous sacroiliitis is most often sufficient.

DECLARATION

The authors declare that they have no conflict of interest.

REFERENCES

1. Bouajina E, Harzallah L, Hachfi W, Slama KB, Rammeh N, Ghannouchi M, Bahri M, Letaief A. Sacro-iliites tuberculeuses: à propos de 22 cas. La revue de médecine interne. 2005 Sep 1;26(9):690-4.
2. Benchakroun M, El Bardouni A, Zaddoug O, Kharmaz M, Lamrani MO, El Yaacoubi M, Hermas M, Wahbi S, Ouazzani N, El Manouar M. Tuberculous sacroiliitis. Four cases. Joint Bone Spine. 2004 Apr 1;71(2):150-3.
3. Pouchot J, Vinceneux P, Barge J, Boussougant Y, Grossin M, Pierre J, Carbon C, Kahn MF, Esdaile JM. Tuberculosis, of the sacroiliac joint: clinical features, outcome, and evaluation of closed needle biopsy in 11 consecutive cases. The American journal of medicine. 1988 Mar 1;84(3):622-8.
4. Molimard M, Hirsch A, Chretien J. Tuberculose : une nouvelle priorité. Presse Med. 1994;23:1166-71.
5. Brucker G, Bletry O, Danis M, Herson S, Gentilini M, Godeau P. Clinique et diagnostic de 7 cas de tuberculose sacroiliaque : apport de la scintigraphie osseuse. Sem Hop. 1980;56:1891-4.
6. Schute L. Unilateral tuberculous sacroiliitis. Deutsche medizinische Wochenschrift (1946). 1991 Jul 12;116(28-29):1124.
7. Chen WS. Chronic sciatica caused by tuberculous sacroiliitis. A case report. Spine. 1995 May;20(10):1194-6.
8. Pertuiset E, Beaudreuil J, Horusitzky A, Liote F, Kemiche F, Richette P, Clerc-Weyl D, Cerf-Payrastre I, Dorfmann H, Glowinski J, Crouzet J. Nonsurgical treatment of osteoarticular tuberculosis. A retrospective study in 143 adults. Revue du rhumatisme (English ed.). 1999 Jan;66(1):24-8.
9. Lejeune E, Bouvier M, Llorca G, Andre Fouet E, Dubreuil C. Traitement médical de la tuberculose ostéo-articulaire. Rev Rhum Mal Osteoartic .1981;48:171-80.