

Unusual Football Injury: Talonavicular Dislocation

Lamkhanter A*, Jalal Y, El Ghou N, Zadoug O, Ouzaa MR, Antri I, Bouya A, Elghazoui A, Bennis A, Benchekroune M, Zine A, Tanane M, Jaafar A

Department of Orthopedic Surgery and Traumatology I, Mohammed V Military Training Hospital of Rabat, Faculty of Medicine and Pharmacy of Rabat, Mohammed V University of Rabat, Morocco.

***Corresponding author**

Lamkhanter A

Article History

Received: 23.09.2018

Accepted: 04.09.2018

Published:30.09.2018

DOI:

10.36347/sjmcr.2018.v06i09.009



Abstract: Authors report a case of an 22- year-old footballer player who had experienced a talonavicular dislocation in a which occurred during a soccer game, to discuss in details the mechanism of such an injury and to highlight the importance of prompt closed reduction and early mobilization to ensure a satisfactory long-term outcome.

Keywords : talonavicular joint, dislocation, sport.

INTRODUCTION

Dislocation of the tarsal navicular is an uncommon injury, which accounts for only an estimated 1–2% of all joint dislocations, making it one of the rarest forms of orthopedics injuries [1]. It is characterized by dislocation of the talonavicular joint, but the calcaneocuboid joint remains intact. Patients presenting with this injury are mostly young, with an average age of 37 years (range, 14–89 years). Many of these dislocations results from high-energy injuries such as a fall from a height, or a motor vehicle accident, and usually associated with concomitant fracture in upwards of 75-90% [2]. However, it is not commonly seen as a sports injury. Prompt recognition and early reduction is necessary to obtain optimal results and to avoid complications.

We report a case of medial talonavicular dislocation in a 22- year-old footballer player, which occurred during a soccer game.

OBSERVATION

-A 22-year-old man presented to the emergency department with a painful left foot after a fall during a soccer game. He sustained this injury after landing on the ground with his foot abducted and everted. Local examination noticed a bony prominence on dorso-medial aspect of the left foot along with medial displacement of the foot on the head of talus with mild edema (fig.1). Pulse of the posterior tibial and dorsalispedis artery were present but weak. Standard radiographs, including anteroposterior, lateral views were done, which showed isolated medial dislocation of the talonavicular (fig.2). The CT scanning was not available.

Closed reduction was done under spinal anesthesia. Reduction was achieved by traction on the forefoot, with the foot held pronated and flexed, and manual pressure on the head of the talus, followed by adduction and dorsiflexion which was associated with an audible clunk. Confirmation of successful reduction was done under image intensifier. During stress

examinations, the reduction remained unstable and percutaneous K-wire fixation of the talonavicular joint was done (fig.3). The patient was placed into a non-weight-bearing cast for 6 weeks, followed by a weight-bearing cast for 2 weeks. K-wire was removed at 6 weeks and gradual physiotherapy of ankle, subtalar as well as mid-tarsal joints started. Gradual weight bearing was started. The patient was followed up at 6months and 2 years. At the last follow-up examination, he had mild to severe pain on the medial side of the foot during walking for long distances and upon forced inversion of the foot. There was no limitation of movement of the ankle joint, but the range of motion of the subtalar joint was diminished 20% compared with the right side. X-rays taken 2 years after injury showed arthritis of the talonavicular joint (fig.4,5). The patient cannot return to his activities as a footballer player and he did not agree to undergo arthrodesis. His pain was successfully managed by an infiltration of corticosteroids and the patient was employed as a manual worker in the same team.

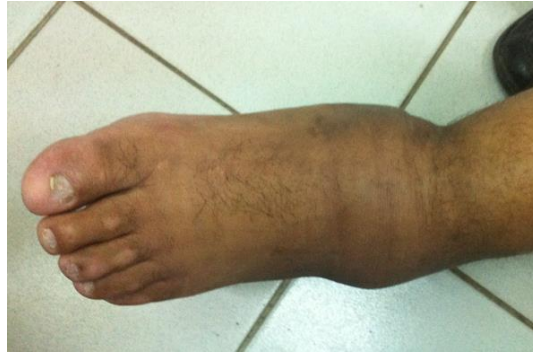

Fig-1: Clinical appearance of a talonavicular dislocation with medial displacement of the foot on the head of talus with mild edema

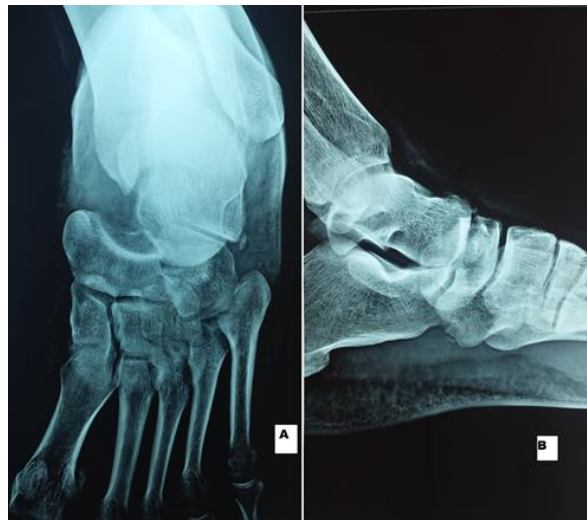


Fig-2: (A,B): anteroposterior and lateral views of the left ankle showed isolated medial dislocation of the talonavicular

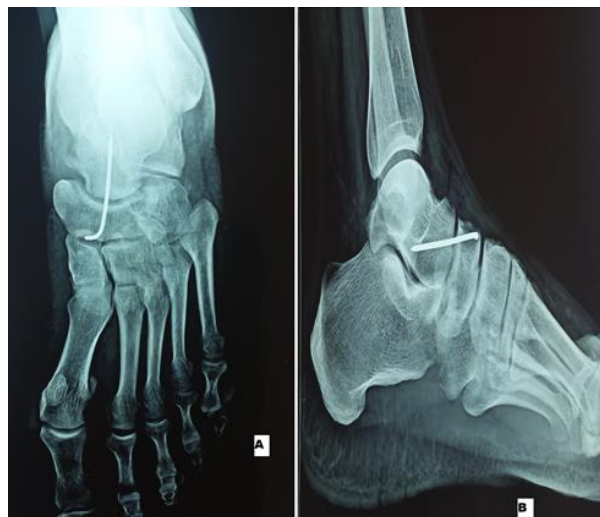

Fig-3(A,B): anteroposterior and lateral views after closed reduction and percutaneous fixation with wire of medial talonavicular dislocation

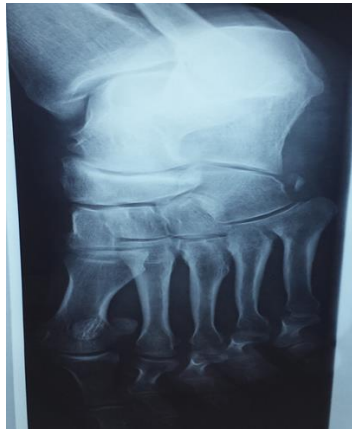

Fig-4

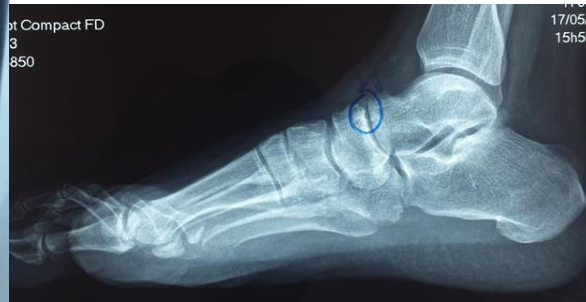

Fig-5

Fig-(4,5): anteroposterior and lateral views of the left ankle 2 years after injury showed arthritis of the talonavicular joint

DISCUSSION

Talonavicular dislocation occurring during soccer game is uncommon. The rarity of this injury can be attributed to the rigid bony and ligamentous support surrounding the navicular, which usually undergoes fracture and dislocation rather than pure dislocation of the navicular [3]. Such injuries are usually caused by a severe abduction or adduction force exerted to the forefoot. In our case, the mechanism of injury was axial compression with forceful dorsiflexion of the left foot. The following sports and activities have a relatively high risk of navicular injury: sports involving jumping and sprinting-basketball, soccer, football, and rugby [4]; ballet and other dancing activities, and gymnastics [5]. Depending on the direction of the applied force and the direction of displacement of the forefoot, Main and Jowett [6] described five patterns of midfoot injury: medial force with medial displacement, longitudinal force with impaction and twisting, lateral force with lateral displacement, plantar force with plantar displacement, and crush injury.

Patients with injuries at the Chopart joints display a wide range of clinical symptoms ranging from localized pain that is exaggerated by weight bearing, to severe swelling and hematoma over the midfoot.

Four standard projections seem to be essential for the immediate evaluation: the dorsoplantar, the lateral, the oblique from dorso-lateral to plantar-medial, and the Brode'n views. Two important marker of midfoot injury: The talus-medial cuneiform-first metatarsal axis should be lined up on both a lateral and anteroposterior radiograph and the S-shaped Cyma line on lateral radiographs, sign of congruence of the talonavicular and calcaneocuboidal joints. In order to decrease the rate of missed fractures, and to plan future treatments CT appears helpful. Based on the radiographic, the dislocation sustained in our case is a medial swivel type.

Prompt closed reduction under anesthesia is the first line of management of such injury. It minimizes the soft tissue damage and reduces the incidence of a vascular necrosis of the talus. Different treatment methods are available; including closed reduction and open reduction with or without internal or external fixation. However, there is no clearcut superiority between them. While Shelton [7] and Pedowitz treated these injuries by open reduction because of soft tissue interposition, Main and Jowett [6] recommended closed reduction and immobilization of medial swivel±dislocations, with or without Kirschner wire fixation, such as in our case.

In open fractures and fracture-dislocations, primary treatment consists of emergent reduction of gross dislocations, copious irrigation, and generous debridement of contaminated and avital tissue. Open reduction and internal fixation is carried out, possibly by extending the existing open wound. If a primary definite internal fixation is not feasible, an approximate reduction and temporary internal and external fixation is carried out.

Arthrodesis is generally reserved for patients with residual disability [8]. After successful reduction, the foot should be immobilize in a non-weight bearing below knee cast for 4 weeks. After removal of plaster and wire, the patient progresses from partial to complete weight bearing over 6 weeks.

Complications with these injuries are numerous, frequent, and depend on the type and severity of the dislocation. Early complications are skin necrosis, deep infection, and neurovascular compromise. The frequency of these complications varies from 0% to 10% [9]. Therefore, early diagnosis and accurate reduction are essential to prevent these early complications. Late complications include avascular necrosis of the tarsal bones, osteoporosis, and posttraumatic arthritis. The latter, is the most common one.

CONCLUSION

Talonavicular dislocation is a rare condition. Its occurrence in sport is even rarer. Such injury is caused by severe abduction or adduction of the forefoot and often associated with fractures of the navicular, cuboid, or calcaneus. Prompt recognition and early reduction is necessary to obtain optimal results and to avoid complications.

REFERENCES

1. Dhillon MS, Nagi ON. Total dislocations of the navicular: are they ever isolated injuries? *J Bone Jt Surg Br.* 1999;81:881-885.
2. Rammelt S, Grass R, Schikore H, Zwipp H. Injuries of the Chopart joint. *Der Unfallchirurg.* 2002 Apr;105(4):371.
3. Ross PM, Mitchell DC. Dislocation of the talonavicular joint: case report. *The Journal of trauma.* 1976;16(5):397-401.
4. Vaishya R, Patrick JH. Isolated dorsal fracture dislocation of the tarsal navicular. *Injury* 1991;22:47-8.
5. Pathria MN, Rosenstein A, Bjorkengren AG, Gershuni D, Resnick D. Isolated dislocation of the tarsal navicular: a case report. *Foot Ankle* 1988;9:146-9.
6. Main BJ, Jowett RL. Injuries of the midtarsal joint. *The Journal of bone and joint surgery. British volume.* 1975 Feb;57(1):89-97.
7. Shelton ML, Pedowitz WJ. Injuries to the talus and midfoot. *Disorders of the Foot.* 1982;2:1463.
8. Fogel GR, Katoh Y, Rand JA, Chao EY. Talonavicular arthrodesis for isolated arthrosis 9.5-year results and gait analysis. *Foot & ankle.* 1982 Sep;3(2):105-13.
9. Kotter A, Wieberneit J, Braun W, Rüter A. The Chopart dislocation. A frequently underestimated injury and its sequelae. A clinical study. *Der Unfallchirurg.* 1997 Sep;100(9):737-41.