

## Management of a Rare Follicular Neoplasm (NIFTP)

Karam Aziz\*, Abdelouhab El Marouni, Houssam Belghali, Ahmed Zerhouni, Tarik Souiki, Karim Ibn Majdoub, Imane Toughrai, Khalid Mazaz

Visceral Surgery Service, Hassan II University Hospital, Faculty of Medicine and Pharmacy of Fez, Sidi Mohamed Ben Abdullah University, Fez, Morocco

DOI: [10.36347/SJMCR.2019.v07i10.009](https://doi.org/10.36347/SJMCR.2019.v07i10.009)

| Received: 11.10.2019 | Accepted: 18.10.2019 | Published: 30.10.2019

\*Corresponding author: Karam Aziz

### Abstract

### Case Report

A female patient was admitted for the management of a multiheteronodular goiter toxic with the histopathological examination revealed the aspect of a NIFTP. This case report allows us to discuss the diagnosis features of this condition.

**Keywords:** Goiter, NIFTP, Multiheteronodular.

**Copyright @ 2019:** This is an open-access article distributed under the terms of the Creative Commons Attribution license which permits unrestricted use, distribution, and reproduction in any medium for non-commercial use (NonCommercial, or CC-BY-NC) provided the original author and source are credited.

## INTRODUCTION

Thyroid tumors currently diagnosed as noninvasive EFVPTC have a very low risk of adverse outcome and should be termed NIFTP. This reclassification will affect a large population of patients worldwide and result in a significant reduction in psychological and clinical consequences associated with the diagnosis of cancer [1].

## CASE REPORT

A 35-years-old female, admitted to the department of visceral and endocrine surgery for the management of a multiheteronodular goiter toxic, the patient was operated, having benefited of a total thyroidectomy, the post-operative was without abnormality, histopathological examination was observed at the level of the right lobe, histologic aspect of a (NIFPT) (fig1.2)(noninvasive follicular thyroid neoplasm with papillary-like nuclear features), the patient was subsequently referred to the endocrinology department for possible biological and radiological clinical monitoring.

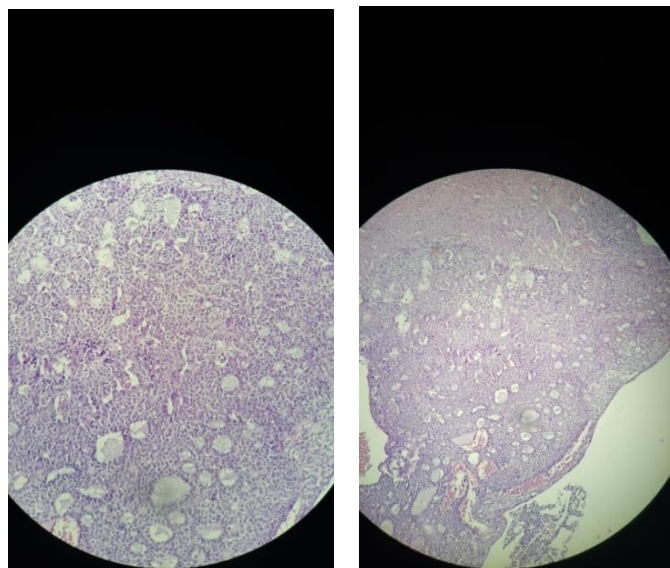


Fig-1.2: Irregular nuclear contours and chromatin clearing

## DISCUSSION

Since the term noninvasive follicular neoplasm with papillary-like nuclear features (NIFTP) was introduced, its existence has been controversial. The resultant debate has left clinicians confused as to how to counsel and follow their patients diagnosed with this entity [2].

The follicular variant of PTC was broadly recognized in the mid-1970s as a tumor composed of neoplastic follicles rather than papillae, but with follicular cells showing nuclear features characteristic of PTC [3].

Recognizing the problem of overdiagnosis and overtreatment of indolent cancers in many organs, the National Cancer Institute convened in 2012 a conference to evaluate this problem. Following the conference, a statement from a number of participants emphasized the need to revise terminology, replacing the word “cancer” when data emerge to support a more indolent designation [4].

## CONCLUSION

The adoption of a new term for variant noninvasive variant of papillary thyroid cancer, tumor indolent evolution in the vast majority of cases, could

avoid treatment in excess and not overload patients with a diagnosis of cancer and a long-term potential monitoring.

## REFERENCES

1. Nikiforov YE, Seethala RR, Tallini G, Baloch ZW, Basolo F, Thompson LD, Barletta JA, Wenig BM, Al Ghuzlan A, Kakudo K, Giordano TJ. Nomenclature revision for encapsulated follicular variant of papillary thyroid carcinoma: a paradigm shift to reduce overtreatment of indolent tumors. *JAMA oncology*. 2016 Aug 1;2(8):1023-9.
2. Parente DN, Kluijfhout WP, Bongers PJ, Verzijl R, Devon KM, Rotstein LE, Goldstein DP, Asa SL, Mete O, Pasternak JD. Clinical safety of renaming encapsulated follicular variant of papillary thyroid carcinoma: is NIFTP truly benign?. *World journal of surgery*. 2018 Feb 1;42(2):321-6.
3. Chem KT, Rosai J. Follicular variant of thyroid papillary carcinoma: a clinicopathologic study of six cases. *Am J Surg Pathol*. 1977;1(2):123-130.
4. Lubitz CC, Kong CY, McMahon PM, Daniels GH, Chen Y, Economopoulos KP, Gazelle GS, Weinstein MC. Annual financial impact of well-differentiated thyroid cancer care in the United States. *Cancer*. 2014 May 1;120(9):1345-52.