

## Endotracheal Solitary Fibrous Tumor: A Rare Discovery on Operative Piece

Souleymane Diatta\*, khady thiam, Magaye Gaye, Momar Sokhna Diop, Ndeye Fatou Sow, Pape Amath Diagne, Papa Salman Ba, Pape Adama Dieng, Amadou Gabriel Ciss, Assane Ndiaye, Mouhamadou Ndiaye

Thoracic and Cardiovascular Surgery Department, National Teaching Hospital of Fann, Dakar, Senegal

\*Corresponding author: Souleymane Diatta | Received: 02.03.2019 | Accepted: 18.03.2019 | Published: 30.03.2019  
DOI: 10.36347/sjmcr.2019.v07i03.025

### Abstract

### Case Report

Solitary fibrous tumor or pleural fibroma is a tumor of the pleura well known in its intra pleural topography. Other topographies, intrapulmonary or endobronchi exist but are particularly rare. We report the case of a benign tumor in old man with acute dyspnea. It was an endo-tracheal solitary fibrous tumor diagnosed on the operative specimen, the 5<sup>th</sup> case published to our knowledge. The aim of this report is to present, a rare pathology to evoke in the management of carcinoid tumors.

**Keywords:** solitary fibrous tumor; trachea; surgery.

**Copyright © 2019:** This is an open-access article distributed under the terms of the Creative Commons Attribution license which permits unrestricted use, distribution, and reproduction in any medium for non-commercial use (NonCommercial, or CC-BY-NC) provided the original author and source are credited.

## INTRODUCTION

Solitary fibrous tumors originate from the pleura, but they can also develop in the thorax at extra-pleural sites in 2% of cases [1]. On the other hand, the endo-bronchial form of the solitary fibrous tumor is much rarer. The analysis of the literature has identified five cases reported in the last ten years [1-3]. We report the case of a 72-year-old patient in the respiratory intensive care unit for acute respiratory distress, presenting an endotracheal tumor of undetermined nature, revealed by dyspnea-like respiratory symptoms leading to respiratory insufficiency. The complete excision of the lesion by right thoracotomy made it possible to obtain the diagnosis on the operative specimen with simple sequences.

## CLINICAL CASE

This is a 72 year old patient admitted for the management of an endotracheal polyp. The onset occurred one year earlier, marked by a quintessential cough associated with mucous expectorations and dyspnea on exertion. It was a superficial polypnea stage III according to the Sadoul classification evolving outside a febrile context. This motivated a consultation in pneumology before sending him to us after exploration for continuation of the care.

On admission, he was in good general clinic condition; normo-colored mucosa, without cyanosis, or edema.

Temperature: 37.2 ° C;

Pulse: 140 beats / min;

Saturation in oxygen: 87% in ambient air and 96% under oxygen;

Respiratory Frequency: 38 c / min.

The heart sounds were regular, well perceived, without added noise. Thoracic expansion was symmetrical and mobile with respiration. A dyspnea with superficial polypnea type with a suprasternal retraction, a good pulmonary sound. The vesicular murmur was audible with bilateral and diffuse rhonchis. The rest of the exam was normal. At paraclinic, thoracic CT scan found an intraluminal solid tracheal polypoid process, stenosing 18.5 x 17.1 mm between T3 and T4 (figure 1). Bronchial endoscopy showed an endocardial luminal bud vascularized at the middle third of the pedunculated trachea with an anterior foot and obstructing the tracheal light at 95% (figure 2).

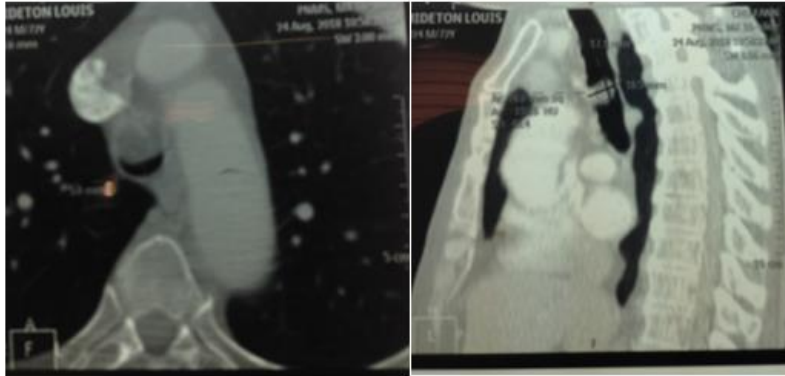On transthoracic echocardiography, we found a slight dilation of the ascending aorta (42 mm), type I diastolic dysfunction without anomaly of filling pressures, ejection fraction of 77% and pulmonary arterial systolic pressure of 31 mm Hg. A complete excision of the tumor is made by right thoracotomy.

The operative follow-up was simple with an extubation on operating table; early respiratory rehabilitation started in the recovery room allowing sequences without bronchial congestion and oxygen weaning on day 2. The hospital discharge occurred at the 5th postoperative day. The definitive histology found on

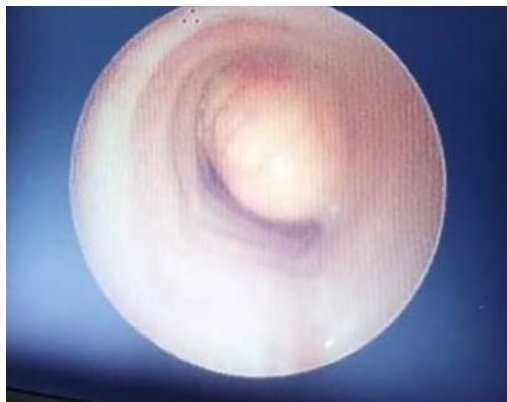
macroscopic examination a lesion of 2.1 cm in size, with an endo-tracheal proximal development, whitish-yellow in appearance, fasciculated at the cut. At the microscopic level, the lesion appears of peri-tracheal development, relatively well limited. This lesion is more or less cellular depending on the area. There is an absence of necrosis, and an average of 3 mitoses for an area of 2 mm<sup>2</sup>. The immunohistochemical study notes a diffuse expression of CD34 and STAT6, without

expression of the cytokeratin AE1 / AE3, of PS100. We noted also a relatively diffuse positivity of the tumor cells with the anti-beta-catenin antibody.

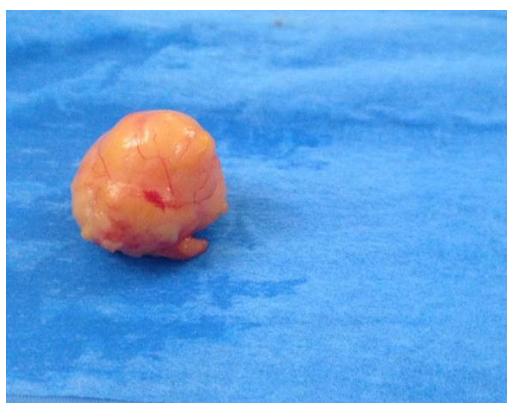In total it is an endotracheal lesion of 2.1 cm long axis corresponding to a solitary fibrous tumor, without criteria of malignancy according to the WHO 2015 classification.



**Fig-1: CT image of a solid tumor obstructing 70% of the tracheal light**



**Fig-2: Endoscopic image of the endotracheal tumor almost completely obstructing the trachea**



**Fig-3: Image of the operative piece**

## DISCUSSION

The solitary fibrous tumors of the pleura were first described by Klemperer and Rabin in 1931, and about 800 cases have been reported in the literature [4]. A Briselli study [5] of 368 cases revealed that about

80% of cases come from the visceral pleura and 20% from the parietal pleura. In the literature, there have been topographic forms located entirely in the pulmonary parenchyma, without contact with the pleura, and they represent less than 2% of the 800 cases

reported [4-6]. Endo-bronchial localization is even rarer; to our knowledge, until 2016 there were only five published cases [1-3].

All cases of reported endothelial solitary fibrous tumors have been observed in adults ranging in age from 47 to 74 years, irrespective of sex [3].

50% of patients are asymptomatic for a long time. Progression of the tumor results in compression of nearby organs and may result in chest pain, coughing and dyspnea with acute respiratory distress [7]. Imaging shows a very regular polyp aspect lesion, without calcification or necrosis, not hyper-metabolic [3]. As a result, these tumors are still considered benign before surgery [1].

Complete surgical resection with healthy margins is the only curative treatment for solitary fibrous tumors, and the definitive diagnosis of the lesion is based on histological examination of the tumor after the excision. The resection of the tumor by rigid bronchoscopy is possible but has limitations, because it does not allow to analyze the margins of resection. According to some studies, the effectiveness of surgery depends on the state of margins of tumor resection, as they often recur at the surgical site [8]. The majority of cases of endo-bronchial fibrous tumors (3/4 cases) reported were surgically treated. And this surgical excision must be complete with healthy margins to prevent local recurrence.

However, due to the rarity of endo-bronchial forms, a larger number of cases with long-term follow-up is needed to evaluate the therapeutic procedures and define the follow-up with the evolution.

In the Harrison-Phipps study [9], the average survival time for all forms of solitary fibrous tumor in 84 patients was 24 years. However, metastasized or recurrent forms led to death in 55% of cases [9]. Some histological features may indicate malignancy, such as more than four mitoses per 10 high power fields, hypercellularity, and greater tumor size [10].

The place of adjuvant treatment in case of R1 remains unclear [1, 5]. However it should be indicated, especially in recurrent malignant forms. Unlike benign lesions for which complete excision remains sufficient [1].

## CONCLUSION

The post-operative discovery of a solitary fibrous tumor in its endo-tracheal localization on an operative specimen is exceptional. Despite the predominance of benign forms, the results of surgical treatment should be evaluated and monitored similarly to solitary fibrous tumors at other sites, with long-term follow-up. Since these tumors can have high recidivism rates.

## REFERENCES

1. Pak PS, Yanagawa J, Abtin F, Wallace WD, Holmes C, Lee JM. Surgical management of endobronchial solitary fibrous tumor. *Ann Thorac Surg.* 2010; 90(2): 659-61.
2. Oliveira CC, Moraes MPT, Colby T. Endobronchial solitary fibrous tumor. *Autopsy Case Rep.* 2016; 6(4):35-40.
3. Wenyong Huang, Xiao Xu, Jiali Hu, Gongwen Cheng, Ping Xie. *Int J Clin Exp Pathol.* 2015;8(10):13596-13600
4. Perrot M, Fischer S, Brundler MA, Sekine Y, Keshavjee S. Solitary fibrous tumor of the pleura. *Ann Thorac Surg.* 2002; 74: 285–93.
5. Briselli M, Mark E, Dickersin R. Solitary Fibrous tumors of the pleura: eight new cases and review of 360 cases in the literature. *Cancer.* 1981;47:2678–89.
6. Sakurai H, Tanaka W, Kaji M, Yamazaki K, Suemasu K. Intrapulmonary localized fibrous tumor of the lung: a very unusual presentation. *The Annals of thoracic surgery.* 2008 Oct 1;86(4):1360-2.
7. Kouki E, Dougenis D. Solitary fibrous tumor of the lung. *Gen Thorac Cardiovasc Surg.* 2008;56:249-51.
8. England DM, Hochholzer L, McCarthy MJ. Localized benign and malignant fibrous tumors of the pleura. A clinicopathologic review of 223 cases. *The American journal of surgical pathology.* 1989 Aug;13(8):640-58.
9. Harrison-Phipps KM, Nichols FC, Schleck CD, Deschamps C, Cassivi SD, Schipper PH, Allen MS, Wigle DA, Pairolero PC. Solitary fibrous tumors of the pleura: results of surgical treatment and long-term prognosis. *The Journal of thoracic and cardiovascular surgery.* 2009 Jul 1;138(1):19-25.
10. Kouki HS, Koletsis EN, Zolota V, Prokakis C, Apostolakis E, Dougenis D. Solitary fibrous tumor of the lung. *Gen Thorac Cardiovasc Surg.* 2008; 56: 249-251.