

## Ovarian Carcinosarcoma

Fouzia El Hilali<sup>1\*</sup>, Ezza Lemrabott<sup>1</sup>, Sanaa Errarhay<sup>1</sup>, Nissrine Mamouni<sup>1</sup>, Chahrazed Bouchikhi<sup>1</sup>, Abdelaziz Banani<sup>1</sup>

<sup>1</sup>Departement of Obstetrics and Gynecology I - HASSAN II University Hospital – Fez, Morocco

DOI: [10.36347/sjmcr.2021.v09i04.032](https://doi.org/10.36347/sjmcr.2021.v09i04.032)

| Received: 12.03.2021 | Accepted: 17.04.2021 | Published: 29.04.2021

\*Corresponding author: Fouzia El Hilali

### Abstract

### Case Report

Ovarian carcinosarcoma or mixed müllerian malignancy is a very rare and aggressive biphasic histological entity that contains both carcinomatous (from epithelial tissue) and sarcomatous (from connective tissue) histological components. It occurs mainly in postmenopausal women and is often diagnosed at an advanced stage. Given the rarity of this tumor there is no elaborate therapeutic consensus, and the management is based on the recommendations of retrospective studies, which consists of an optimal surgical cytoreduction, followed by radiotherapy and chemotherapy, or chemotherapy alone. Its prognosis is very poor with a 5-year survival rate of 28.2%.

**Keywords:** Carcinosarcoma, mixed müllerian malignancy, ovarian cancer.

**Copyright © 2021 The Author(s):** This is an open-access article distributed under the terms of the Creative Commons Attribution 4.0 International License (CC BY-NC 4.0) which permits unrestricted use, distribution, and reproduction in any medium for non-commercial use provided the original author and source are credited.

## INTRODUCTION

Ovarian carcinosarcoma (OCS) also known as mixed müllerian malignancy is a very rare and extremely aggressive biphasic histological entity that contains both carcinomatous tissue (from epithelial tissue) and sarcomatous tissue (mesenchymal, from connective tissue) [1]. It represents less than 1% of all ovarian malignancies [2]. Its prognosis is poor with a disease-specific survival rate of 28.2% at five years [3].

## OBSERVATION

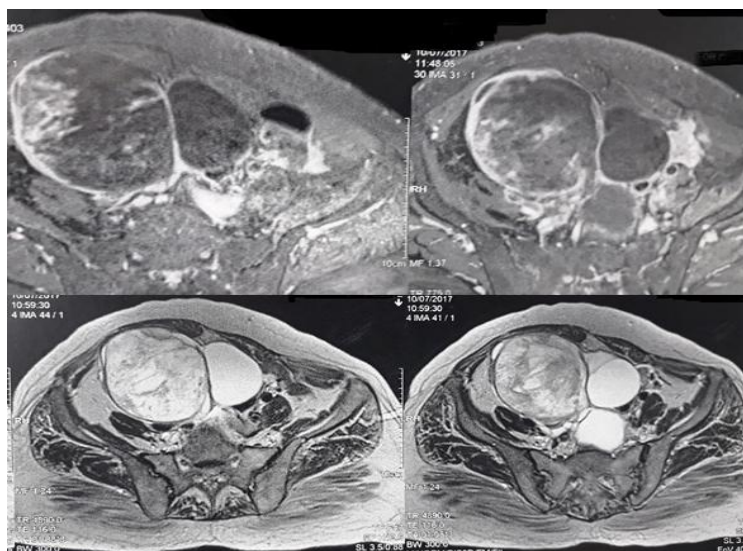
Female patient, 75 years old, Gravida 2 Para 1, menopausal, with an increase in abdominal volume and abdominopelvic pain that has been evolving for two years. Clinical examination found an abdomino-pelvic mass reaching the umbilicus, with a macroscopically normal cervix without metrorrhagia. On pelvic ultrasound: latero-uterine echogenic image containing multilocular areas in some parts, this mass measures 15x10 cm, and is prolonged below by another cystic mass of 8 cm in diameter.

Abdomino Pelvic Computed Tomography (AP CT) showed an abdominopelvic mass with a mixed tissue and cystic component measuring 17x12 cm (Figure-1). Pelvic Magnetic Resonance Imaging (MRI) revealed a large multilocular cystic mass measuring 16 cm in diameter with solid components and vegetations, evocative of a tumor mass with an ovarian origin (Figure-2).

The patient underwent a median laparotomy with a voluminous mass in the right ovary measuring 30 x 10 cm with a double component: tissue and cystic. A hysterectomy and bilateral adnexectomy were performed, with infracolic omentectomy and multiple peritoneal biopsies. The histological examination concluded to a mixed malignant müllerian tumor of the right ovary with the epithelial component: high grade serous adenocarcinoma, and for the mesenchymal component: heterologous chondrosarcomatous differentiation. The patient received adjuvant chemotherapy.

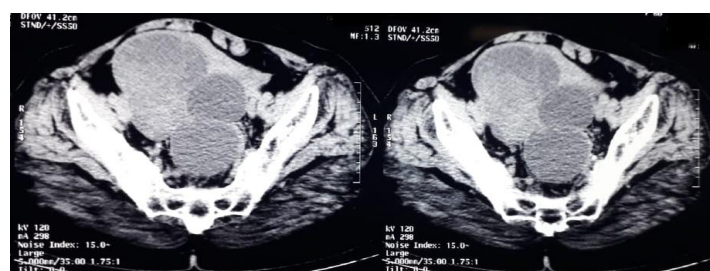

Fig-1: CT scan of the abdominopelvic mass measuring 17x12 cm



**Fig-2: MRI appearance of ovarian mass of multilocular cystic nature measuring 16 cm in large diameter with solid components and vegetations**

## DISCUSSION

OCS occurs in postmenopausal women with an average age of 65 years, diagnosed in 90% of cases at an advanced stage [4]. They are clinically manifested by abdominopelvic pain, abdominal distension and are sometimes associated with digestive disorders, with an abdominopelvic mass on clinical examination.

These tumors are usually very large in diameter, ranging from 10 to 20 cm, solid-cystic, and most often extend beyond the ovary and into the peritoneum. They contain two components, one carcinomatous (originating from the epithelial tissue) and the other sarcomatous (mesenchymal, originating from the connective tissue). These two components of the OCS are usually mixed randomly [5].

The most frequently observed epithelial components are serous, endometrioid, or undifferentiated adenocarcinomas. OCSs are classified according to homologous or heterologous derivation of mesenchymal tissue into their stromal component. Homologous carcinosarcomas contain sarcomatous elements that differentiate from physiologically native ovarian tissue and include fibrosarcoma and leiomyosarcoma. Heterologous components usually contain malignant osteoid, chondroid or rhabdomyoid cells that are physiologically foreign to the primary site [6]. In our case it is a heterologous carcinosarcoma.

There is no international consensus for the management of OCS due to its rarity, and generally the therapeutic approach follows the recommendations of retrospective studies, and consists of an optimal surgical cytoreduction including hysterectomy, bilateral adnexectomy, omentectomy, and appendectomy, with lumbo-aortic and pelvic lymphadenectomy, and multiple peritoneal biopsies [5].

The surgery is followed by both radiotherapy and chemotherapy or chemotherapy alone. Chemotherapy may be based on platinum salts alone, or a combination of carboplatin-paclitaxel or platinum-ifosfamide [1]. In some cases, three or six cycles of chemotherapy may be given preoperatively to achieve an optimal surgical outcome [5].

The prognosis of OCS is unfavorable compared to epithelial carcinoma of the ovary with a median overall survival ranging from 7 to 27 months [7], according to the review of the literature by Boussios *et al.*, several prognostic factors have been described, including age less than 65 years, disease stage, a preponderant sarcomatoid component of more than 25%, vascular endothelial growth factor (VEGF) expression, p53 mutation, Ki-67 overexpression, tumor grade and residual disease after surgery [5].

## CONCLUSION

Ovarian carcinosarcoma or malignant mixed Mullerian tumor is a very rare histological entity with a very poor prognosis, whose therapeutic management is based on the recommendations of retrospective studies. More appropriate studies are needed for a better evaluation and the development of a therapeutic consensus.

## REFERENCES

1. Shylasree TS, Bryant A, Athavale R. Chemotherapy and/or radiotherapy in combination with surgery for ovarian carcinosarcoma. *Cochrane Database Syst Rev.* 2013;2:CD006246.
2. Russell\_PB, Solomon\_HJ. Malignant mullerian and miscellaneous mesenchymal tumors of ovary ('ovarian sarcomas'). In: Coppers M editor(s). *Gynecologic Oncology.* 2nd Edition. Churchill Livingstone, 1992:971-86.

3. Rauh-Hain JA, Diver EJ, Clemmer JT, Bradford LS, Clark RM, Growdon WB, Goodman AK, Boruta II DM, Schorge JO, Del Carmen MG. Carcinosarcoma of the ovary compared to papillary serous ovarian carcinoma: a SEER analysis. *Gynecologic oncology*. 2013 Oct 1;131(1):46-51.
4. Berton-Rigaud, D., Devouassoux-Shisheboran, M., Ledermann, J. A., Leitao, M. M., Powell, M. A., Poveda, A., ... & Ray-Coquard, I. (2014). Gynecologic Cancer InterGroup (GCIg) consensus review for uterine and ovarian carcinosarcoma. *International Journal of Gynecologic Cancer*, 24(Supp 3): S55–S60.
5. Boussios, S, Karathanasi A, Zakyntinakis-Kyriakou N, Tsiouris AK, Chatziantoniou AA., Kanellos FS, Tatsi K. Ovarian carcinosarcoma: Current developments and future perspectives. *Critical Reviews in Oncology/Hematology*, 2019;134, 46–55.
6. The effect of epithelial and stromal tumor components on FIGO stages III and IV ovarian carcinosarcomas treated with primary surgery and chemotherapy; 1025-1030.
7. Duska LR, Garrett A, Eltabbakh GH, Oliva E, Penson R, Fuller AF. Paclitaxel and platinum chemotherapy for malignant mixed mullerian tumors of the ovary. *Gynecologic oncology*. 2002 Jun 1;85(3):459-63.