

## Adrenal Pheochromocytoma in a 16-Year Old Male Patient

Dr. El Fdili El Mostapha\*, Pr. Karim IBN Majdoub, Pr. Khalid Mazaz

Digestive and Endocrine Surgery Department, Hassan II University Hospital in Fez

DOI: [10.36347/sasjs.2021.v07i10.009](https://doi.org/10.36347/sasjs.2021.v07i10.009)

| Received: 04.08.2021 | Accepted: 04.10.2021 | Published: 12.10.2021

\*Corresponding author: Dr. El Fdili El Mostapha

### Abstract

### Case Report

Pheochromocytoma is a rare endocrine tumor (incidence 0.1–2%), developed at the expense of chromaffin cells in the adrenal medulla (localization in 85%), secreting catecholamines responsible for paroxysmal or more often permanent arterial hypertension, tachycardia, headache, anxiety. It is a rare cause of high blood pressure (hypertension) in children, which has some peculiarities compared to adults. We report in our work an observation of pheochromocytoma operated in the department of digestive and endocrine surgery at the University Hospital of Fez.

**Keywords:** Pheochromocytoma; hypertension; surgery; pheochromocytoma in children; preoperative preparation; surrenalectomy; follow-up.

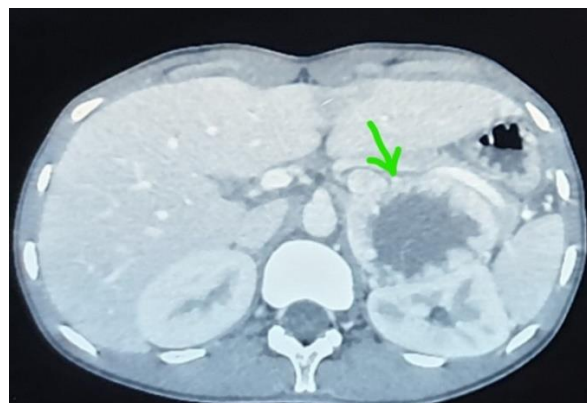
**Copyright © 2021 The Author(s):** This is an open-access article distributed under the terms of the Creative Commons Attribution 4.0 International License (CC BY-NC 4.0) which permits unrestricted use, distribution, and reproduction in any medium for non-commercial use provided the original author and source are credited.

## INTRODUCTION

The diagnosis of pheochromocytoma is based on the methoxyl derivative assay and on the abdominal CT scan, its management requires medical preparation by antihypertensive treatment, sometimes embolization to minimize the risk of intraoperative haemorrhage, surgery is the standard treatment to eradicate symptoms. Follow-up is always recommended to detect recurrences.

## CASE REPORT

M. F.O is a 16-year-old patient of Moroccan origin with no medical history. He has had headaches, palpitations and sweating for 2 years, the symptoms worsened 2 months ago by the occurrence of diffuse abdominal pain more accentuated in the left hypochondrium. In the emergency room, he has a BP of 220/90 mmHg, with a heart rate of 107bp / min and a weight of 45 kg height 172 cm, BMI at 15.59 kg / m<sup>2</sup>. The remainder of the physical examination is within specification. In the biological assessment, a 24-hour urine collection: metanephrines 35 nmol / L, normetanephrines 4050 nmol / L or 8.9\* N, 3 ortho methyl dopamine: 266 nmol / l 1.66N. Abdominal CT scan, Presence of a retro-peritoneal inter-spleno-renal tissue mass measuring 60x72x75 mm with ipsilateral adrenal gland probably seen, hypervascularized with a liquefied center irrigated by the left renal vein without loco-regional extension or neighboring lymphadenopathy or localization secondary to distance.



**Fig-1: Inter-spleno-renal tissue mass measuring 60x72x75 mm**

The management of the tumor consisted of 3 parts: a medical preparation at first, arterial embolization then surgery.

### 1- Medical preparation

- Alpha blocker: Terazosine 2mg 1pill per day
- Adding calcium channel blocker 10 mg at the 7th day.
- Atarax (1-0-1) + oral Potassium.

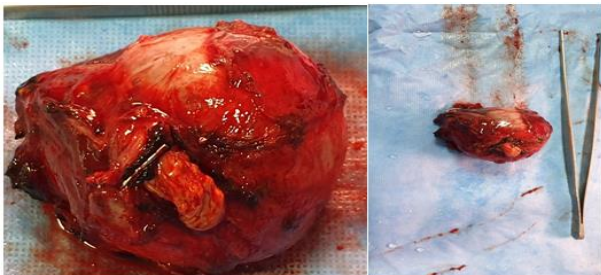
### 2- ARTERIAL EMBOLIZATION

The patient underwent embolization of the 2 upper and lower left adrenal arteries. The act went off without incident.

### 3- SURGERY

#### a- surgical procedure

- Under general anesthesia in the supine position
- Left subcostal parotomy
- Exploration: no ascites or hepatic metastasis or carcinoma nodules
- Realization of a colo-epiploic detachment from right to left allowing access to ACE
- Lowering of the left colic angle
- The opening of the adrenal compartment revealed a large adrenal tumor measuring about 8 cm, very adherent to the upper pole of the left kidney and with a liquefied center.
- Mobilization of the spleno-pancreatic block then its reposition allowing the exposure of the anterior face of the aorta and the left renal vein
- Dissection, ligation then section of the main adrenal vein as well as the accessory vein
- Liberation of the tumor of the upper pole of the left kidney
- Performing a left adrenalectomy after section ligation of its posterior and upper attachments and of the upper left adrenal artery (very dilated because of the embolization) Hemostasis made and putting place of a Surgicel in the dressing room
- Drainage of the rear omentum cavity by a suction Redon



#### b- Post-operatives suites

##### Clinically

- Patient remained hemodynamically and respiratory stable
- Blood pressure: Varies between 12-13 / 07-08 cmHg without orthostatic hypotension
- Pulse: varies between 100-105 bpm

##### Biologically

- Na: 135 meq / l K: 4.3 meq / l
- 8am cortisol: 15.7 ug / dl
- DMU at D + 7 negative validated by a correct 24-hour creatinuria: 1074 mg / 24
- Normetadrenaline: 79 nmol / l
- Metadrenaline: 32 nmol / l (normal)
- 3 orthomethyldopamine: 150 nmol / l

### 4- ANATOMOPATHOLOGICAL EXAMINATION

The pathological examination objectified a histological aspect suggesting a pheochromocytoma, of non-aggressive potential (PASS score 2).

### DISCUSSION

Pheochromocytoma is an adrenal medulla tumor that develops at the expense of chromaffin cells. It is characterized by great variability in biological activity and therefore clinical manifestations. The exceptionally tumoral clinical expression results from the effects of catecholamines on the receptor organs [1]. Pheochromocytomas represent 4% of adrenal tumors discovered incidentally [2]. 10–20% of pheochromocytomas are encountered in childhood, with an incidence of 0.2-0.5 cases per million children [3].

The clinical manifestations result from the effects of catecholamines on the receptor organs, which makes its symptomatology very polymorphic and most often atypical, which can delay the diagnosis. Thus, apart from the usual signs found in adults dominated by Ménard's clinical triad: pulsatile headaches, palpitations and sweating associated with paroxysmal hypertension, in children other signs are also found: weight loss estimated at 10 kg, asthenia, constipation, with anxiety. In our patient, the clinical symptoms were dominated by paroxysmal frontal headaches and diffuse abdominal pain more marked in the left hypochondrium.

The positive diagnosis of pheochromocytoma is biological. It is based on the demonstration of an abnormally high secretion of catecholamines in the form of their methoxylated derivatives: metanephrine and normetanephrine. Any clinical suspicion of pheochromocytoma must therefore be confirmed or not by biology, whether it is a patient with suggestive symptoms or an asymptomatic patient carrying a mutation identified in a predisposition gene, in as part of family screening [4]. In our observation, the blood dosage of catecholamines was not done, while the urinary dosage of their metabolites was high. In fact, the determination of methoxide derivatives, especially in urine, has a sensitivity of over 99% and is currently considered to be the most reliable measure [5]. In our study, the dosage of normetanephrine was high and metanephrine was normal. The radiologic evaluation usually is made with a computed tomography scan or a magnetic resonance study to localize the tumors. Both CT and MRI have similar diagnostic sensitivities [6].

In our case, the abdominal CT scan objectified an inter-spleno-renal retro-peritoneal tissue mass measuring 60x72x75 mm with ipsilateral adrenal gland probably seen, hypervascularized with a liquefied center.

The surgical treatment must be preceded by a preoperative preparation, in order to balance the blood pressure to prevent any operative problem; our patient was put on antihypertensive treatment made of alpha blockers and calcium channel blockers.

The surgical approach should be personalized according to tumor size, location, and any underlying mutation [7], in our case the first was by left subcostal laparotomy due the large size of the tumor and the procedure consisted of a total left surrenalectomy. The post-surgical anatomopathological study revealed adrenal parenchyma is the site of a well-limited tumor proliferation arranged in small back-to-back nests (Score 0), of moderate cellularity (Score 0). It is made of polygonal cells of medium size, with a moderately atypical nucleus with loose chromatin (Score 0) sometimes nucleolated signs of malignancy have not been found.

This resection allowed the normalization of blood pressure in our patient. Long-term monitoring is necessary to look for possible recurrences and late onset of metastases [8].

## CONCLUSION

Surgical resection is the standard treatment for pheochromocytomas, however long-term follow-up is recommended postoperatively for the detection of any metastases, genetic counseling is recommended.

## REFERENCES

1. Touiti, D., Seket, B., Deligne, E., Badet, L., Colombel, M., Dawahra, M., & Dubernard, J. M. (2001, November). Phéochromocytomes surrenaliens bilatéraux au cours de la maladie de von Hippel-Lindau. In *Annales d'urologie* (Vol. 35, No. 6, pp. 323-328). Elsevier Masson.
2. Lo, C. Y., Lam, K.Y., Wat, M.S., Lam, K.S. (2000). Adrenal pheochromocytoma remains a frequency overlooked diagnosis. *Am J Surg*, 179; 212–5.
3. de Tersant, M., Généré, L., Freyçon, C., Villebasse, S., Abbas, R., Barlier, A., ... & Brugières, L. (2020). Pheochromocytoma and paraganglioma in children and adolescents: experience of the French Society of Pediatric Oncology (SFCE). *Journal of the Endocrine Society*, 4(5), bvaa 039
4. Phéochromocytome et paragangliome - 02/12/13 [10-015-B-50] - Doi: 10.1016/S1155-1941(13)64274-2 page 2 S. Laboureau, V. Rohmer.
5. Brunaud, L., Ayav, A., Bresler, L., Klein, M., & Boissel, P. (2005). Les problèmes diagnostiques du phéochromocytome. In *Annales de chirurgie* (Vol. 4, No. 130, pp. 267-272).
6. Cohen, B., Silbiger, A., Otremski, S., Matot, I., & Riou, B. (2011). Case Scenario: Metastatic Pediatric Paraganglioma Presenting during the Course of an Elective Surgery. *The Journal of the American Society of Anesthesiologists*, 115(2), 408-413.
7. Gunawan, V. L., Suarta, K., Nilawati, G. A. P., Arimbawa, I. M., Darmajaya, M., Ariyanta, K. D., & Hartawan, I. N. B. (2019). Bilateral adrenal pheochromocytomas in a 14 year-old boy. *Journal of Pediatric Surgery Case Reports*, 51, 101318.
8. Dubois, R., & Chappuis, J. P. (1997). Le phéochromocytome: particularités pédiatriques. *Archives de pédiatrie*, 4(12), 1217-1225.